FirstRanker.com
Firstranker's choice
www.FirstRanker.com www.FirstRanker.com

HEAD & NECK. (2 types of Skeletal muscles) 3 Motor column
(1. Smooth muscle)

Cranial nerve nuclei

* pharyngeal arches

I → Mandibular nerve → M/s of mastication.
II → facial nerve → M/s of facial expression
III → glossopharyngeal. IX → M/s of palate, pharynx, Larynx.
IV →
V →
VI →
X vagus nerve.

are supplied by (VAC) vago accessory complex.

Somatic Muscles :-

* Extraoccular & Tongue muscles. (not derived from).

Neural tube.

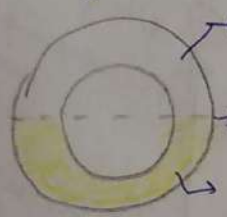

Alar plate (Dorsal). → sensory nuclei
sulcus limitans.
Basal plate. → Motor nuclei

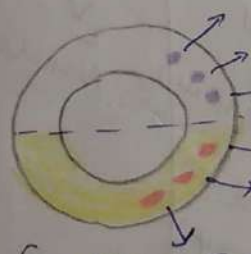

GSA (Gene. Somatic. Afferent) → Gen. sensation from Body wall
SVA (Sp. visceral. A.) → Taste.
GVA (G. visceral. A) → General sensation from viscera
GVE (General Visceral Eff) → smooth muscles & glands, → mucosa gland.
SVE (Sp. Visceral Efferent) → Pharyngeal arch mus → motor pharyng
(Motor Efferent): GSE
Gen. Somatic Efferent. → Somatic skl. mus → tongue → EOM.



www.FirstRanker.com
Scanned by CamScanner

FirstRanker.com
Firstranker's choice
www.FirstRanker.com www.FirstRanker.com

2016

HEAD & NECK. (2 types of Skeletal muscles) 3 Motor column.
(1 Smooth muscle)

Cranial nerve nuclei

* pharyngeal arches

I → Mandibular nerve → M/s of mastication.
II → facial nerve → M/s of facial expression
III → glossopharyngeal. IX
IV →
V →
VI →
X vagus nerve.

→ M/s of palate, pharynx, Larynx.
are supplied by (VAC) vago accessory complex.

Somatic Muscles :-

* Extra occular & Tongue muscles. (not derived from).

Neural tube.

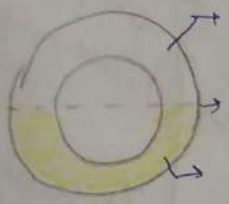

→ Alar plate (Dorsal). → sensory nuclei
→ sulcus limitans.
→ Basal plate. → Motor nuclei

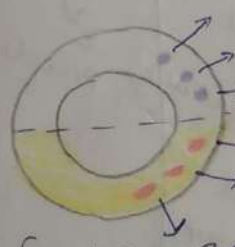

GSA (Gene. Somatic Afferent) → Gen. sensation from Body wall
SVA (Sp. visceral A.) → Taste.
GVA (G. Visceral A) → General sensation from viscera
GVE (General Visceral Eff) → smooth muscles & glands. → mucosa gland.
SVE (Sp. Visceral Efferent) → Pharyngeal arch mus → motor pharyng
(Motor Efferent): GSE
Gen. Somatic Efferent. → Somatic skl. mus → tongue → EOM.

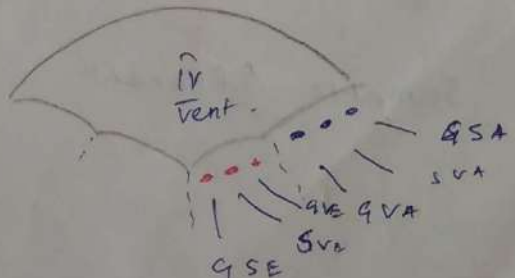

www.FirstRanker.com
Scanned by CamScanner

FirstRanker.com
Firstranker's choice
www.FirstRanker.com www.FirstRanker.com

Brainstem

	GSE	SVE	GVE
Midbrain	III, IV		Edinger Westphal → Sphincter pupillare → ciliaris (using 3rd nerve)
Pons	V3, VI	VII	Sup. Salivatory nr. (Sub mandibular, Sublingual) Caudal part → (lacrimatory) using VII; Inf. SSN (parotid) using IX
MO	XII	IX, X, XI	Dorsal nucleus of Vagus using X

(Nucleus Ambiguus)

injury to n.A.
* ipsilateral bulbar paralysis
* loss of gag reflex.

3, 7, 9, 10

Parasympathetic.

	GVA / SVA	GSA
Midbrain		Mesencephalic (Proprioception)
Pons		Principal sensory (touch, pressure)
MO	Cranial Taste. Nucleus of Tractus solitarius.	Spinal (pain & temp.)

(1) Jaw reflex / masseteric reflex.

(2) Site of pseudounipolar neurons.

Trigeminal → nucleus.

→ C2 level of Spinal cord.

SSA → Special Somatic Afferent.

www.FirstRanker.com
Scanned by CamScanner

FirstRanker.com
Firstranker's choice
www.FirstRanker.com www.FirstRanker.com

(1) Vision → II × no nuclei

(2) Olfaction → I × no nuclei

(3) Auditory → VIII → vestibulo cochlear nucleus.

V 3S 1M SVE, GSA (2 cocolumns).

III GSE, GVE, GSA

IV GSE, GSA.

VI GSE, GSA.

VII SVE (M/S face exp) GVE ~~parotid~~ SVA (chorda tympani taste from Ant 2/3rd of tongue) GSA (skin of auricle)

IX SVE (stylopharyngeus) GVE inf. saliva nu GVA | SVA ↓ gen sens post-1/3rd tong ↓ taste sensation post 1/3rd tong. GSA Proprioception

X (Vagus) SVE GVE. GVA | SVA. GSA

www.FirstRanker.com
Scanned by CamScanner

FirstRanker.com
Firstranker's choice
www.FirstRanker.com www.FirstRanker.com

III occulomotor nerve

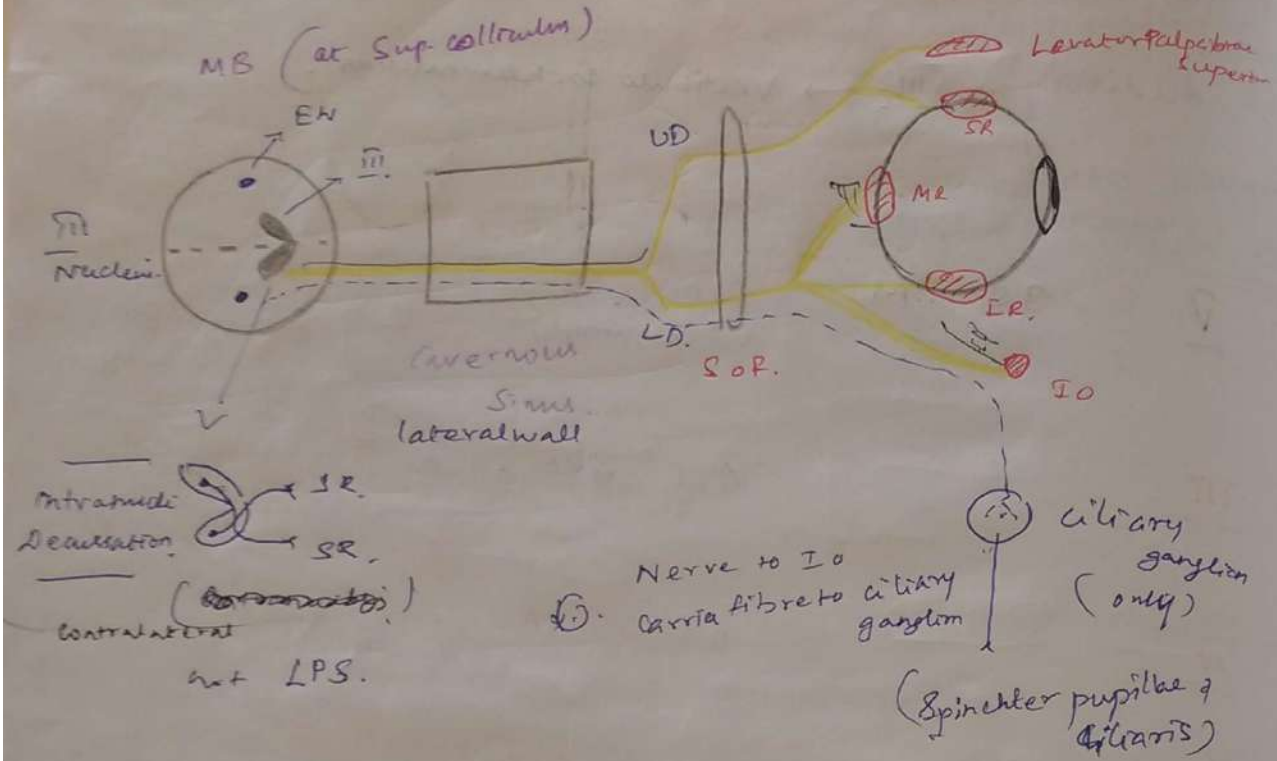

* III nerve content of interpeduncular fossa.
* Nerve which is most commonly involved intracranial aneurysms. due to circle of willis.

IV Trochlear Nerve...

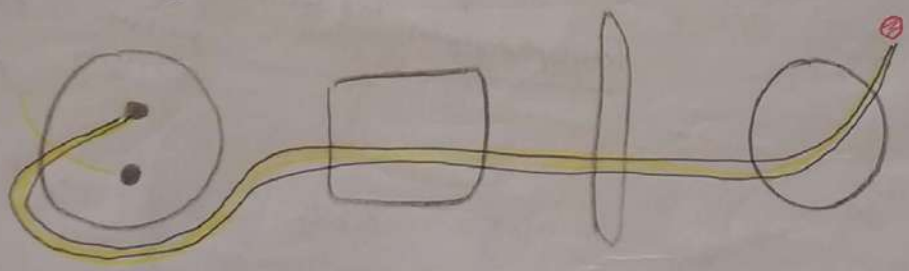

* Thinnest cranial Nerve (more slender) & smallest (thickness)
* only Nerve from Dorsal aspect of Brainstem
* Longest Intracranial course.
* LMN Decussate within Brainstem

www.FirstRanker.com
Scanned by CamScanner

FirstRanker.com
Firstranker's choice
www.FirstRanker.com www.FirstRanker.com

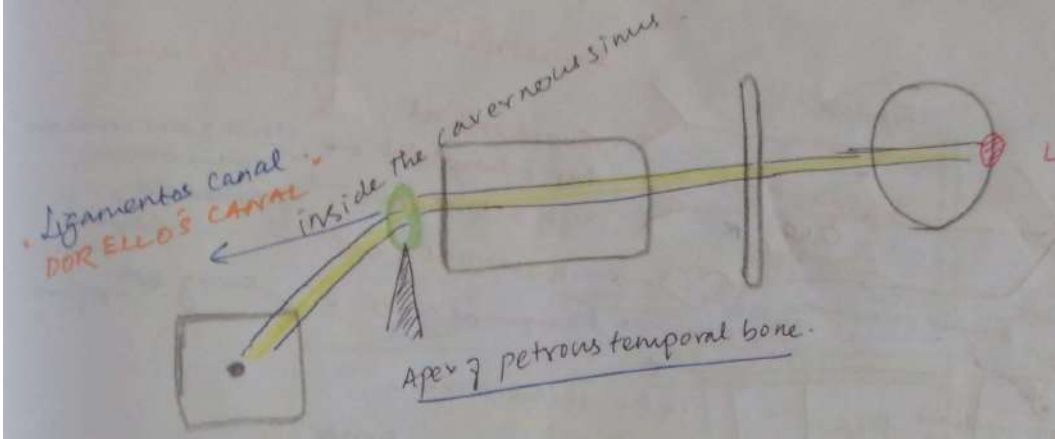

* most commonly involved in ↑ ICP.
* Longest intradural coarse.

Parasympathetic Ganglion.

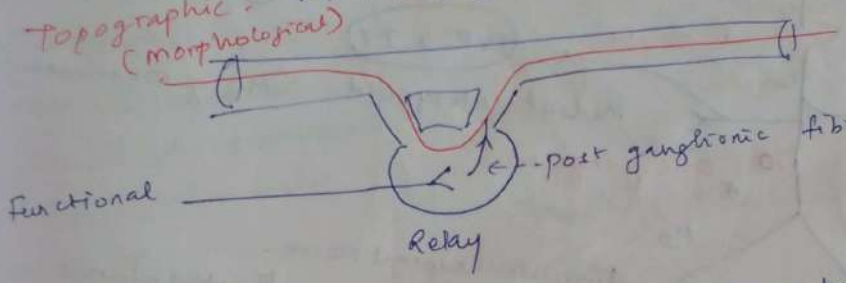

* Nerve which connects ganglion topographically will also carry post ganglionic parasympathetic fibres.
* All parasympathetic ganglions of H & N are topographically related to "Trigeminal Nerve fibres".
* So that the All post-gang-parasympathetic fibres are Branches of "Trigeminal nerve"

www.FirstRanker.com
Scanned by CamScanner

FirstRanker.com
Firstranker's choice
www.FirstRanker.com www.FirstRanker.com

V Trigeminal Nerve :-

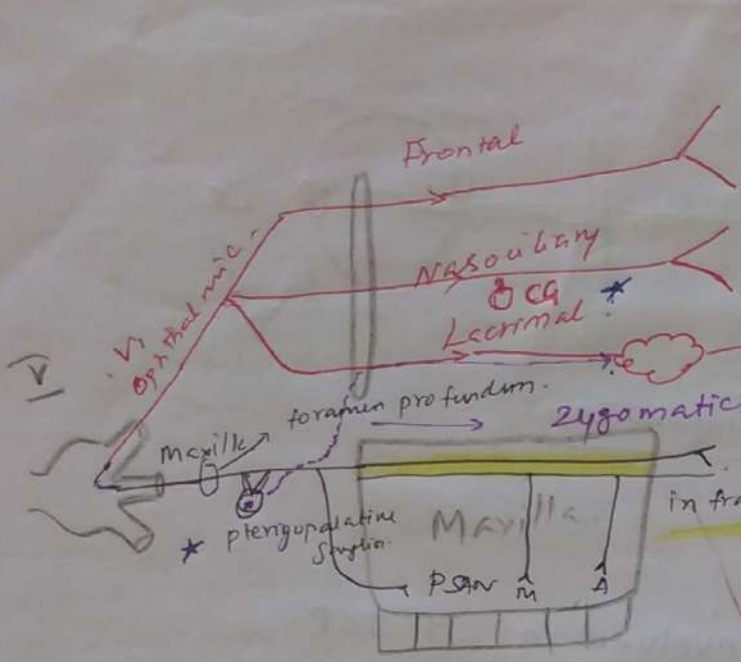

★ topographically

Mandibular Nerve :-

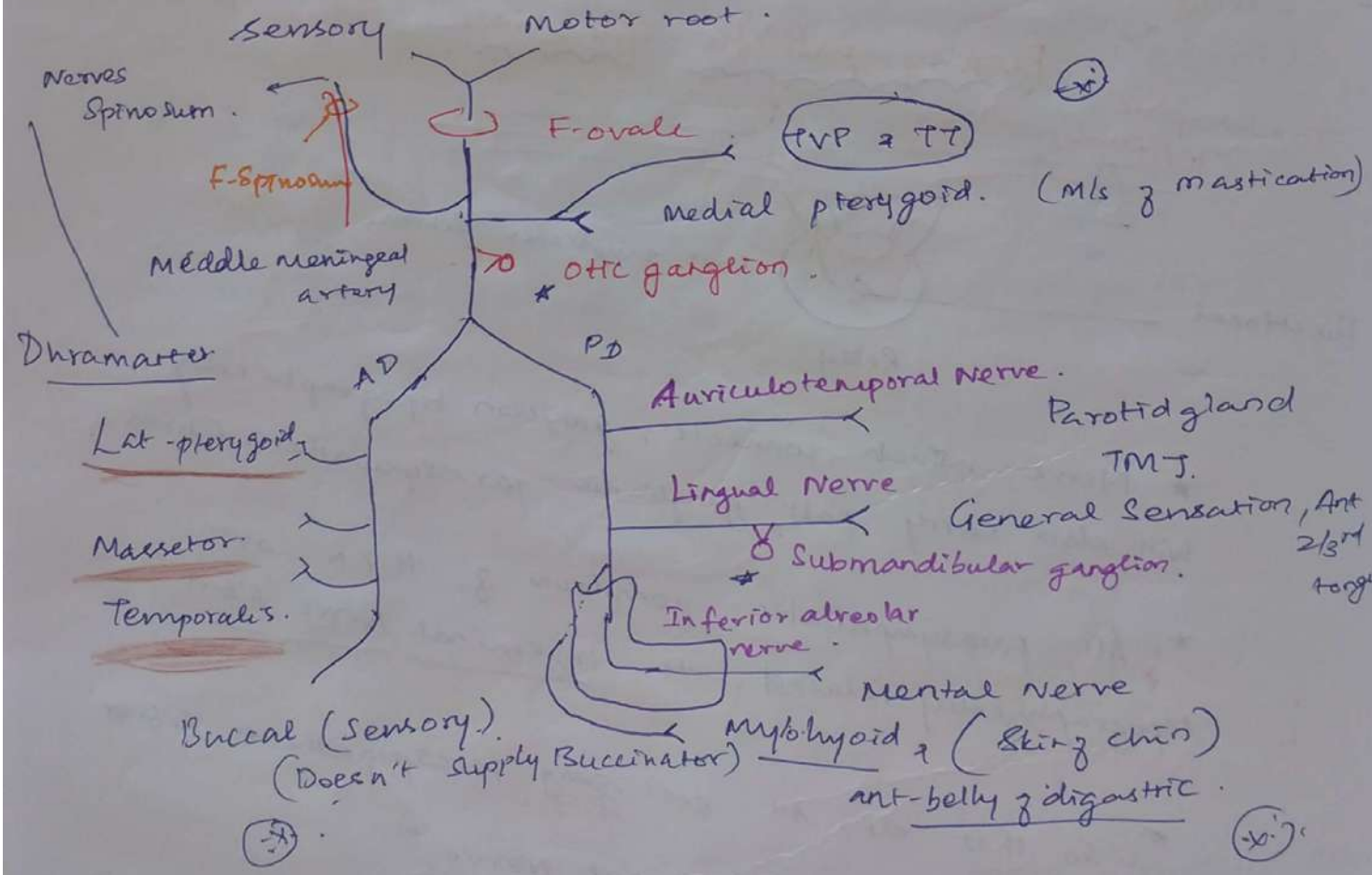

(xi)

TVP & TT

Medial pterygoid. (Mls of mastication)

Parotid gland
TMJ.

General Sensation, Ant 2/3rd tongue

(xii)

(x)

www.FirstRanker.com
Scanned by CamScanner

FirstRanker.com
Firstranker's choice
www.FirstRanker.com www.FirstRanker.com

VII facial Nerve: (long [illegible] nerve)

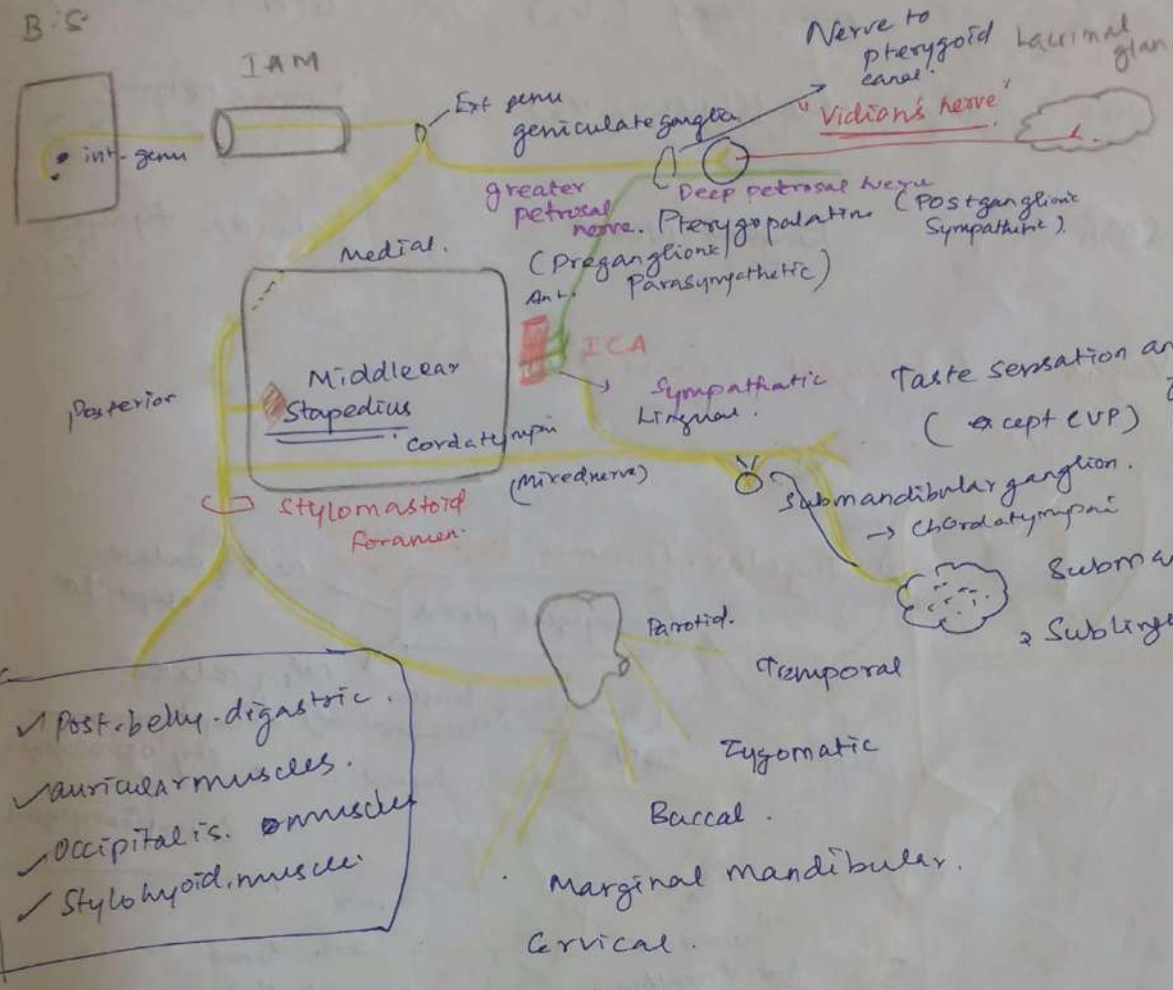

IX Glossopharyngeal Nerve:-

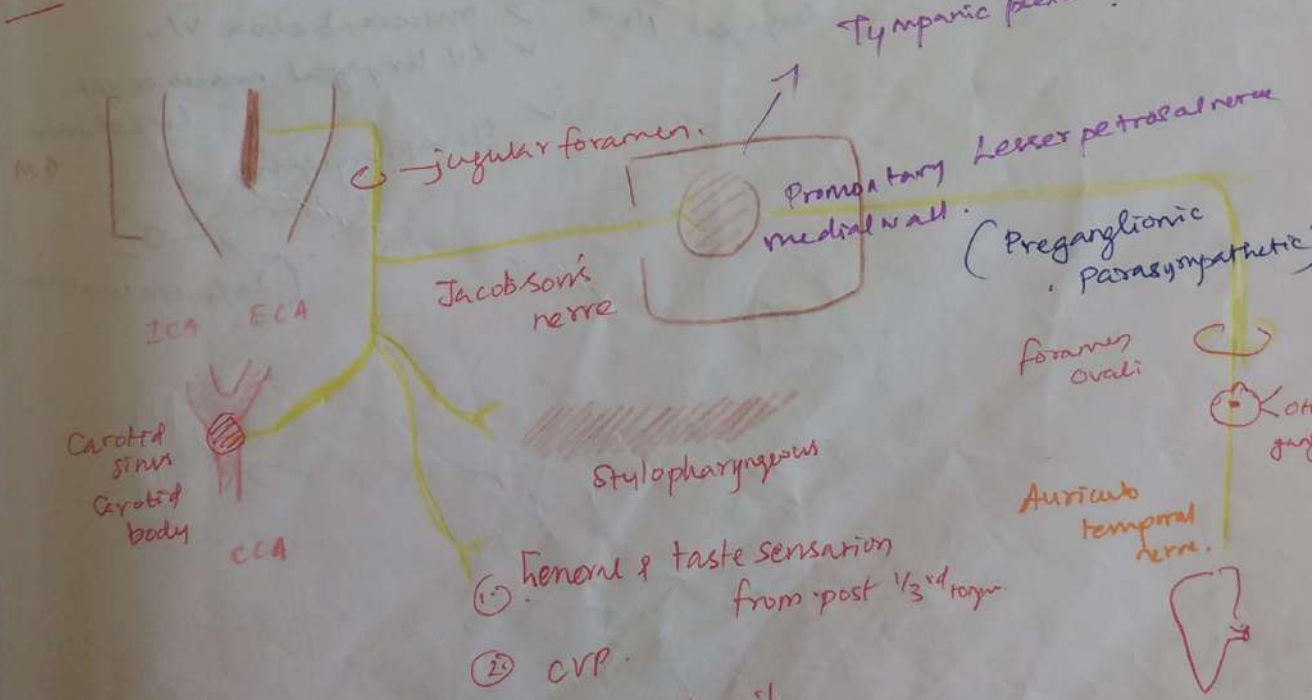

www.FirstRanker.com
Scanned by CamScanner

FirstRanker.com
Firstranker's choice
www.FirstRanker.com www.FirstRanker.com

Ganglion	Topographical
1. Ciliary	Nasociliary (V_1)
2. PPG.	maxillary (V_2)
3. Otic	Mandibular (V_3)
4. SMG	Lingual Nerve

III rd nerve.

GPN (VII branch)

Lesser petrosal (IX)

chorda tympani (VII)

X Vagus (Longest cranial nerve)

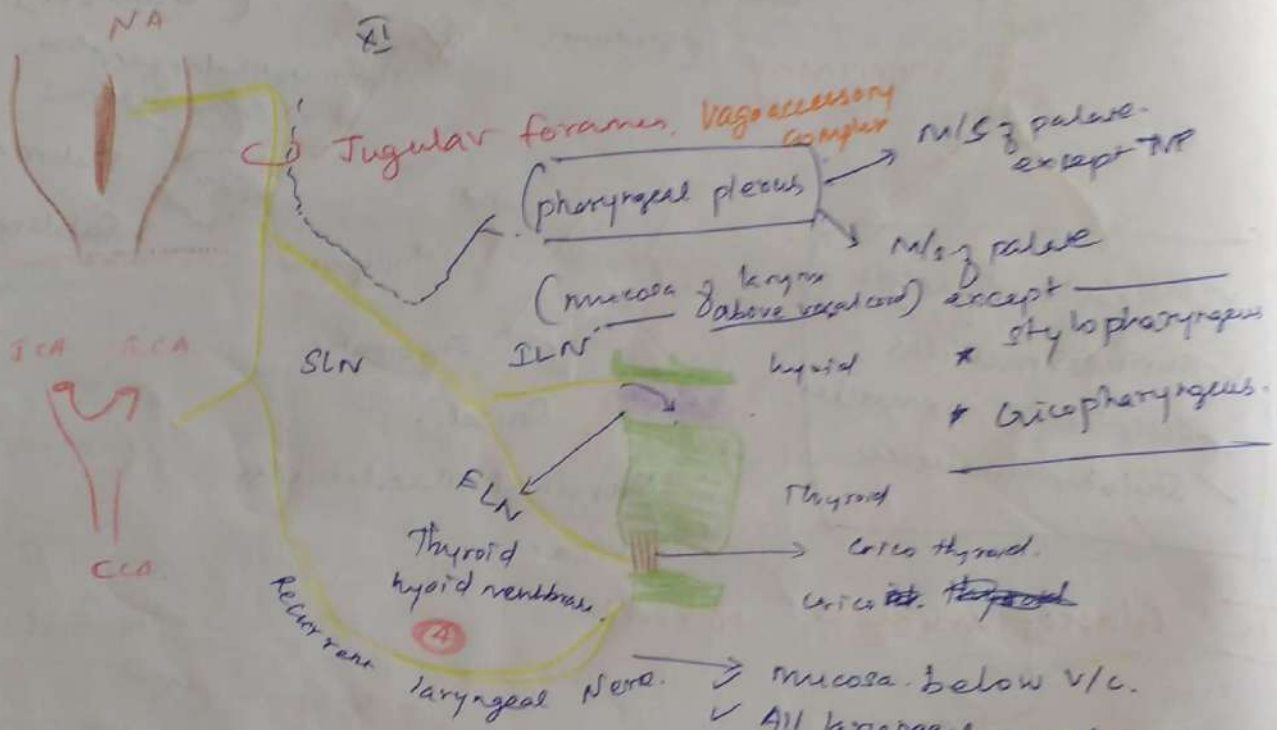

www.FirstRanker.com
Scanned by CamScanner

FirstRanker.com
Firstranker's choice
www.FirstRanker.com www.FirstRanker.com

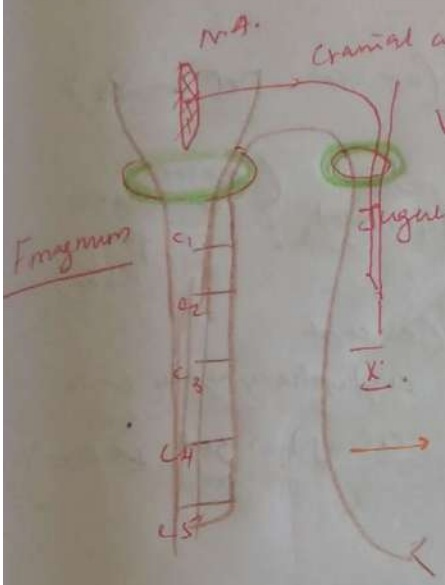

Spinal accessory

Sternocleidomastoid.

Trapezius.

XII Hypoglossal Nerve :-

All m/s of tongue except. Palatoglossus

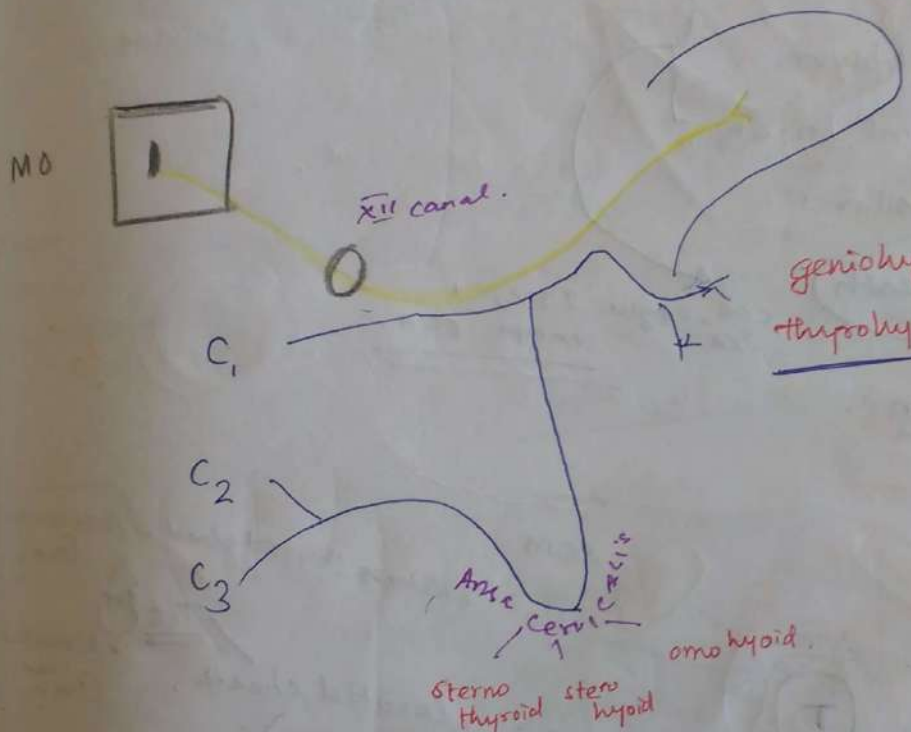

Geniohyoid
thyrohyoid.

only strap muscle which is not supplied by Ansacervicalis

www.FirstRanker.com
Scanned by CamScanner

FirstRanker.com
Firstranker's choice
www.FirstRanker.com www.FirstRanker.com

* All tongue muscles are supplied by XII (except palatoglossus)
* All m/s of palate " " VAC (except TVP ← V_3)
* All m/s of larynx " " recurrent laryngeal nerve (except cricothyroid ↑ ELN)
* All m/s of pharynx " " VAC (except stylopharyngeus ← IX, cricopharyngeal nerve ← RLN)

DEEP CERVICAL FASCIA.

↓

Modification.

↓

1. Investing layer.
2. Pretracheal layer,
3. Prevertebral layer.
4. Paryngobasilar.
5. Carotid sheath. — CCA, vagus, IJV, ICA, (except ECA).

Transverse Section :-

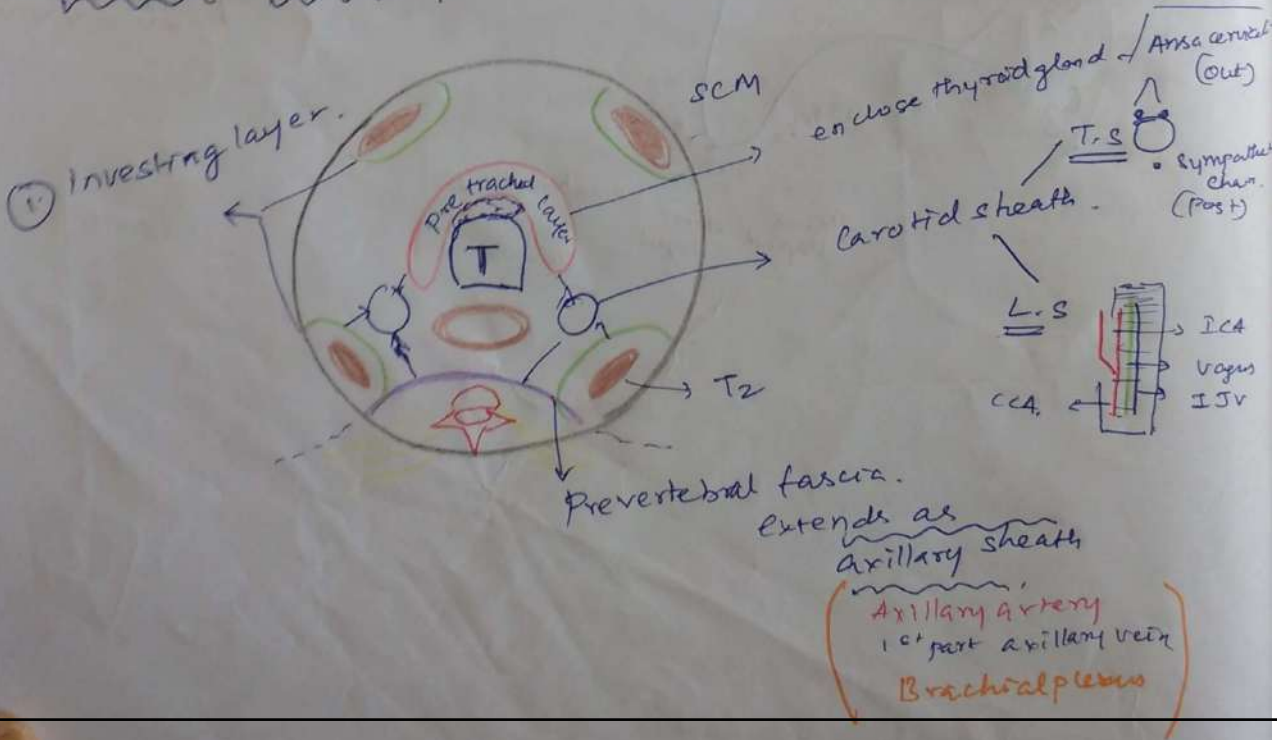

www.FirstRanker.com
Scanned by CamScanner

FirstRanker.com
Firstranker's choice
www.FirstRanker.com www.FirstRanker.com

Longitudinal section :-

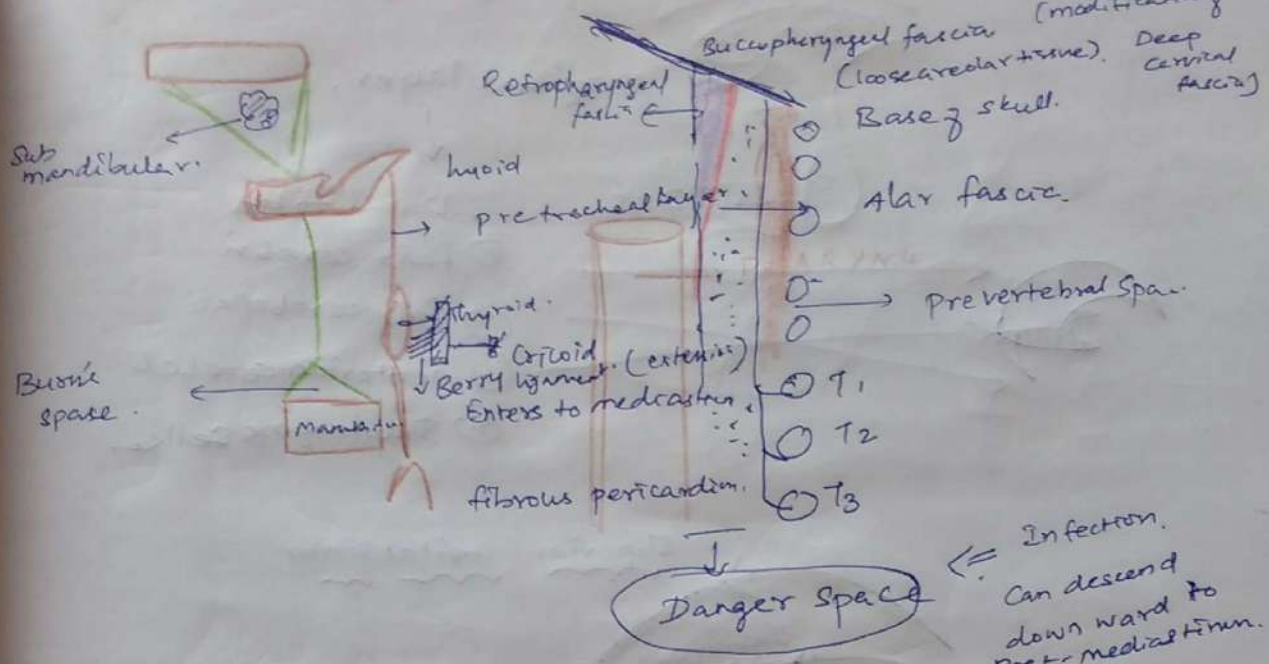

① Investing layer :-

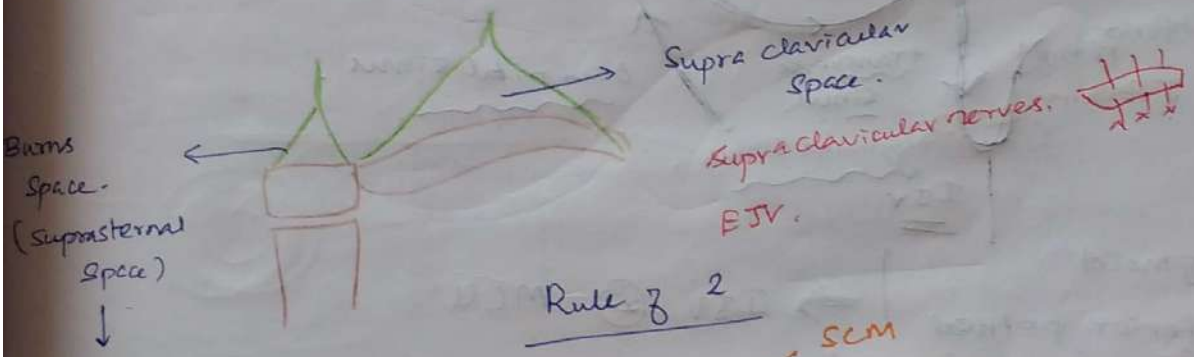

Rule of 2

- ★ 2 muscles < SCM, Trapezius.
- ★ 2 gland. < Submandibular. Parotid.
- ★ 2 spaces < Burns space, supra clavicular.
- ★ 2 ligaments < Spheno mandibular lig, Stylo mandibular lig.

Inter clavicular ligament
Sternal head of SCM.
Jugulo Venous Arch.

false ligament. TMJ.

www.FirstRanker.com
Scanned by CamScanner

FirstRanker.com
Firstranker's choice
www.FirstRanker.com www.FirstRanker.com

Cranial Duramater

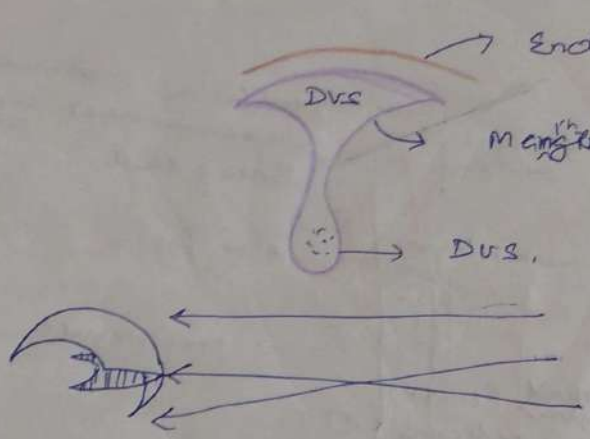

Dural folds

① falx cerebri
② falx cerebelli
③ Tentorium cerebeli
④ Diaphragma sellae.

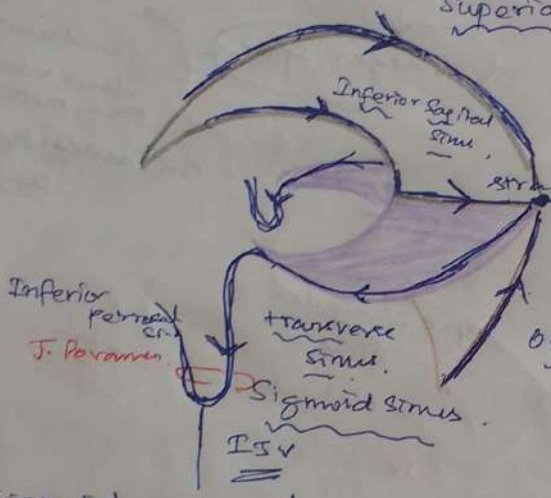

Sigmoid
Inferior petrosal
"formation tributaries" → IJV ⑧ MCQ

Inferior Sagittal
?
Straight sinus
→ only in meningeal layer of Dura.

www.FirstRanker.com
Scanned by CamScanner

FirstRanker.com
Firstranker's choice
www.FirstRanker.com www.FirstRanker.com

CAVERNOUS SINUS

Superior ophthalmic vein (emissary) novalue

Incoming :-

- SOV
- IOV
- Sup. Middle cerebral vein
- Inf. cerebral vein
- Speno parietal sinus
- middle meningeal sinus (Ant. tributary of middle meningeal vein).

ORBIT | BRAIN | MENINGES

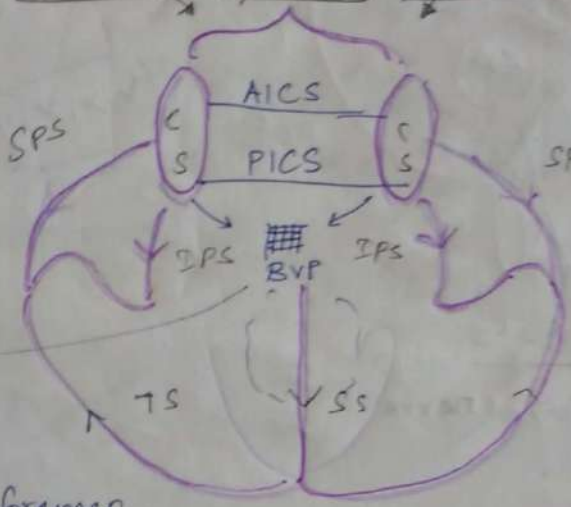

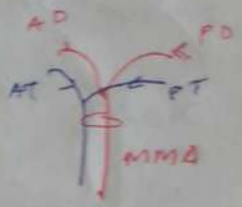

Basilar venous plexus
↓
Beyond foramen magnum
Vertebral venous plexus
(BETSONS PLEXUS)

Outgoing

- ✓ SOV - (emissary).
- ✓ SPS
- ✓ IPS.

Relations :-

Coronal section :-

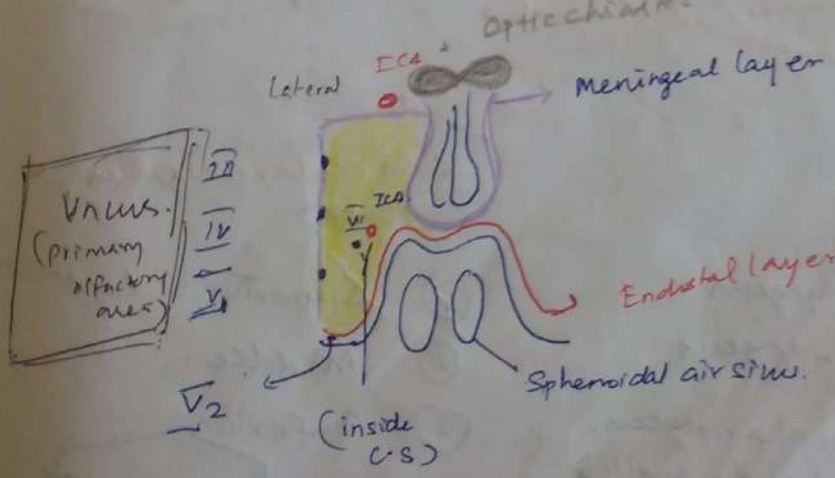



www.FirstRanker.com
Scanned by CamScanner

FirstRanker.com
Firstranker's choice
www.FirstRanker.com www.FirstRanker.com

...ervation.

Pharyngeal wall :-

Inside → outside.

1. Mucous membrane.
2. pharyngo basilar fascia.
3. Muscle coat.
4. Buccopharyngeal fascia.



pharyngeal raphe.

Muscles of pharynx

3 longitudinal (Inner)

1. Stylopharyngeus.
2. Palatopharyngeus.
3. Salpingopharyngeus. (medial end of auditory tube.)

Post part thyroid cartilage

Deglutition.

3 circular muscles (outer)

1. Superior Constric
2. Middle.
3. Inferior
   - Thyropharyngeus
   - Cricop

www.FirstRanker.com
Scanned by CamScanner

FirstRanker.com
Firstranker's choice
www.FirstRanker.com www.FirstRanker.com

Stylopharyngeus. IX nerve.

IL

MC

IC

T → Kilionce dehiscense. (Weakest part)

C

RLN, ILA Thy. Px → VAC
Crico Px → RLN

Neuronal incoordination
↓
Bolus producing diverticulum in posterio lateral wall.
↓
ZENKERS DIVERTICULUM

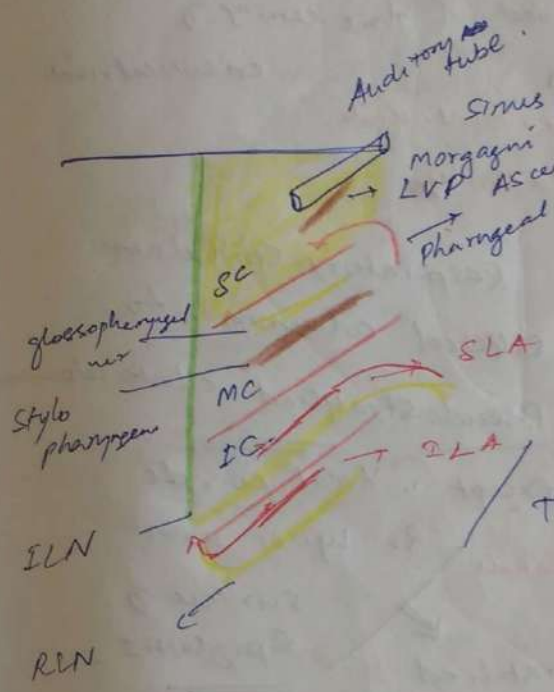

Tracheo oesophageal group.

Hyaline
elastic

LARYNX.

unpaired cartilages (3).

1. Thyroid cartilages → HC
2. Cricoid. → HC (Base of cricoid).
3. Epiglottis. (EC)
(fibroelastic cartilage)

Paired cartilages (4)

1. Arytenoid → Apex (EC), Base (HC)
2. Coriculate (EC)
3. Cuneiform. (EC)
4. Triticeal (EC)

www.FirstRanker.com
Scanned by CamScanner

FirstRanker.com
Firstranker's choice
www.FirstRanker.com www.FirstRanker.com



* Lining epithelium of Larynx Respiratory epithelium
ciliated coloumnar to
pseudo-stratified ciliate coloumn

except 1. Vocal cords.
2. upper part surface of Epiglottis.

Devoid of mucus glands

vocal cord receives mucus from saccule of larynx (oil cane of larynx)

Stratified squamous epithelium.

Muscles of Larynx :-

Controlling inlet of larynx

Controlling RG.

Controlling tension in vocal cords.

www.FirstRanker.com
Scanned by CamScanner

FirstRanker.com
Firstranker's choice
www.FirstRanker.com www.FirstRanker.com

Controlling
Inlet of Larynx.

↓

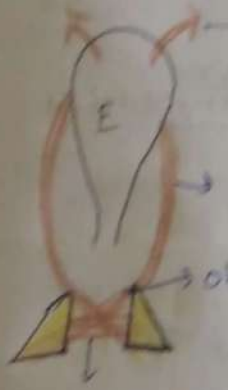

→ Thyroepiglotticus (opening of inlet of larynx).

cont. of oblique arytenoids)

→ Aryepiglotticus : closing of inlet of Larynx.

→ oblique arytenoids.

Transverse arytenoids

Controlling
Rima glottidis

T.S.

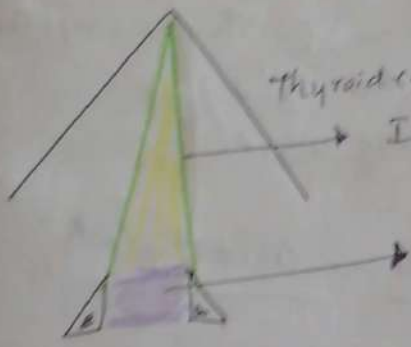

Post. cricoarytenoid (Life Saving) only Abductor.
(Fatty)

www.FirstRanker.com
Scanned by CamScanner

FirstRanker.com
Firstranker's choice
www.FirstRanker.com www.FirstRanker.com

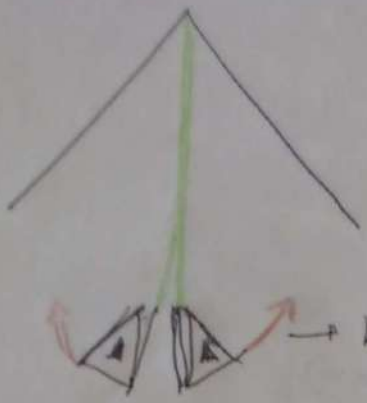

→ Lateral crico arytenoid (Adduction) inter memb RG.
(muscle of whispering)

complete closure of RG ⇒ Inter arytenoids

Controlling tension.

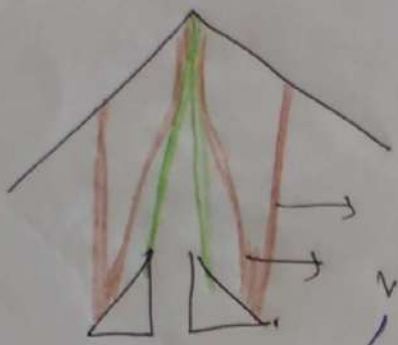

Relaxing the vocal cord.

→ Thyro-arytenoid m/s.
→ vocalis (modulator of larynx).
medial fibre of
(Thyro arytenoid)

Tension Ant 1/3rd
Relax post 2/3rd

Pure tensor of vocal cord crico thyroid.

www.FirstRanker.com
Scanned by CamScanner

FirstRanker.com
Firstranker's choice
www.FirstRanker.com www.FirstRanker.com

Pre epiglottic Space (Boyer's space).

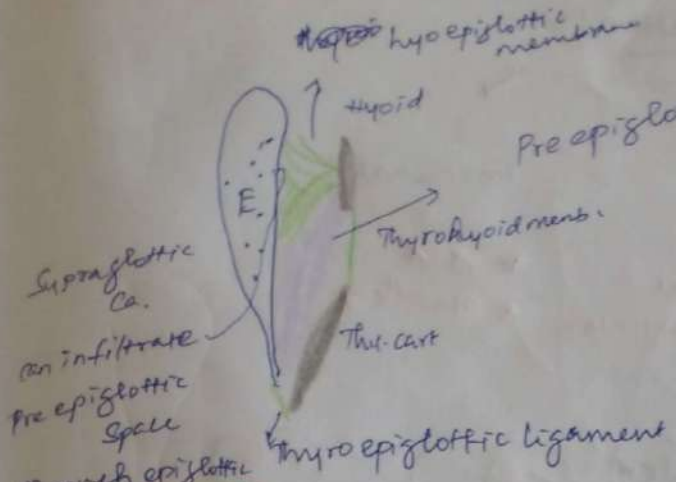

DAY-2

9 AM DEC 2

Blood vessels in Neck

Face :

ECA (8)

(5) (Carotid Δ)

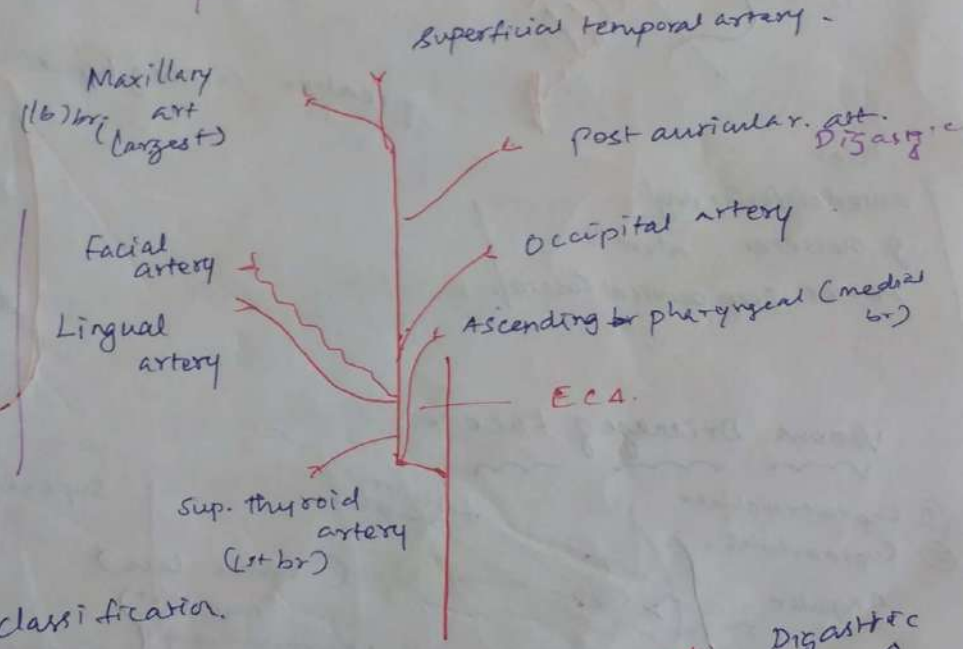

Location Based classification.

Sup thy. art.
Asc. ph. art.
Lingual
Facial
Occipital
- Carotid Δ

Post-auricular art.
Superficial temporal
Maxillary
- face
Digastric Δ

www.FirstRanker.com
Scanned by CamScanner

FirstRanker.com
Firstranker's choice
www.FirstRanker.com www.FirstRanker.com

DEC 2018

Direction based classification:-

Medial	Ant	post	terminal
Asc. pharynx	* sup. thyr * lingual * facial	* occipital * post auricular	* STA * Maxillary

Arterial supply of face

ICA CB FB

STAG

ECA = ICA

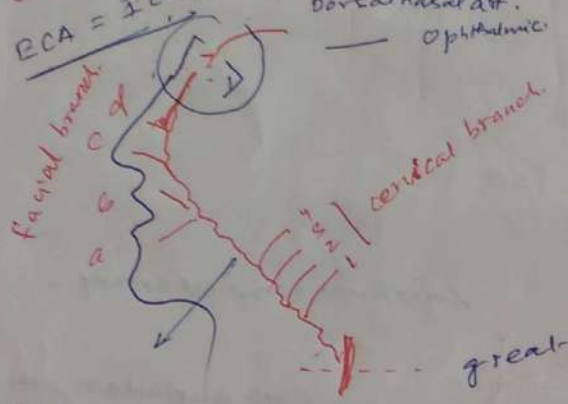

* Submental
* Tonsilar
* Assc. palatine.
* Glandular.

a - Inf labial
b - Sup. labial
c - lat. nasal art.
d - Angular art.
↓
Dorsal nasal art.

Point
anterioinferior angle of messeter where it perces Deep cervical fascia.

Anaesthetist artery
* facial artery @ AIAM
* Sup temporal infront of Tragus

Venous Drianage of Face:-

① supratrochlear.
② supraorbital.

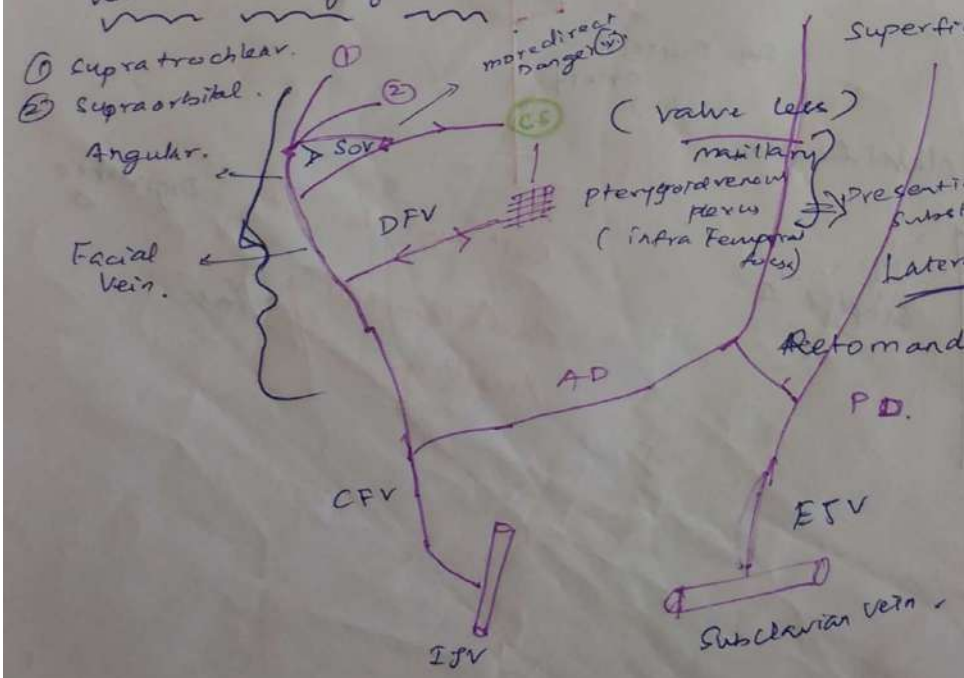

formatory triangle
Post. Div RMV
↑
Post auricular
⇓
EJV

www.FirstRanker.com
Scanned by CamScanner

FirstRanker.com
Firstranker's choice
www.FirstRanker.com www.FirstRanker.com

Maxillary Artery :-

pterys

I Deep to neck & mandible.

II b/w lat. pterygoid.

III pterygomaxillary fissure

I part :- 5 br
(A - ADMI)

A - Acc. meningeal artery Dura
A - Ant. tympanic artery] middle ear.
D - Deep auricular artery]
M - middle meningeal artery. Dura.
I - Inferior alveolar artery. Mandible.

II. Part : 5 br.

2 - Deep temporal artery → Temporalis muscle.

✓ Artery to masseter.
✓ Artery to M. pterygoid.
✓ Artery to L. pterygoid.

III Part :- 6 br (PIG PAS)

P Post. sup. alveolar art.
I Infera orbital art.
G Greater palatine art.

P pharyngeal art.
A Art to pterygoid canal.
S Sphenopalatine artery (Largest br of maxillary art).

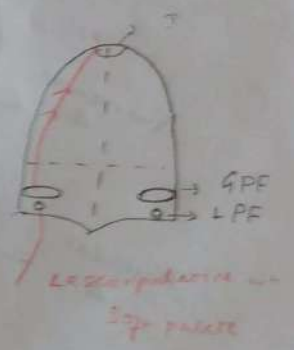

www.FirstRanker.com
Scanned by CamScanner

FirstRanker.com
Firstranker's choice
www.FirstRanker.com www.FirstRanker.com

Subclavian artery :-

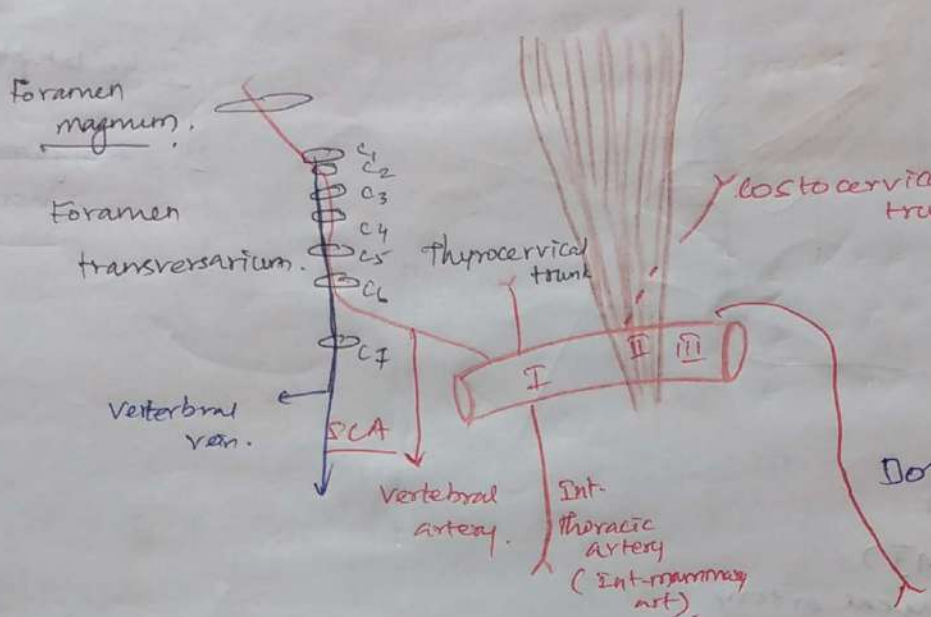

Thyrocervical trunk.

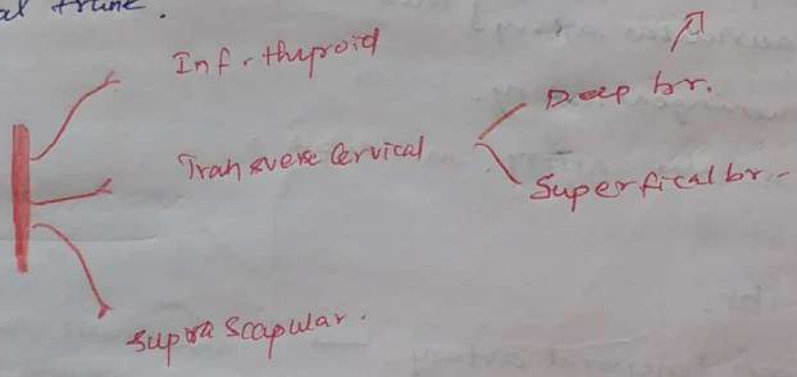

Triangles of Neck :-

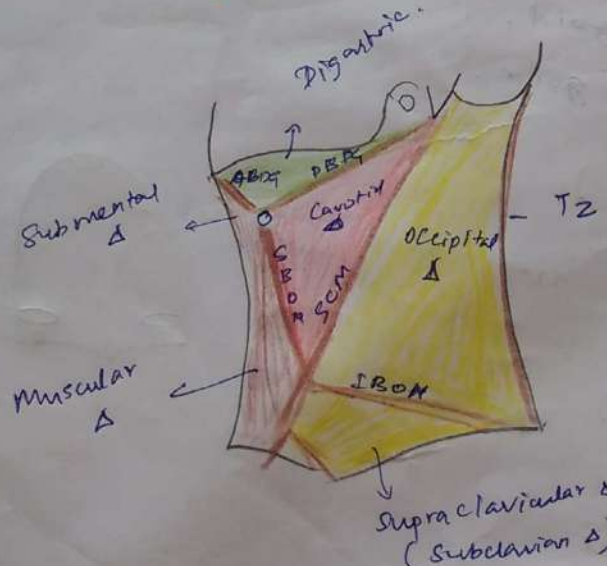

SCM | Spinal Accessory
T2

Ant. Belly — mand
mylohy

Post.

Homohyoid. — Ansa Cervicalis

www.FirstRanker.com
Scanned by CamScanner

FirstRanker.com
Firstranker's choice
www.FirstRanker.com www.FirstRanker.com

[illegible] which supplies skin of face

auriculo temporal nerve most commonly fuses c great auricular nerve in Frey's syndrome. [illegible] Jugular vein in neck. [illegible]

It supplies skin of lobule of ear, skin at angle of mandible *

Post Δ

Greater auricular nerve *

Lesser occipital nerve.

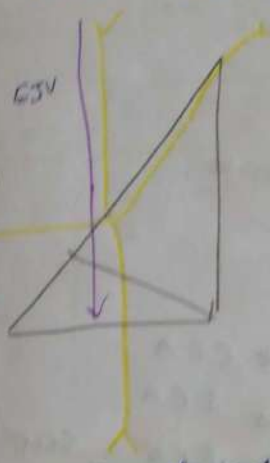

Transverse (Ant) cutaneous nerve of neck

Supraclavicular nerve

ROOF

FLOOR

→ Semi spinalis capitis.

→ Splenius capitis

→ Levator scapulae. (A).

→ Scalenus posterior.

Scalenus medius.

Covered by (Prevertebral fascia.)

SCM | C_3 C_4 (proprioception)

T_2

↓

hybrid (dual nerve supply)

Occipital artery

C_3 C_4 → Spinal Accessory (b/w Prevertebral & Investing layer)

Trunks of Brachial plexus.

Subclavian vessels.

www.FirstRanker.com
Scanned by CamScanner

FirstRanker.com
Firstranker's choice
www.FirstRanker.com www.FirstRanker.com

Carotid Δ

ROOF

1. platysma.
2. Cervical br. of Facial nerve.
3. Transverse cutaneous nerve of Neck.

Contents

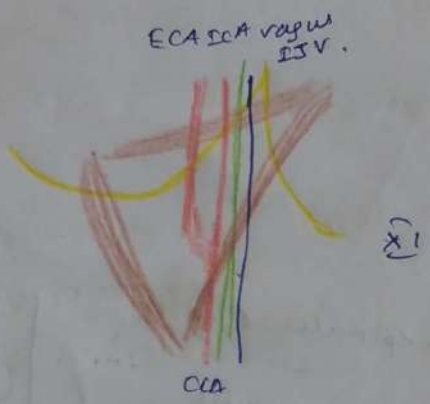

- ★ CCA
- ★ ICA
- ★ ECA
  - ✓ Sup. thyroid
  - ✓ Lingual
  - ✓ Ascending pharyngeal
  - ✓ occipital
  - ✓ Facial.
- ★ IJV
- ★ X, XI, XII
- ★ Ansa cervicalis.

Relations of Hyoglossus :-

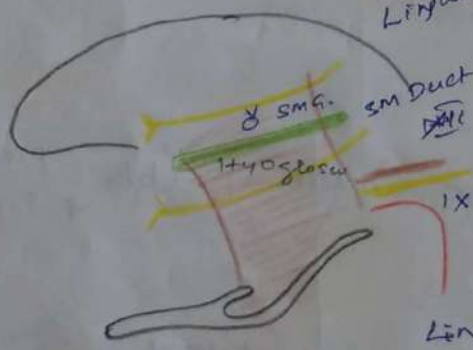

Superficial.

- ✓ Lingual nerve
- ✓ SMG.
- ✓ XII nerve
- ✓ SM Duct.

Deep.

- ✓ Lingual artery
- ✓ IX nerve.
- ✓ Stylopharyngeus muscle

www.FirstRanker.com
Scanned by CamScanner

FirstRanker.com
Firstranker's choice
www.FirstRanker.com www.FirstRanker.com

Parotid duct (Stensen's duct)

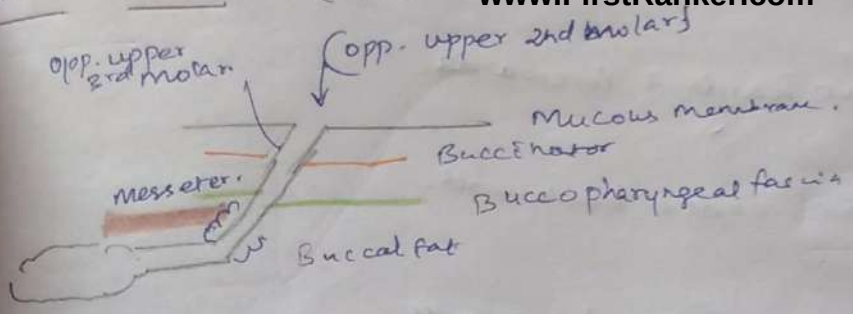

7-5

BBBM.

Temperomandibular Junction.

Type:- Condylor (Bicondylor joint).

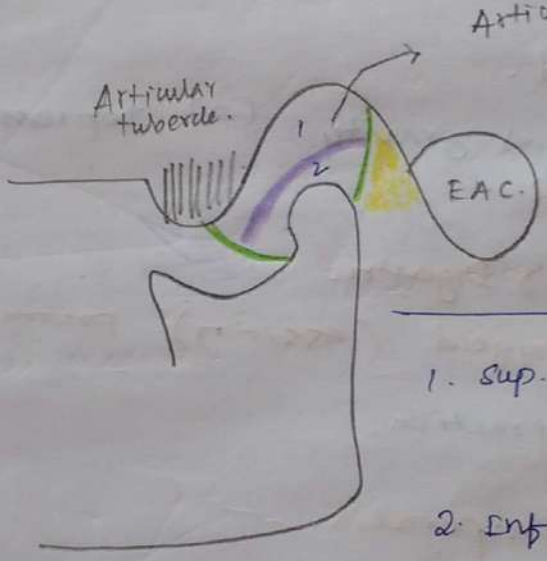

1. Sup. Joint cavity → sliding / Gliding movement

2. Inf. Joint cavity → Rotatory movements.

Supports of TMJ

TRUE

(1) Capsule → Loose & laxative → Up part.
Tense & thick → L. part.

(2) Lateral Ligament →

FALSE

(1) Stylomandibular ligament.

(2) Sphenomandibular ligament.



www.FirstRanker.com
Scanned by CamScanner

FirstRanker.com
Firstranker's choice
www.FirstRanker.com www.FirstRanker.com

Muscles & movements :-

Temporalis	Down wards & forewards.
Messeter.	Down wards & backward.
M. pterygoid	Down wards & backwards.
L. pterygoid.	Backwards

Closing of mouth (or) elevation of mandible.

- ✱ Temporalis
- ✱ messeter
- ✱ M. pterygoid.

opening of mouth => gravity (or) Depression of mandible.

- ✱ mylohyoid
- ✱ Ant. belly. of Digastric
- ✱ Lateral pterygoid (Assisting) protraction)

Protraction.	Retraction.
L. pterygoid.	Temporalis.
Assisted by M.P, Messeter.	(forewards)
(Backwards)	

Side ware movement alternate M. pterygoid & L-pterygoid.

www.FirstRanker.com
Scanned by CamScanner

FirstRanker.com
Firstranker's choice
www.FirstRanker.com www.FirstRanker.com

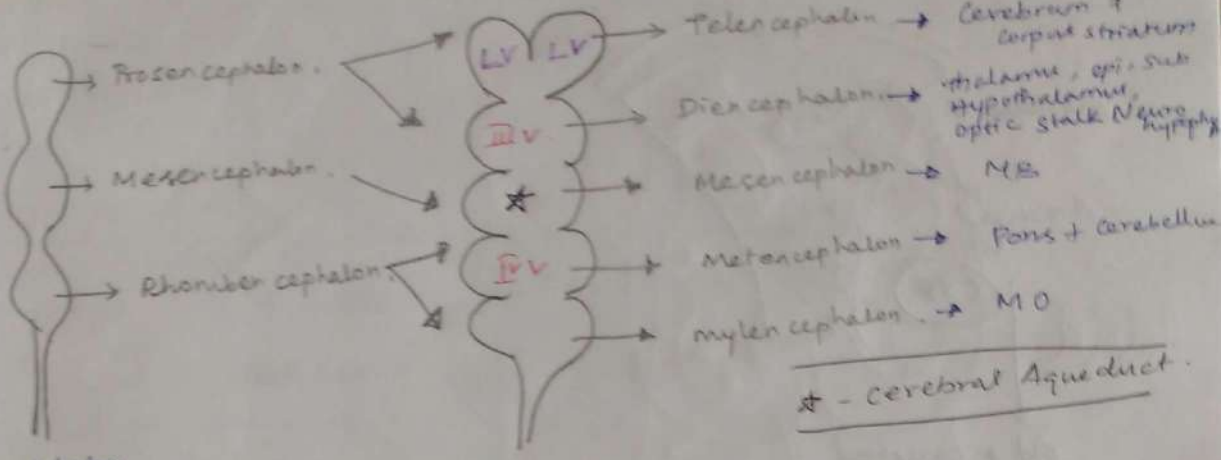

Neural tube
(Neuro Ectoderm).

Blood Brain Barrier :-

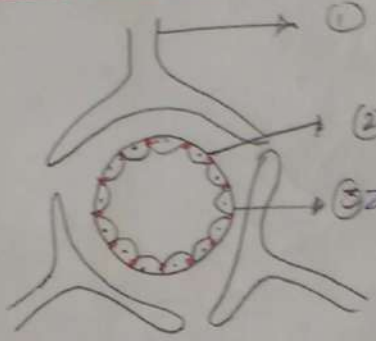

1. Astrocyte
2. B/s memp & capillary endol
3. Zona occludens / tight junct.

(True BBB)

* Areas devoid of Blood Brain Barrier (Circum Ventricular organs)

1. Area of Postrema. (IV vent).
2. Median Eminence.
3. Pineal gland.
4. Neurohypophysis.

(III vent)

5. OVLT :- Organum Vasculosum Lamina Terminalis.

Areas devoid of pain fibres.

- Brain parenchyme.
- Ependyma.
- Duramater

↓

Neither forming DPS nor covering Br

- Pia mater
- Arachanoid mater
- Choroid plexus.

www.FirstRanker.com
Scanned by CamScanner

FirstRanker.com
Firstranker's choice
www.FirstRanker.com www.FirstRanker.com

Arachanoid matter

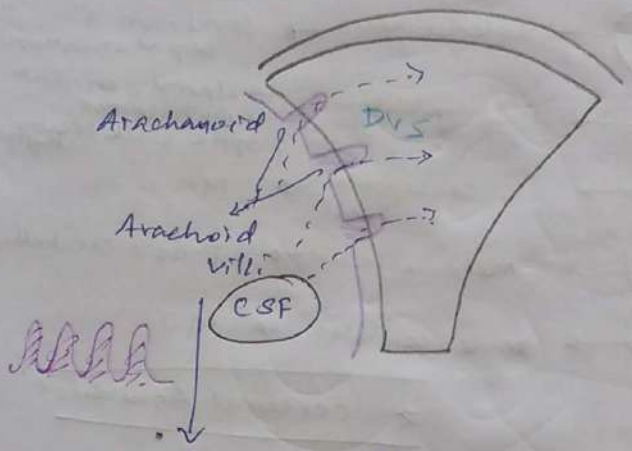

old & crusted

↓

Arachanoid Granulations.

⊕ along superior sagital sinus.

Meningoma & Arachanoid origin along SSS.

Subarachanoid cisterns:-

* Large Subarachanoidal Space:-

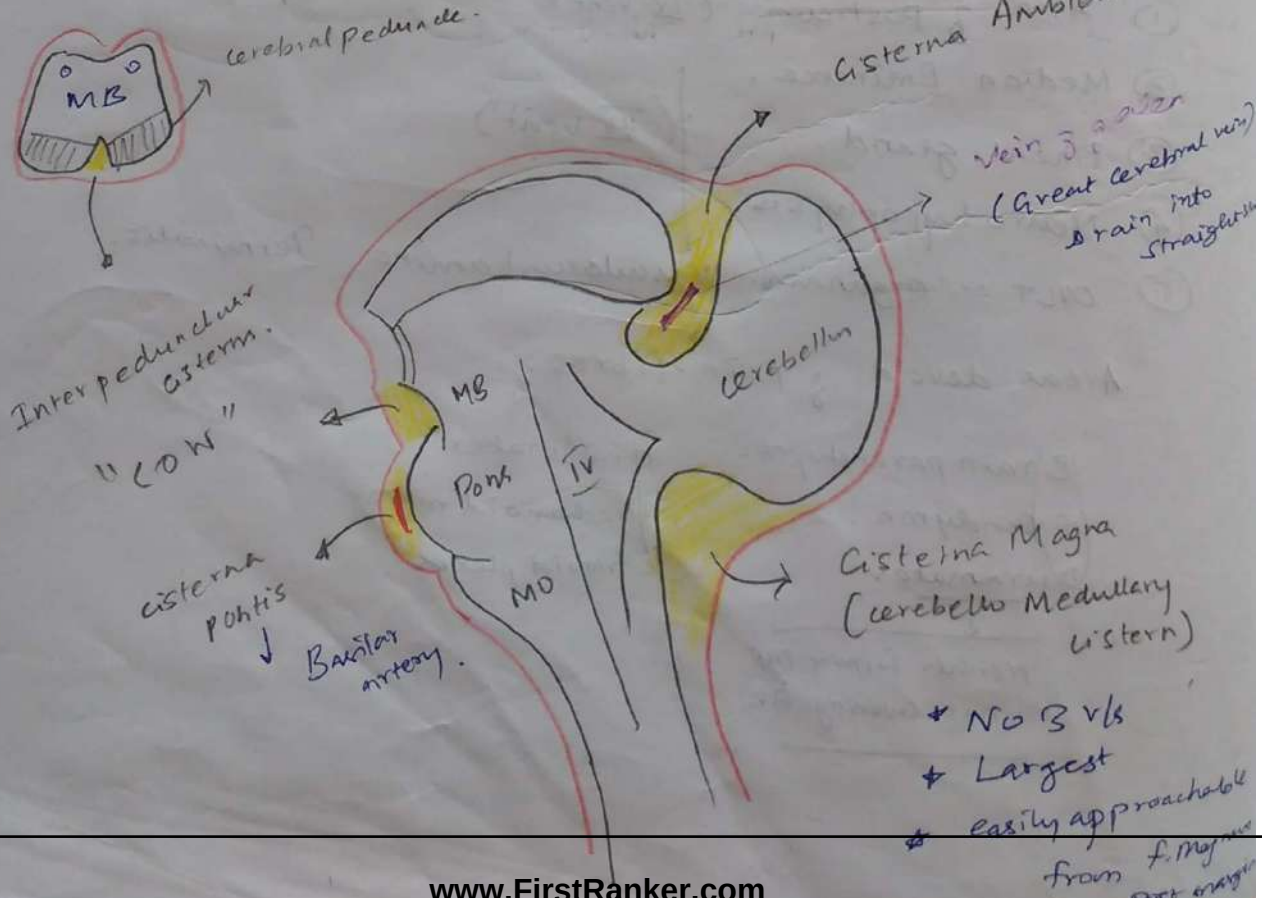

www.FirstRanker.com
Scanned by CamScanner

FirstRanker.com
Firstranker's choice
www.FirstRanker.com www.FirstRanker.com

Sylvian cistern.

SPINAL CORD

Extends : Adults :- C_1 to Lower border of L_1

Neonates :- C_1 to Upper border of L_3

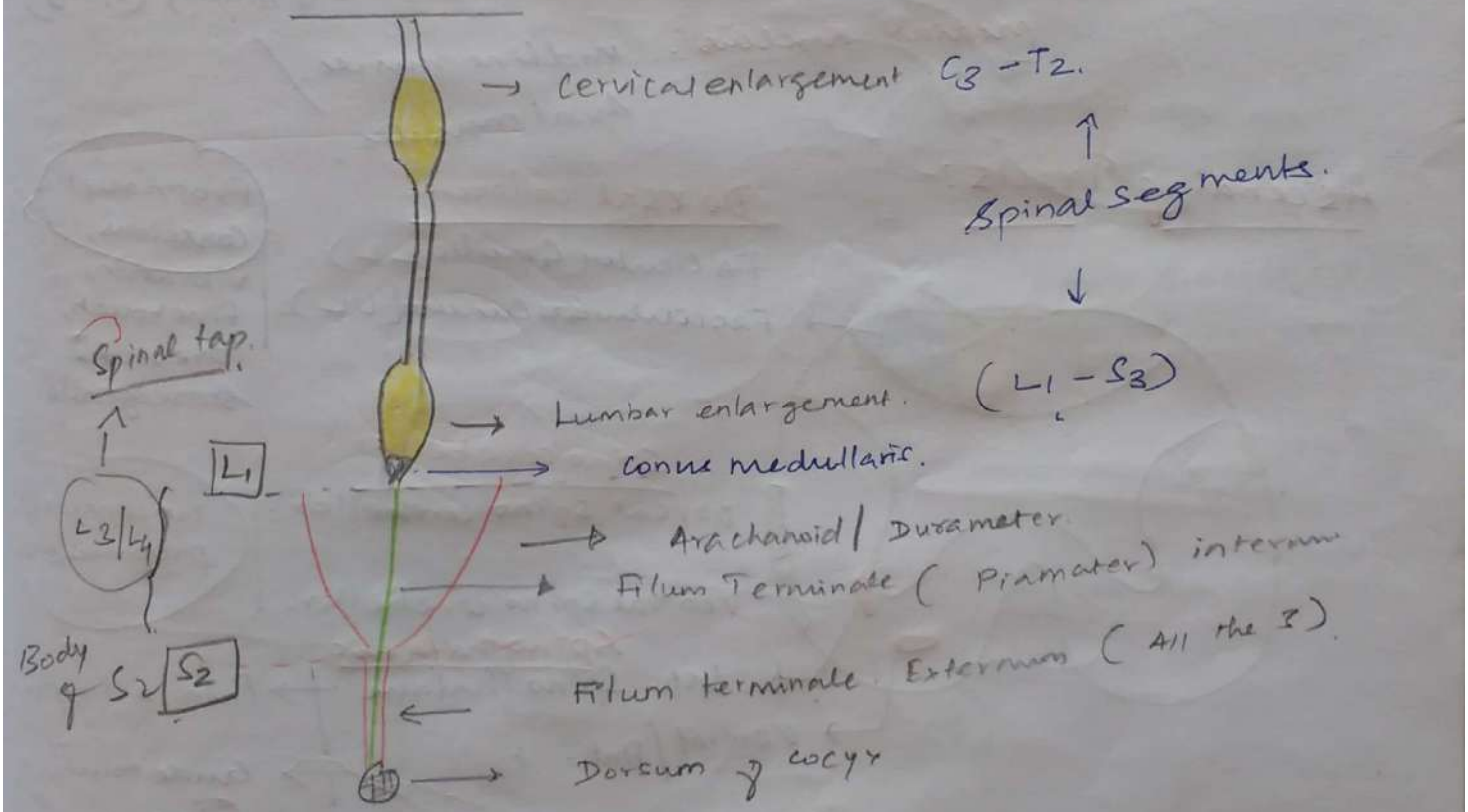

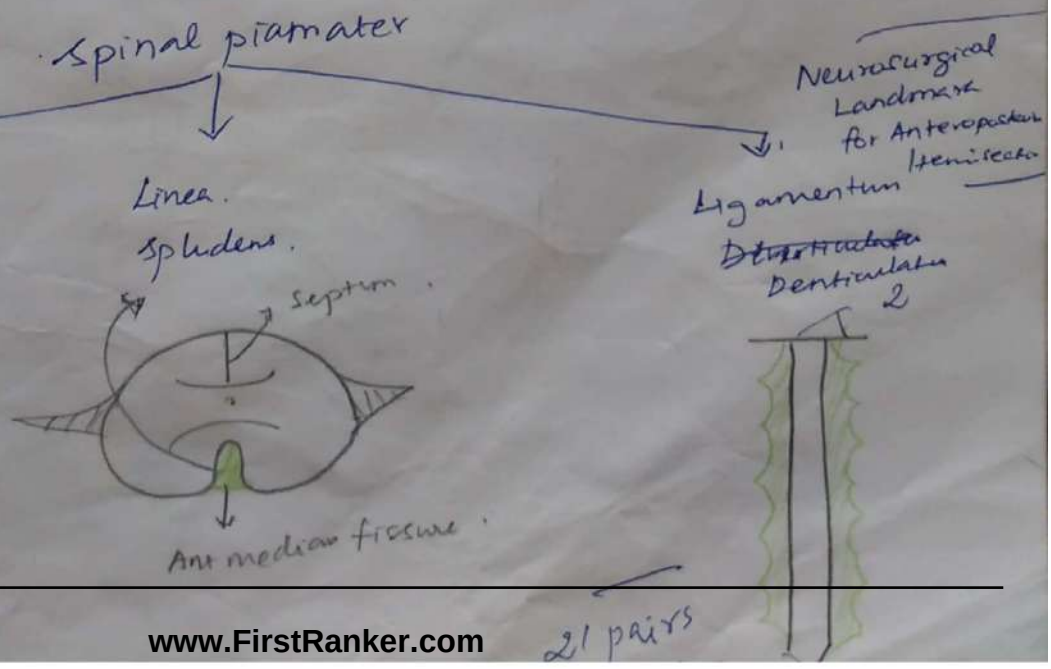

www.FirstRanker.com
Scanned by CamScanner

FirstRanker.com
Firstranker's choice
www.FirstRanker.com www.FirstRanker.com

Grey matter: 8 S-C

Spino cerebellar

Nucleus Dorsalis. (Clarke's column)

Substantia gelatinosa. (R-S) for Spino Relay ⇒ thalamus

Nucleus propius. ⇒ Dorsal Colum (Post. Colum)

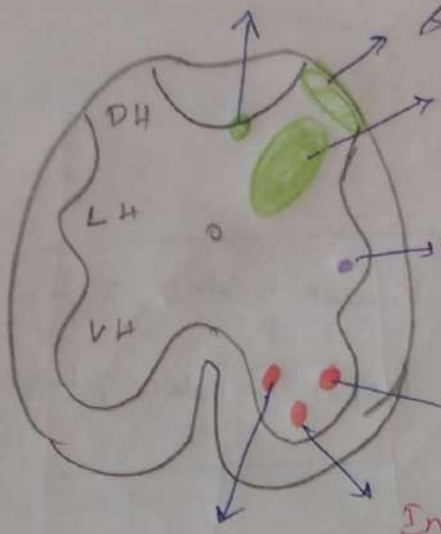

Intermedio lateral Nucleus → Sympathetic thoraco lumbar ($T_1 - L_2$)

→ Parasymp ($S_2 - S_4$)

Lateral nucleus. → Limbs muscles.

Intermediate nucleus. → Phrenic ($C_3 - C_5$)

→ Sp. Accessory ($C_1 - C_5$)

Medial nucleus. → Midline muscle / Axial muscles.

Ascending Tracts :-

Dorsal colloum.

Fasiculus Gracilis (LL)

Fasiculus Cuneatus (UL)

→ Proprioception, Conscious, vibration, fine touch, pressure stereognosis.

Spino cerebellar

Dorsal spino cerebellar.

Ventral spino cerebellar.

→ unconscious proprioception

Spinothalamic

Lat. Spino Thalamic → Pain & temp.

Ventral / Ant. → Crude touch, (-x) pressure major.

www.FirstRanker.com
Scanned by CamScanner

FirstRanker.com
Firstranker's choice
www.FirstRanker.com www.FirstRanker.com

Spinothalamic tract :-

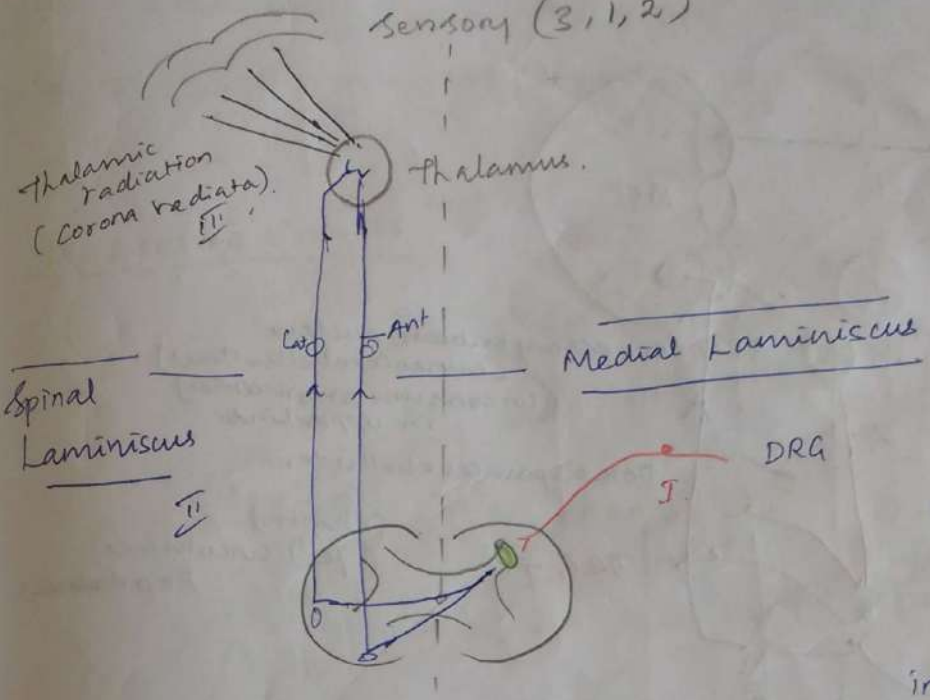

track enters into Spinal cord
lamniscus
injury to Any lamniscus.
effect is on contralater

* Always 2nd order neuron decussates to opposite site.

Dorsal Column Tract :-

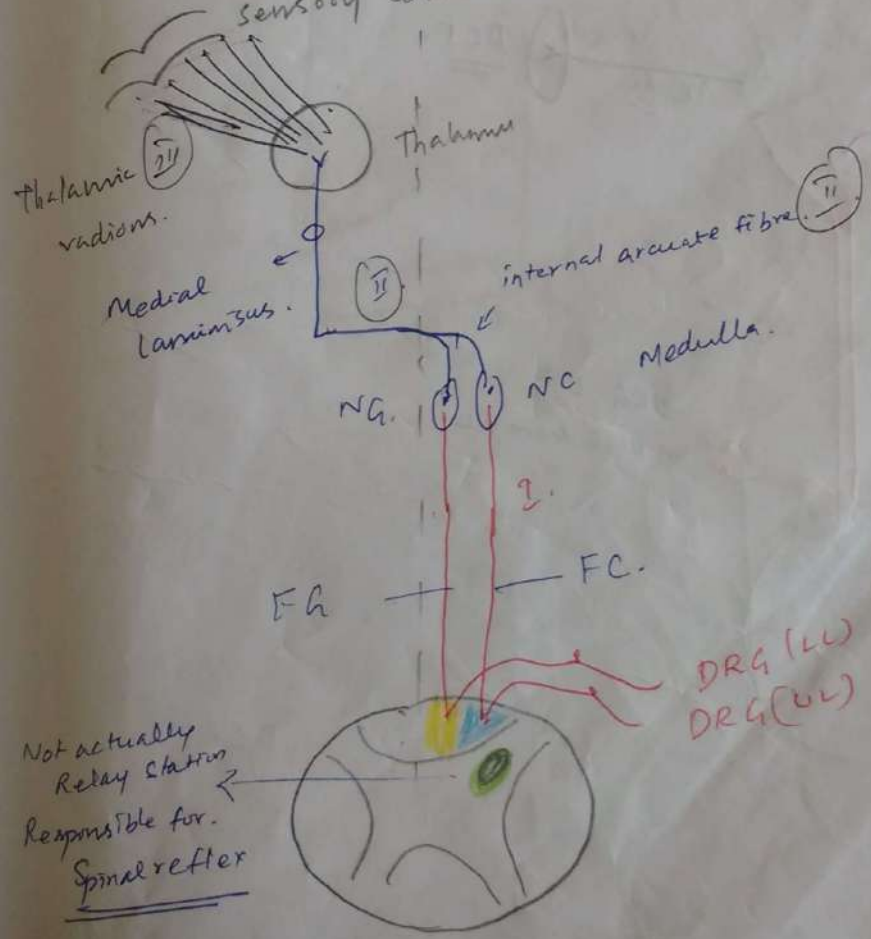

www.FirstRanker.com
Scanned by CamScanner

FirstRanker.com
Firstranker's choice
www.FirstRanker.com www.FirstRanker.com

Spino cerebellar tract

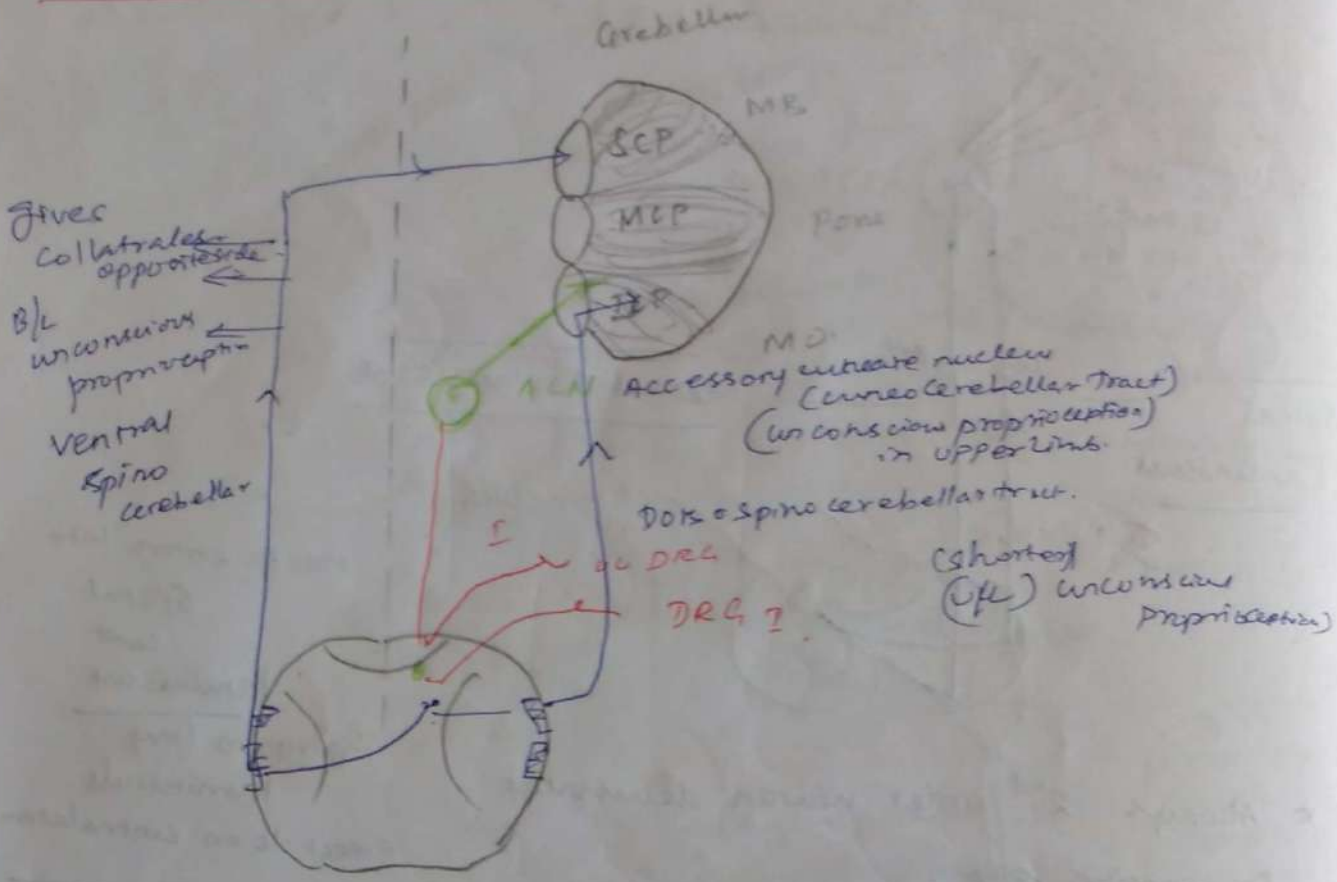

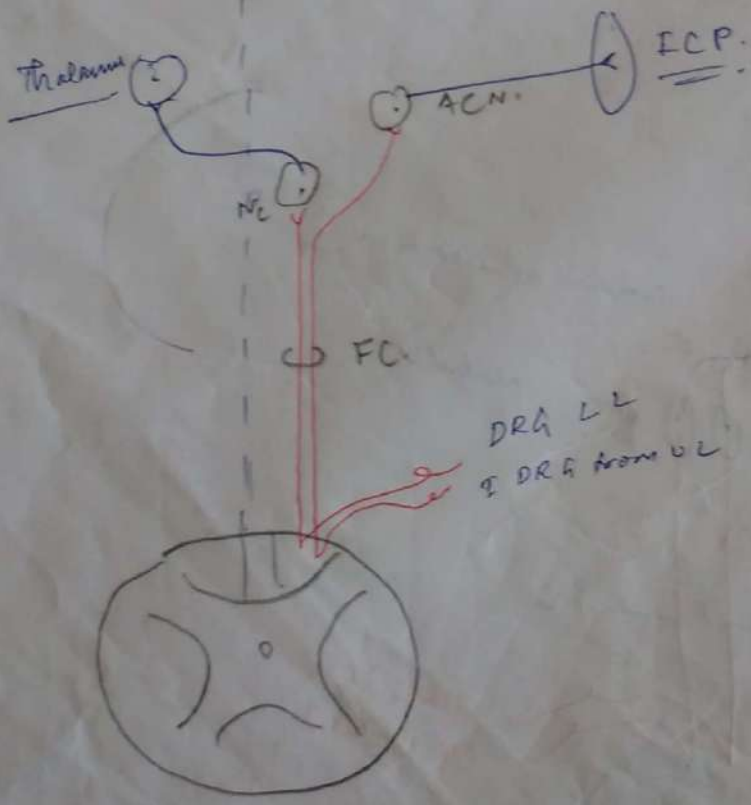

www.FirstRanker.com
Scanned by CamScanner

FirstRanker.com
Firstranker's choice
www.FirstRanker.com www.FirstRanker.com

* injury to Fasiculus Gracilis ipsilateral loss of
* injury to (FC) ipsilateral loss of both conc/un conc. proprio (UL)

Descending Tracts :-

Pyramidal Track

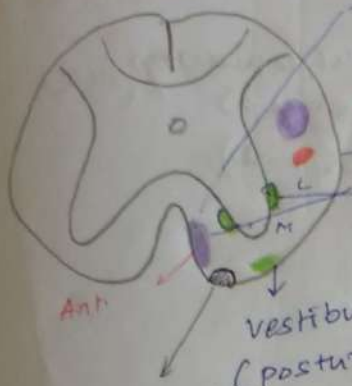

- uncrossed (decussation) → Skilled Voluntary movements.
- Lat (Crossed)
  - Rubro spinal track → facilitates flexors inhibits extensors.
  - L & M Reticulo Spinal tract → Tract via which Hypothalamus controls lat. horn & Spinal cord.
- Vestibulospinal track (postural tract).
- Tectaspinal tract.

FE
IF.

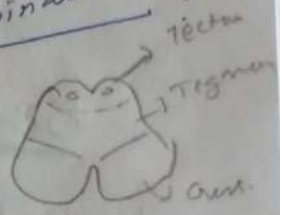

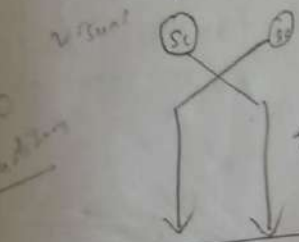

* Coordinated movement of Head & Eyeball & UL Based on visual stimulus

www.FirstRanker.com
Scanned by CamScanner

FirstRanker.com
Firstranker's choice
www.FirstRanker.com www.FirstRanker.com

Pyramidal tract

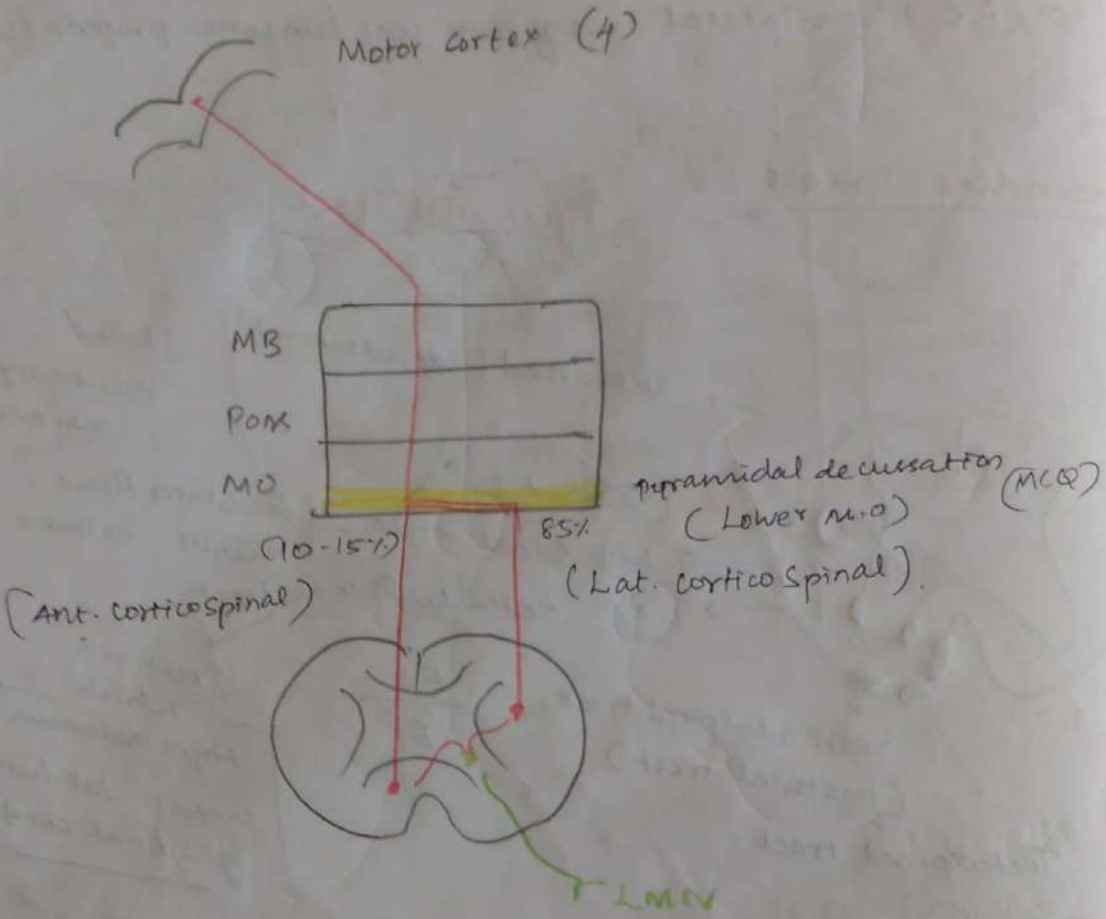

BRAIN STEM

Ventral aspect & Brainstem :-

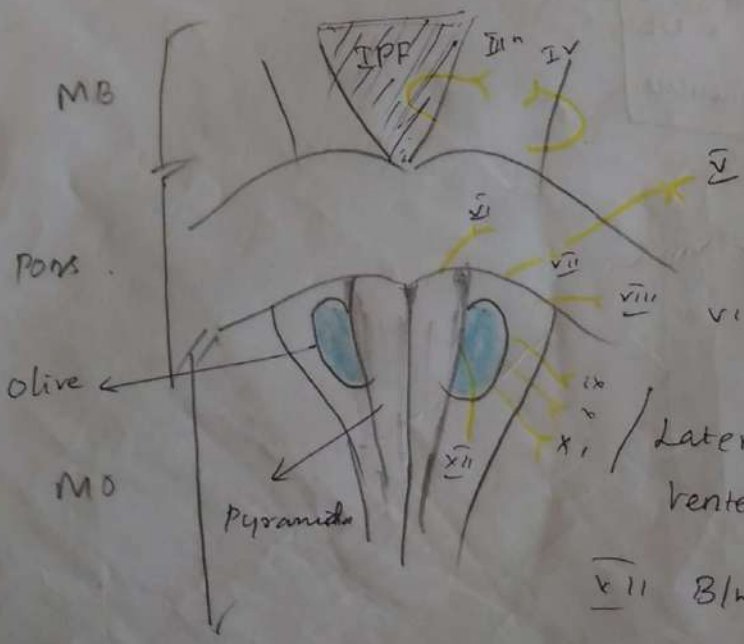

VI, VII, VIII Coming from ponto medullary junction

/ Lateral to olive /
Ventero lateral sulcus

XII B/w pyramid & olive
Ventero medial -

www.FirstRanker.com
Scanned by CamScanner

FirstRanker.com
Firstranker's choice
www.FirstRanker.com www.FirstRanker.com

Inter peduncular fossa :-

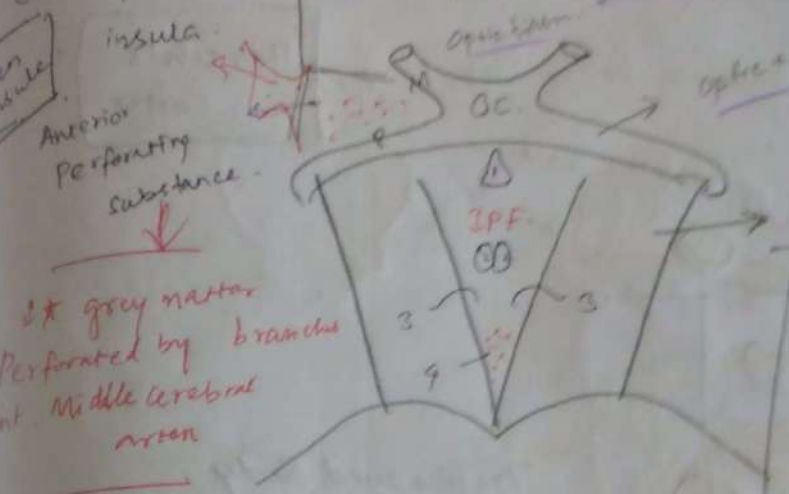

* grey matter Perforated by branches of Ant. Middle cerebral artery

1. Infundibulum / Tuber cinereum
2. Mammillary bodies
3. 3rd nerve
4. Posterior perforating substance

* grey matter perforated by branches of posterior Cerebral artery

Dorsal aspect of Brainstem :-

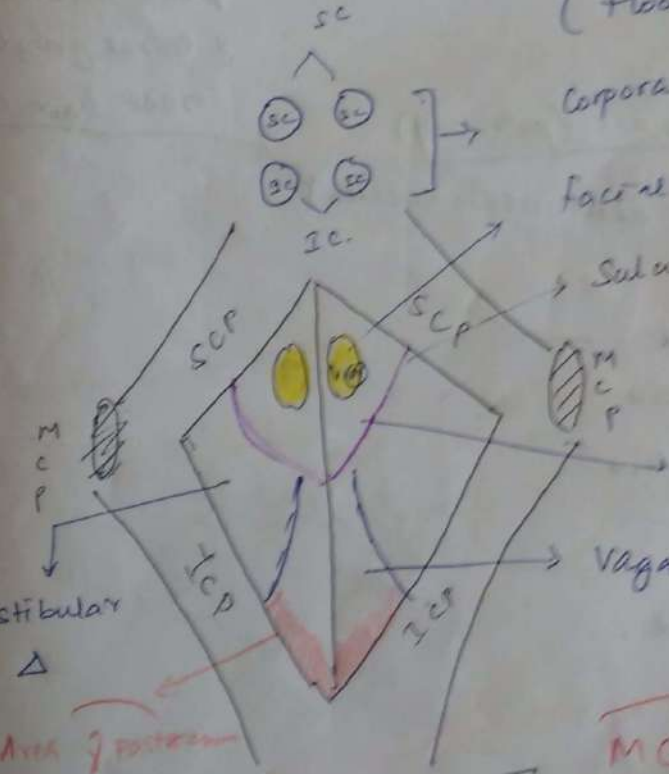

(Floor of IV th ventricle)

Corpora Quadrigemina.

Facial colliculus.

Sulcus limitans.

Hypoglossal Δ

Vagal Δ

Vestibular Δ

VI, VIII, X, XII

Nuclei present in floor of fourth ventricle

Area postrema (vomiting centre) Devoid of BBB

MCQ

MCQ

int. genu resultant of ventricular migration of motor facial nucleus

NEURO BIOTANIC

for faster revision refer.

www.FirstRanker.com
Scanned by CamScanner

FirstRanker.com
Firstranker's choice
www.FirstRanker.com www.FirstRanker.com

Auditory Cortex (41, 42) | Herschl's

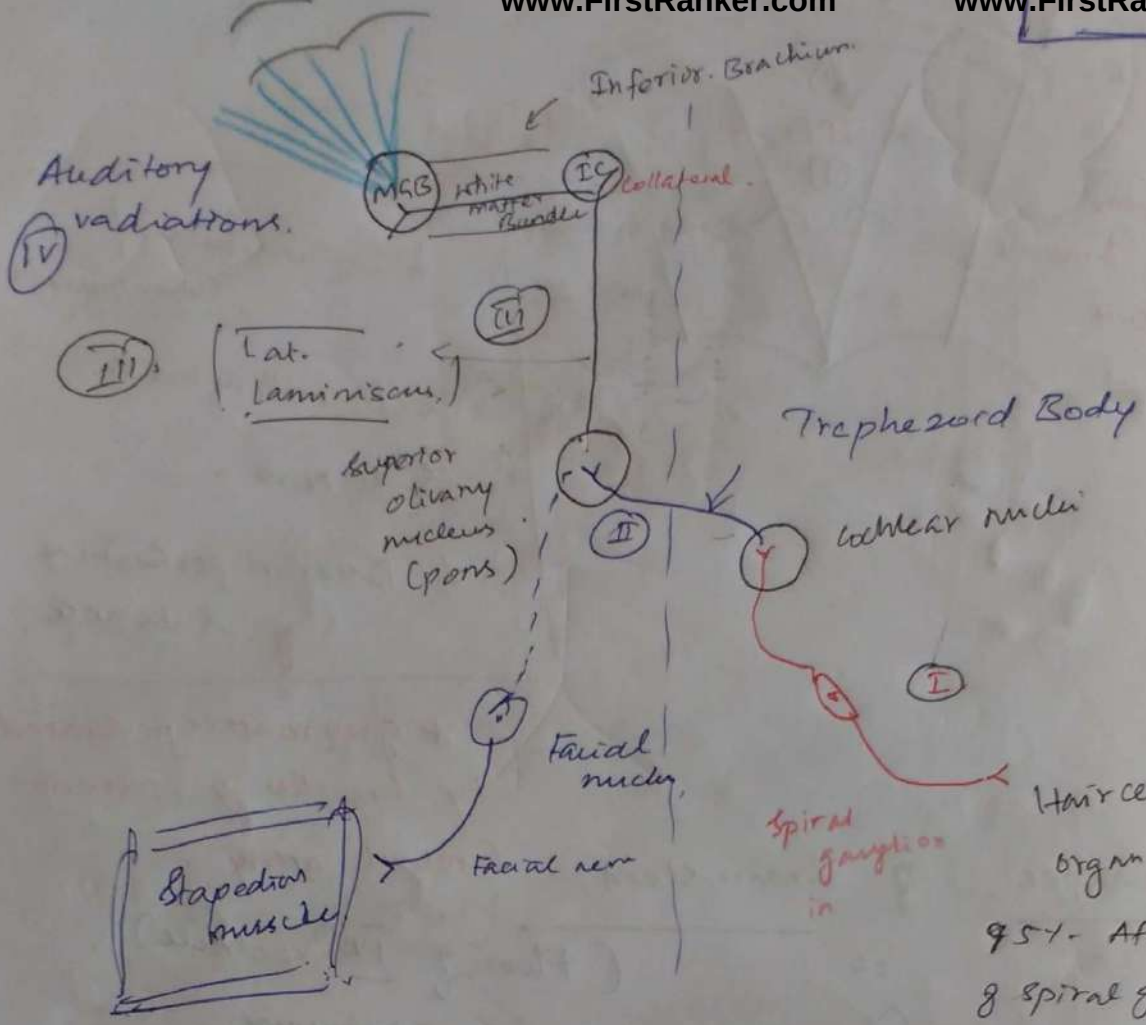

95% Afferent fibres of spiral ganglion inner hair cells

Stapedial Reflex arc (pathway)

- ✓ Spiral ganglion neurons (in cochlea)
- ✓ auditory nerve
- ✓ Cochlear nucleus
- ✓ Sup. Olivary nucleus
- ✓ Facial nerve nucleus
- ✓ Facial nerve
- ✓ Stapedius muscle.

www.FirstRanker.com
Scanned by CamScanner

FirstRanker.com
Firstranker's choice
www.FirstRanker.com www.FirstRanker.com

Trigeminal Thalamic pathway :-

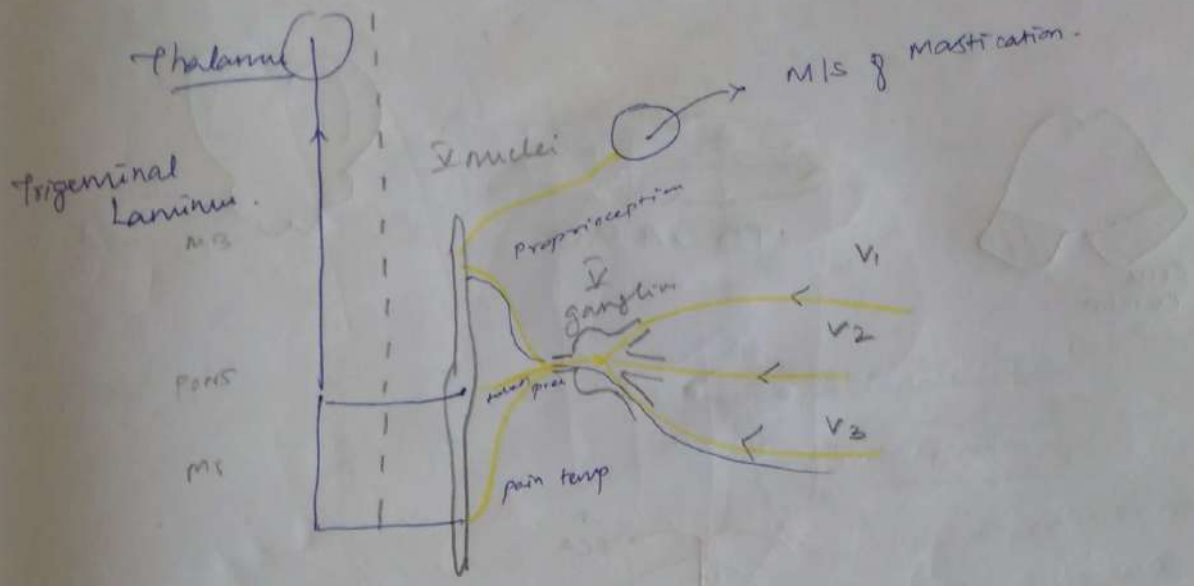

Injury to - - - - - -

(1) Medial Laminiscus. → Contralateral loss of Cons c. proprioception

(2) Lateral L. → C/L hearing loss.

(3) Spinal. → C/L loss of pain, temperature from the body

(4) Trigeminal. → C/L loss of pain & temperature from face. Touch, pressure.

★ Inter nuclear Ophthalmoplegia.

(MLF) Medial Longitudinal Fasiculus Syndrome.

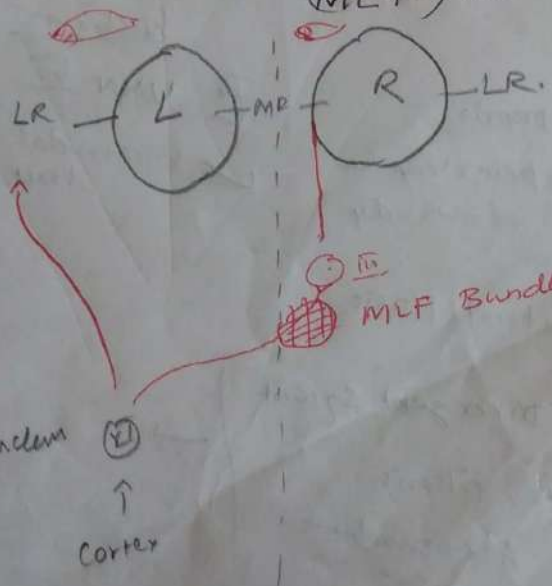



also Horizontal nystagmus due to Abducent nucleus

Over firing of

www.FirstRanker.com
Scanned by CamScanner

FirstRanker.com
Firstranker's choice
www.FirstRanker.com www.FirstRanker.com

M.B

Pons

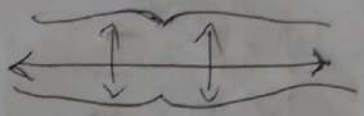

M.O



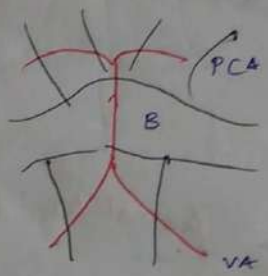

Midbrain Syndrome:-

- Benidict's syndrome.
- Weber's syndrome

★ UMN of VII

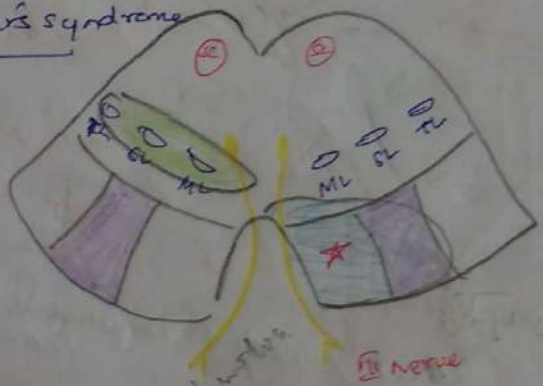

Pain temp loss

Paralysis

Benedicts

✓ ML → c/L loss of conc. proprio.

✓ TL → c/L loss ~~[illegible]~~ pain & temp face

✓ SL → c/L loss of " Extrinsic body

✓ III →

LPS → Ipsilateral ptosis.

(LMN) I/L Divergent Squint.

MR → Spincher pupillae, ciliaris

Light Accommodation

Webers

III. UMN VII c/L Lower half face

✓ Pyramidal tract c/L hemiplegia

www.FirstRanker.com
Scanned by CamScanner

FirstRanker.com
Firstranker's choice
www.FirstRanker.com www.FirstRanker.com

Pontine syndromes:-

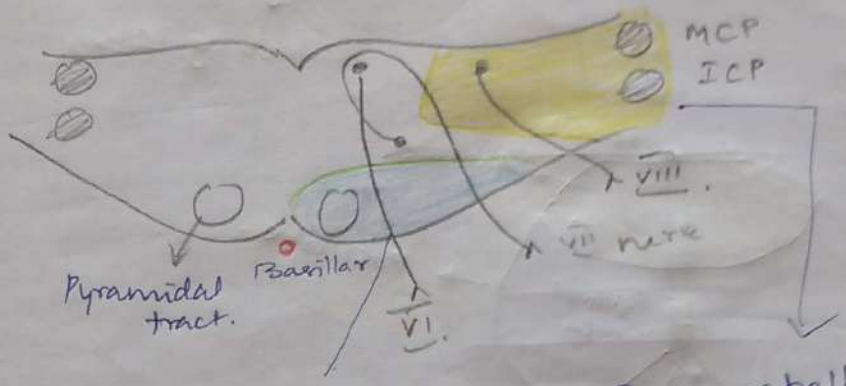

Millard Gubler Syndrome

Acoustic Neuroma

VI → I/L Convergent Squint

VII — I/L Facial paralysis

Pyramidal → C/L Hemiplegia.

Pontocerebellar Angle Syndrome.

Basillar Stroke

VII - I/L facial paralysis

VIII - I/L Hearing loss

MCP / ICP — I/L ataxia.

(X) Abducent Alternating Hemiplegia

Medullary syndromes:-

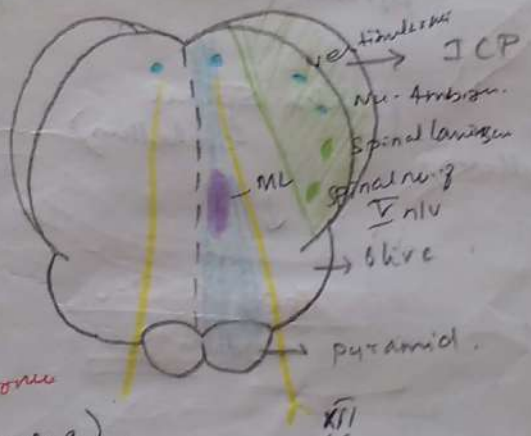

Medial Medullary syndrome (Dejerine)

ML → C/L loss of Conc. proprio

Pyramid → C/L Hemiplegia.

XII → I/L tongue Paralysis.

Deviates on Same side on protrusion of tongue.

Lateral Medullary syndrome (Wallenberg Syndrome).

* ICP → I/L Lateral Ataxia.
* Vestibular → Vertigo, vomiting, nystagmus
* N. Ambiguus → IX, X, XI I/L bulbar paralysis loss of gag reflex.
* Spinal Lemniscus → C/L loss of Pain, temperature Entire Body
* Spinal nucleus of V nerve → I/L loss of pain, temperature from face.

(IX)

www.FirstRanker.com
Scanned by CamScanner

FirstRanker.com
Firstranker's choice
www.FirstRanker.com www.FirstRanker.com

CEREBELLUM

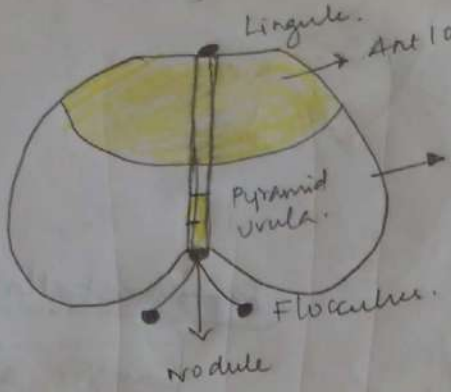

Classification.

Archicerebellum (oldest)
↓
Lingular + Flocculonodular lobe
(aka Vestibular cerebellum)
↓
Axial stability

Paleocerebellum (next to appear)
↓
Ant. lobe + pyramid, uvula.
(aka Spinal cerebellum)
↓
Appendicular stability

Neocerebellum (Recurrent)
↓
post. lobe except Pyramid & uvula
(aka cerebro cerebellum)
↓
Smooth execution of voluntary movements.

www.FirstRanker.com
Scanned by CamScanner

FirstRanker.com
Firstranker's choice
www.FirstRanker.com www.FirstRanker.com

Cerebellar Cortex (Grey matter)

White matter.

Deep cerebellar nuclei

3 Layers of Cerebellar Cortex (Out to In)

1. Molecular Layer.
2. Purkinje Layer
3. Granular Layer.

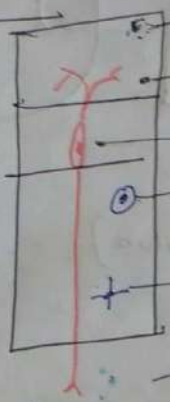

Stellate cells. Inhi (−)
Basket cells. Inhi (−)
Purkinje cell
Granule cells Exci (+)
Golgi cells. Inhi (−)

efferent from cerellum

* Purkinje Largest only efferent from Cortex.
* Efferent from Cerebellum Deep cerebellar nuclei.

Deep Cerebellar Nuclei

D - Dentate nucleus → Largest nucleus / Na of Neocerebellum
E - Emboliform nucleus.
F - Fastigial nucleus. Nucleus of Paleocerebellum
G - Globose nucleus

* Fastigial Nucleus → Na of Archaecerebellum

D (E) F (G) I

E + G = Interpositus Nucleus.

www.FirstRanker.com
Scanned by CamScanner

FirstRanker.com
Firstranker's choice
www.FirstRanker.com www.FirstRanker.com

Afferent fibres

Mossy fibres

climbing fibres.

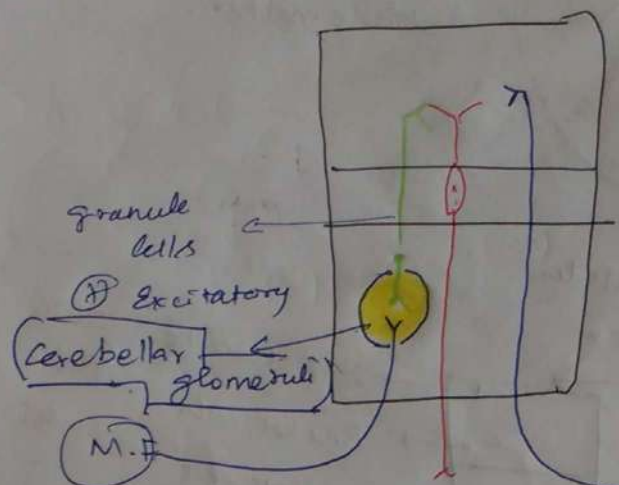

CF → Olivo cerebellar Tract

Para olivocerebellar Tract

Rest all apart from (olivo & para olivocerebellum)

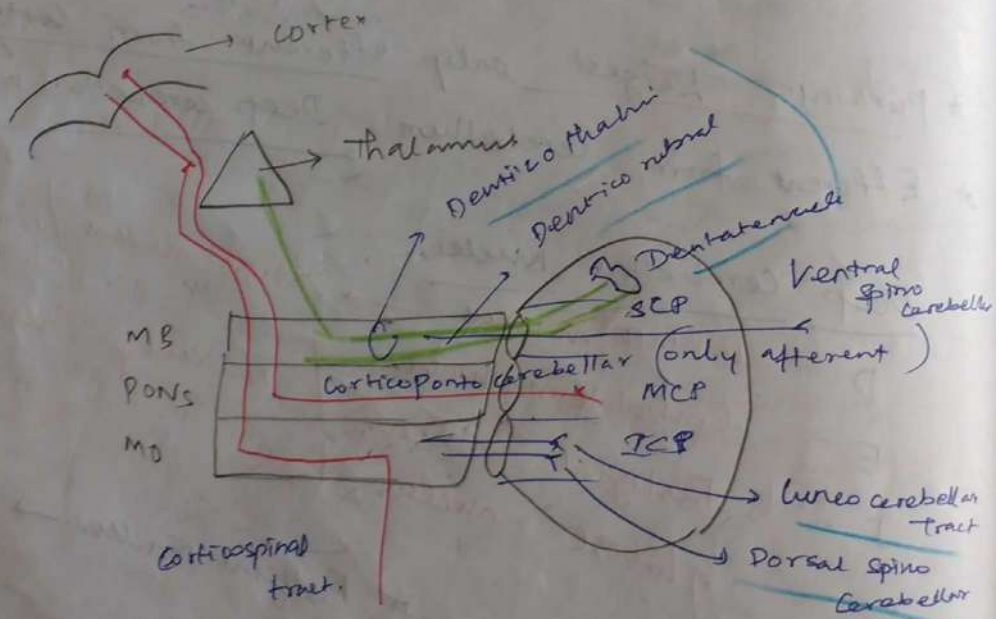

www.FirstRanker.com
Scanned by CamScanner

FirstRanker.com
Firstranker's choice
www.FirstRanker.com www.FirstRanker.com

Types of Sulci

Limiting Sulcus



separates two diff areas at FLOOR

eg central sulcus.

Operculated Sulcus.

Just like limiting Sulcus but transition at Lip (or) margin.

(eg) Lunate Sulcus.

Axial Sulcus

Around which Cortex will develop.

(eg) posterior part of Calcarine Sulcus

Complete sulcus.

Deep enough to indent the wall of Ventricle.

(e.g) Ant. part of Calcarine Sulcus → Collateral.



* Remaining All Sulcus are called as incomplete Sulcus

Superior Lateral Sulcus:- Central sulcus

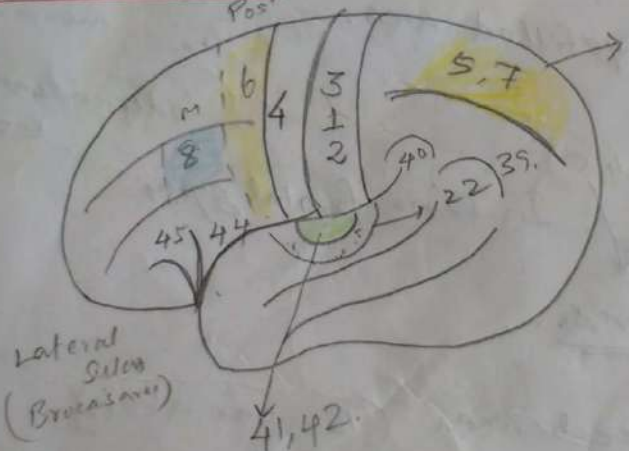

www.FirstRanker.com
Scanned by CamScanner

FirstRanker.com
Firstranker's choice
www.FirstRanker.com www.FirstRanker.com

Area (3, 1, 2) :

Post central gyrus

↓

Primary sensory area.

Area 5, 7 :

Superior parietal lobe

↓

Sensory association area.

Area (4) :

Pre central gyrus

↓

Primary motor area. (origin of pyramidal tract)

Area (6) Post part of Sup. Frontal Gyrus, MFG, IFG.

↓

Premotor area. (Origin of Extrapyramidal tract)

Area (8) : Middle frontal gyrus

↓

Frontal eyefilled area. (continuation scanning movement of eyeball) (independent of visual stimulus)

Area ~~44~~ (44, 45) : In ferio-frontal gyrus

↓ ↓

Pars opercularis Pars Δs.

Motor Speech area (Broca's area)

↓ # # injury

"Motoraphasia"

www.FirstRanker.com
Scanned by CamScanner

FirstRanker.com
Firstranker's choice
www.FirstRanker.com www.FirstRanker.com

Area (41, 42) : Superior temporal gyrus (Herschl's Convolution).

↓

Primary Auditory area.

Area (22) STG.

↓

Auditory association area.

Area (39, 40) : Angular & supramarginal gyrus

↓

"Sensory speech area"

(or)

Wernicke's area — 22, 39, 40

Medial Surface of Brain :-

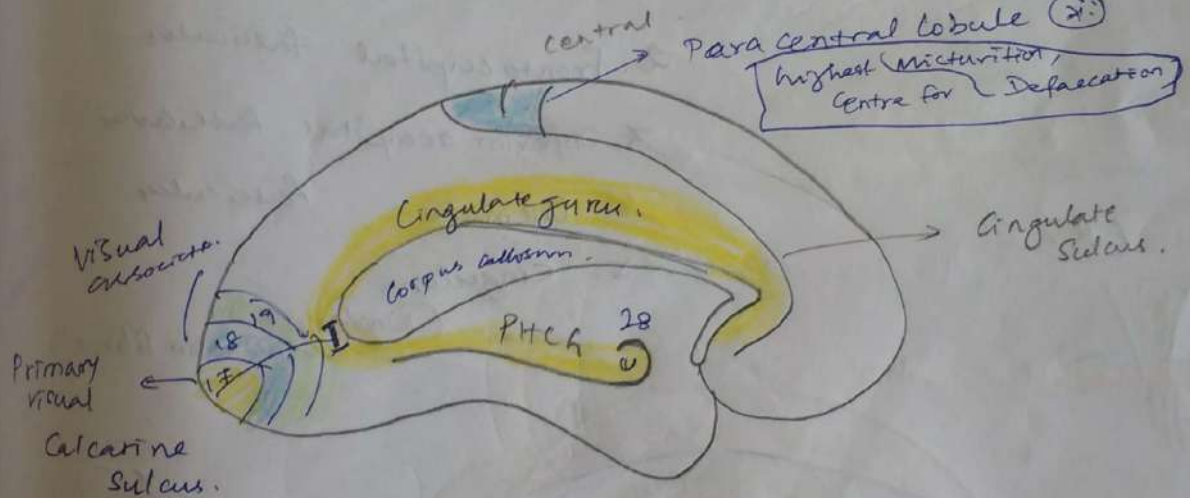

I - Isthmus

PHCG : Parahippocampal Gyrus.

U : Uncus — 28 primary olfactory area.

Limbic System :-

Components.

- Cingulate gyrus
- PHCG
- I
- U

www.FirstRanker.com
Scanned by CamScanner

FirstRanker.com
Firstranker's choice
www.FirstRanker.com www.FirstRanker.com

White matter of cerebrum

- Association fibres
  - Connects different area of same Cerebral hemisphere
- Commissural fibres
  - Connects same area of both Cerebral hemisphere
- Projection fibres
  - All Ascending & Descending tracts.
  - [One functional area to other functional area.]

Association fibres
- Short Association : aka Arcuate fasiculus
  - neibouring area.
- Long Association
  1. Superior longitudinal fasiculus.
  2. Fronto occipital fasiculus
  3. Inferior occipital fasiculus
  4. Uncinate fasiculus
  5. Cingulum.

(Limbic association fibres)

CR.



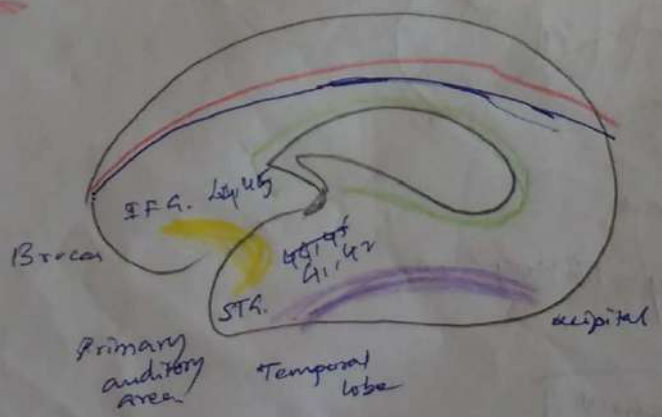

www.FirstRanker.com
Scanned by CamScanner

FirstRanker.com
Firstranker's choice
www.FirstRanker.com www.FirstRanker.com

matter of cerebral

Association fibres → Connects different areas of same Cerebral hemisphere

Commissural fibres → Connects same area of both Cerebral hemisphere

Projection fibres → All Ascending & Descending tracts.
[One functional area to other functional area.]

Association fibres
- Short Association : aka Arcuate fasiculus → neibouring area.
- Long Association
  1. Superior longitudinal fasiculus.
  2. Fronto occipital fasiculus
  3. Inferior occipital fasiculus
  4. Uncinate fasiculus
  5. Cingulum.

(Limbic association fibres)

CR.



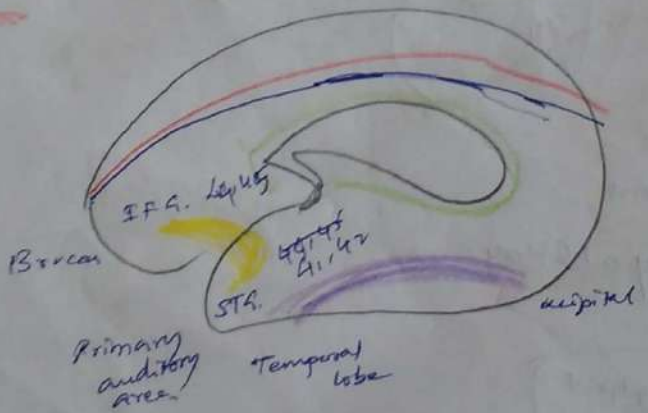

www.FirstRanker.com
Scanned by CamScanner

FirstRanker.com
Firstranker's choice
www.FirstRanker.com www.FirstRanker.com

Commisural fibres

1. Corpus collocum (Largest) → Rostrum, Trunk Body, Splenium
2. Ant. commissure.
3. Post. commissure.
4. Habenular "
5. Hippocampal "

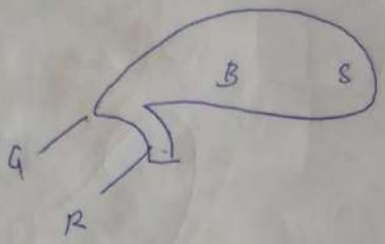

Connects Habenular nuclei

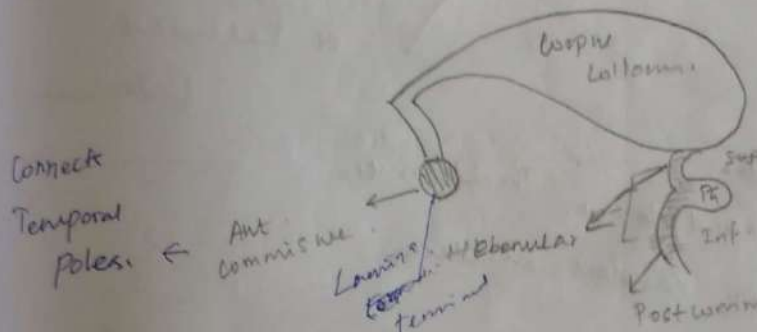

Connects sup. colliculus & Midbrain.

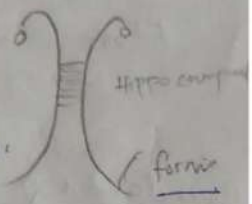

Limbic commisural fibres

Head of caudate nucleus

forceps minor.

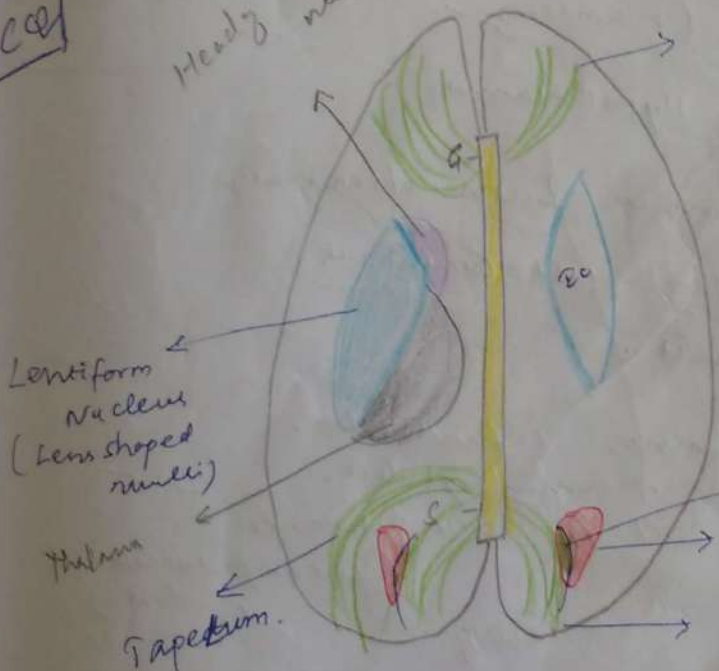

Lentiform Nucleus (Lens shaped nuclei)

Thalamus

Tapetum.

Bulb & post-horn.

Posterior horn & Lateral Ventricle

forceps major.

www.FirstRanker.com
Scanned by CamScanner

FirstRanker.com
Firstranker's choice
www.FirstRanker.com www.FirstRanker.com

Coronal section

MCQ

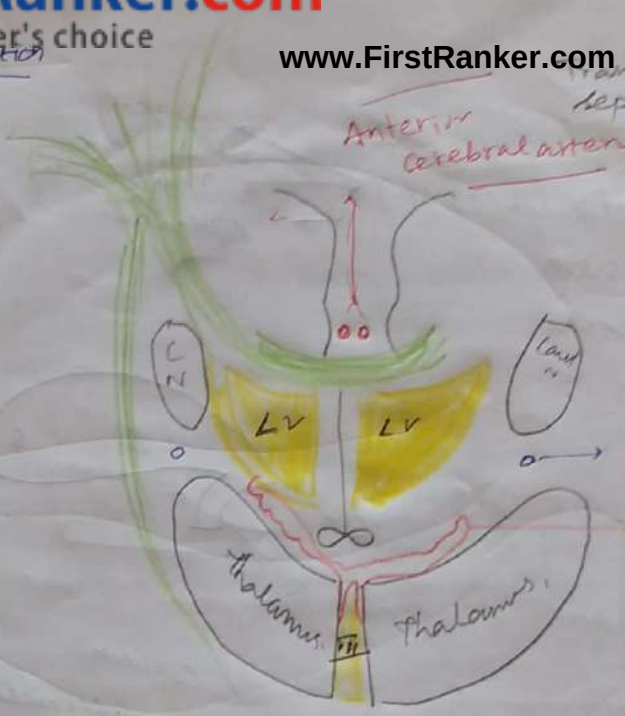

Boundaries of LV

Roof = Corpus callosum

M. wall : septum pellucidum

Floor : Fornix, choroid plexus, Thalamus, thalamostriate vein, caudate nucleus

No Lateral wall

Lateral Ventricle

Boundaries of III rd ventricle :-

No III rd Nerve in 3rd ventricle

Roof : choroid plexus (pia mater)

Lat. wall : Thalamus, Hypothalamus

Ant. wall :- Ant. commissure, Lamina terminalis

post. wall :- pineal gland. post. commissure.

Cerebral Aqueduct.

Floor :- optic chiasma, infundibulum, mammillary bodies, post. perforating substance (Interpeduncular fossa)

Contents

www.FirstRanker.com
Scanned by CamScanner

FirstRanker.com
Firstranker's choice
www.FirstRanker.com www.FirstRanker.com

Projection Fibres :-

1. Internal capsule.
2. Corona radiata.

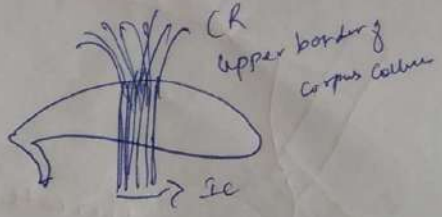

Internal capsule

Anterior Limb (A)

Genu (G)

posterior Limb. (P)

Retro Lentiform. (R)

Sub Lentiform. (S)

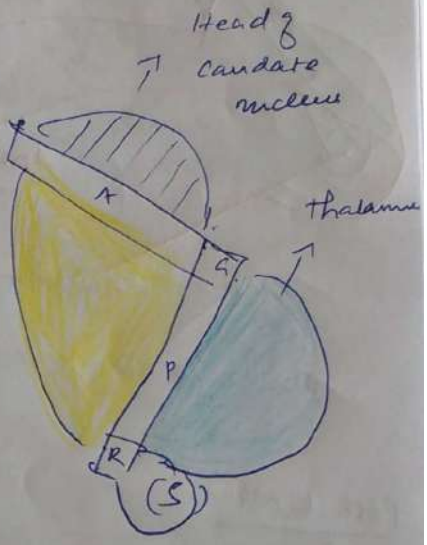

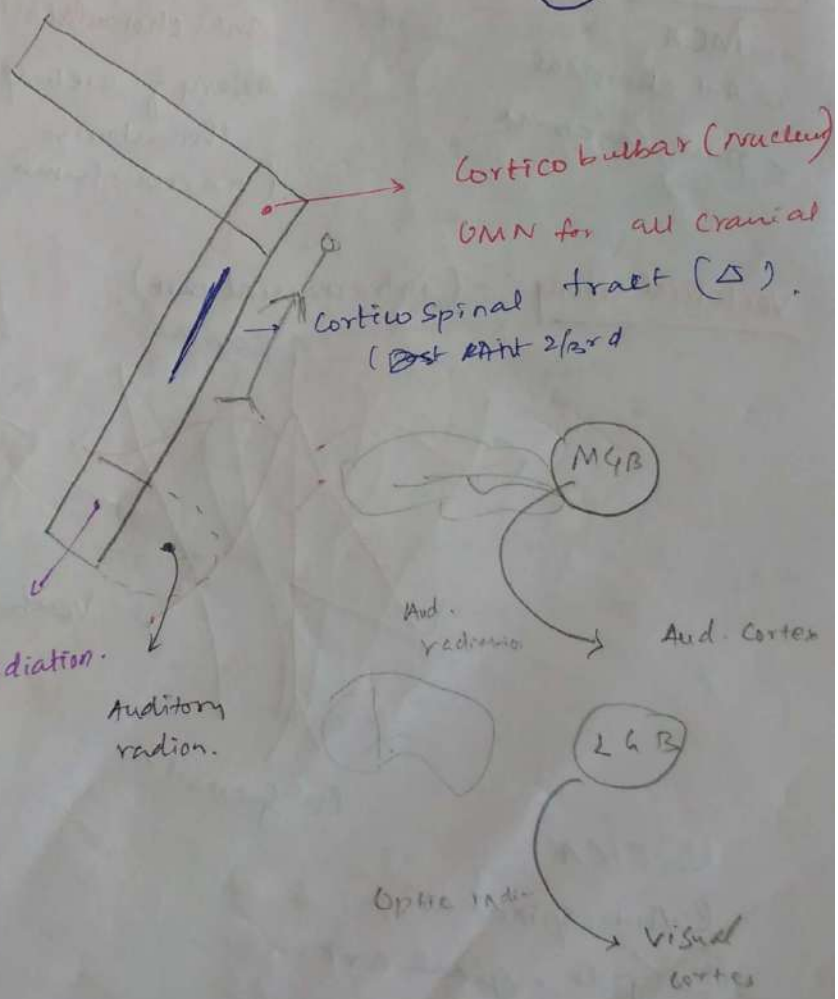

www.FirstRanker.com
Scanned by CamScanner

FirstRanker.com
Firstranker's choice
www.FirstRanker.com www.FirstRanker.com

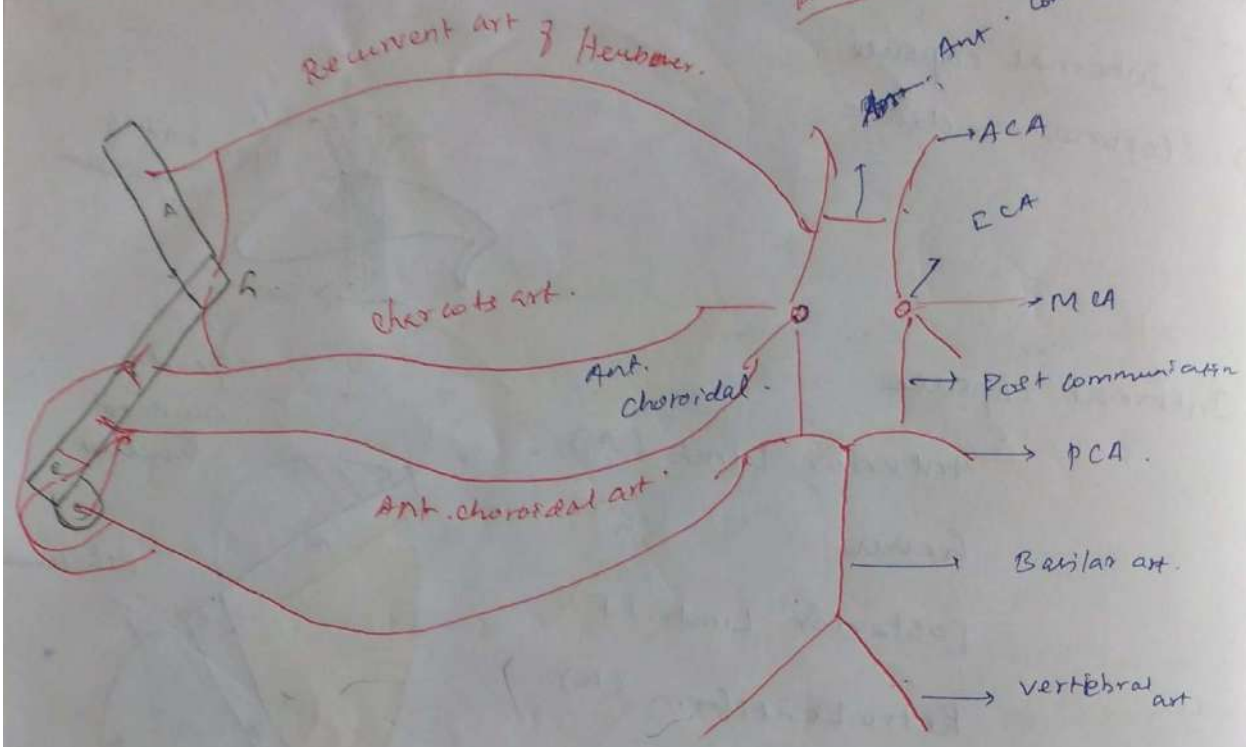

"Circle of willis"

Post. Limb
- MCA
- Ant. choroidal.
- Post. cerebral.

Ant. choroidal art
Artery of cerebral thrombosis (narrow lumen.

Charcots artery
(Lenticulate striate artery)
= artery of cerebral haemorrhage (intracerebral)

Vertebral artery :- (intracranial part).

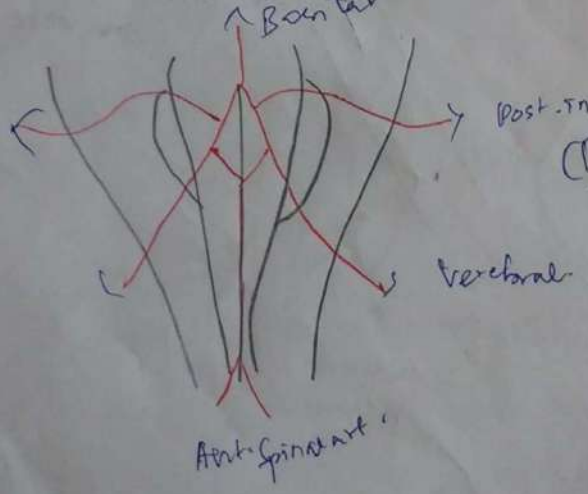

1. PICA
2. Ant. spinal art.
3. post. spinal art.
4. medullary br.
5. meningeal br.

www.FirstRanker.com
Scanned by CamScanner

FirstRanker.com
Firstranker's choice
www.FirstRanker.com www.FirstRanker.com

Basilar Artery :-



Labyrinthine artery.
(may arise from Basilar art)

Internal Carotid artery :-

Carotid siphon.

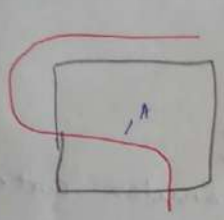

A. Intra cavernal part.

(1) Meningeal br. → wall of C.S.

(2) Sup & Inf. Hypophyseal art.

B. Supra cavernal part

First br. ← (1) Ophthalmic art.
(2) MCA.
(3) ACA.
(4) Ant. choroidal
(5) Post. communicating art.

ACA.

www.FirstRanker.com
Scanned by CamScanner

FirstRanker.com
Firstranker's choice
www.FirstRanker.com www.FirstRanker.com

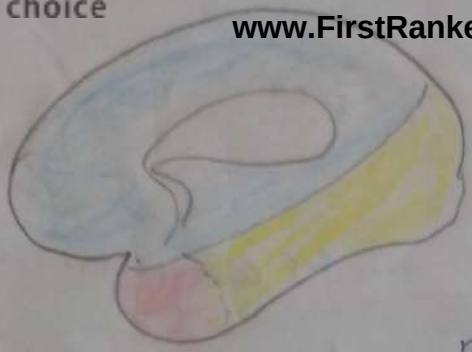

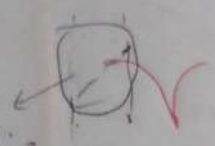

pterion.

Haemorrhages.

- ✓ Extradural → Ant division of Middle Meningeal art.
- ✓ Sub dural. → Bridging vein.
- ✓ Sub arachanoid. → Rupture of Berry aneurysm.
- ✓ Intracerebral. → Charcots artery

Cerebral Cortex Histology

- Granular cortex
  - granul
  - ↓
  - S Cortex
- Agranular cortex (motor)
  - pyramidal (motor)
  - ↓
  - M - cortex.

Outer

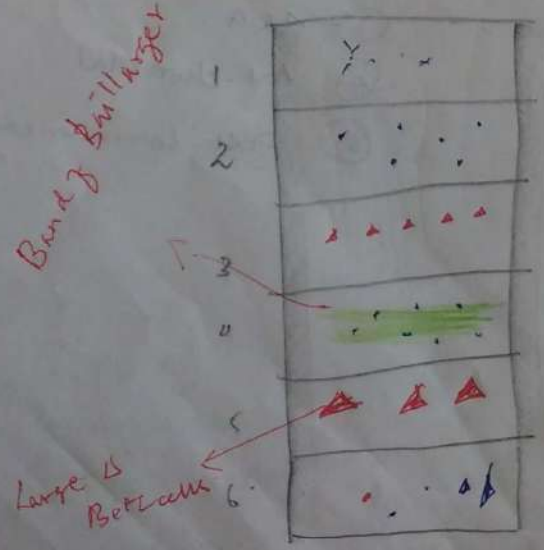

Plexiform Layer (supporting cells)
outer Granular.
outer pyramidal.
Inner Granular.
Inner pyramidal.
Multiform Layer.

inside

www.FirstRanker.com
Scanned by CamScanner

FirstRanker.com
Firstranker's choice
www.FirstRanker.com www.FirstRanker.com

MCQ

→ Horz running Myelin Bevone

→ visual Cortex so reffered as "Striate Cortex"



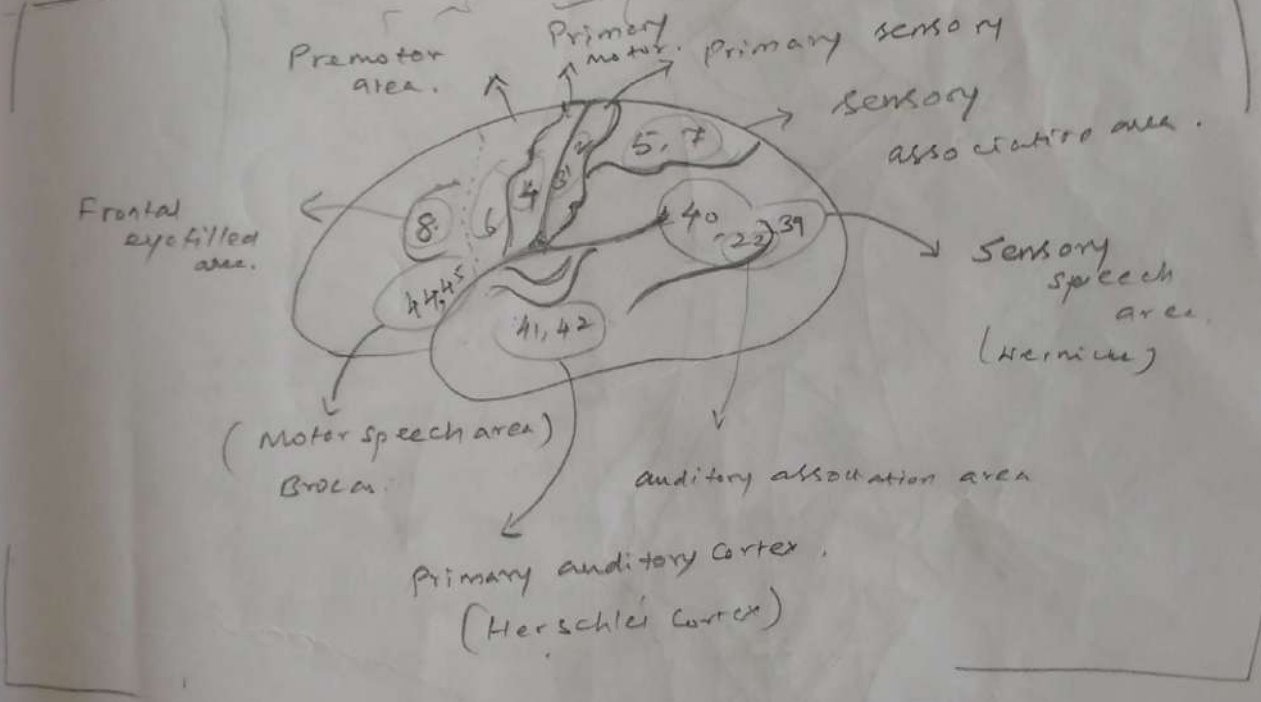



www.FirstRanker.com
Scanned by CamScanner

FirstRanker.com
Firstranker's choice
www.FirstRanker.com www.FirstRanker.com

DEC 4
2016

THORAX:-

Thoracic wall:-

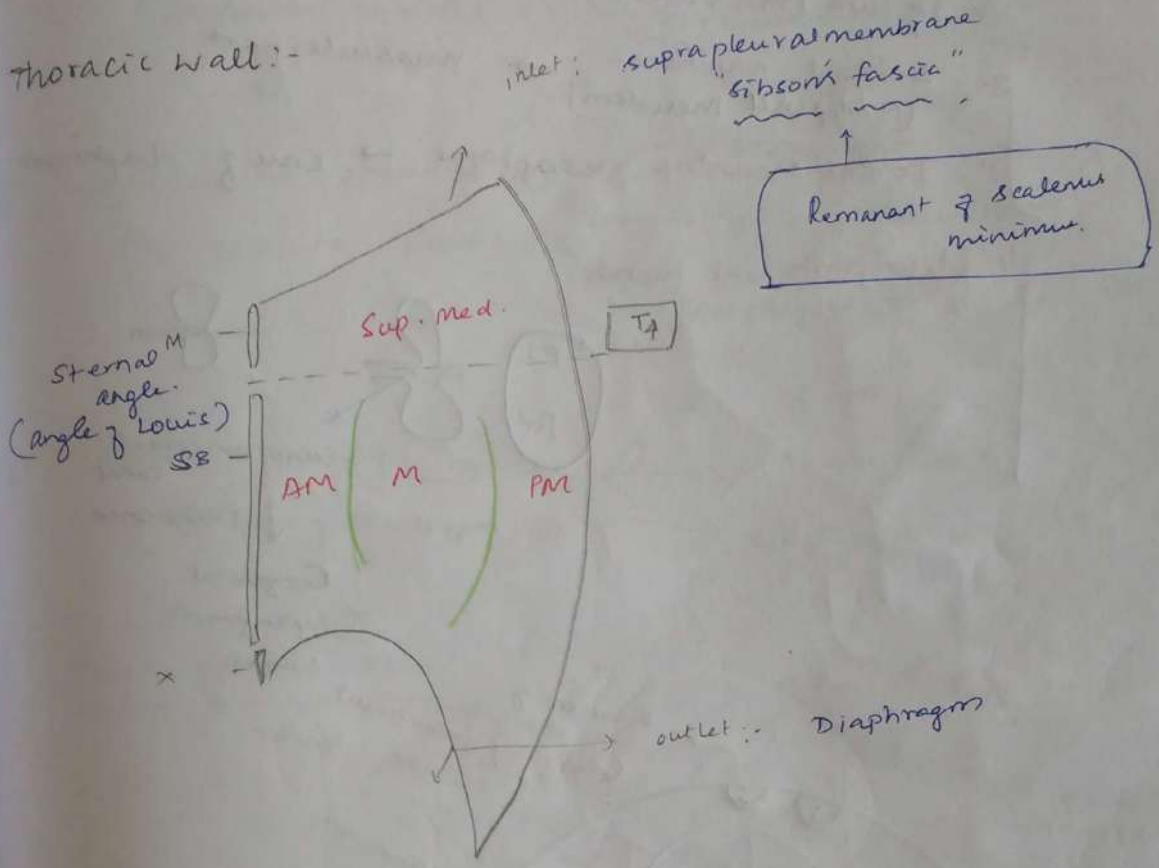

* Sternal angle:-

1. Bifurcation of trachea. (Cadaveric)
2. Beginning & end of arch of aorta.
3. 2nd costal cartilage
4. Arch of azygous vein.
5. Thoracic duct shifts to (L) side.
6. Superficial Cardiac plexus.
7. Level for Apex of fibrous pericardium.
8. Level for Attachment of Sup. sterno pericardial Ligament.
9. Junction of superior & Inferior mediastinum.

www.FirstRanker.com
Scanned by CamScanner

FirstRanker.com
Firstranker's choice
www.FirstRanker.com www.FirstRanker.com

Diaphragm :-

Development :-

1. Septum transversum → Central tendon.
2. Cervical myotome (Body wall mesoderm) → muscular part
3. Dorsal mesentry of oesophagus → Crus of diaphragm
4. pleuroperitoneal memb.

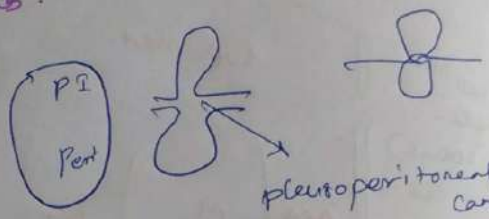

↓ Persistence

Congenital Diaphragmatic Hernia

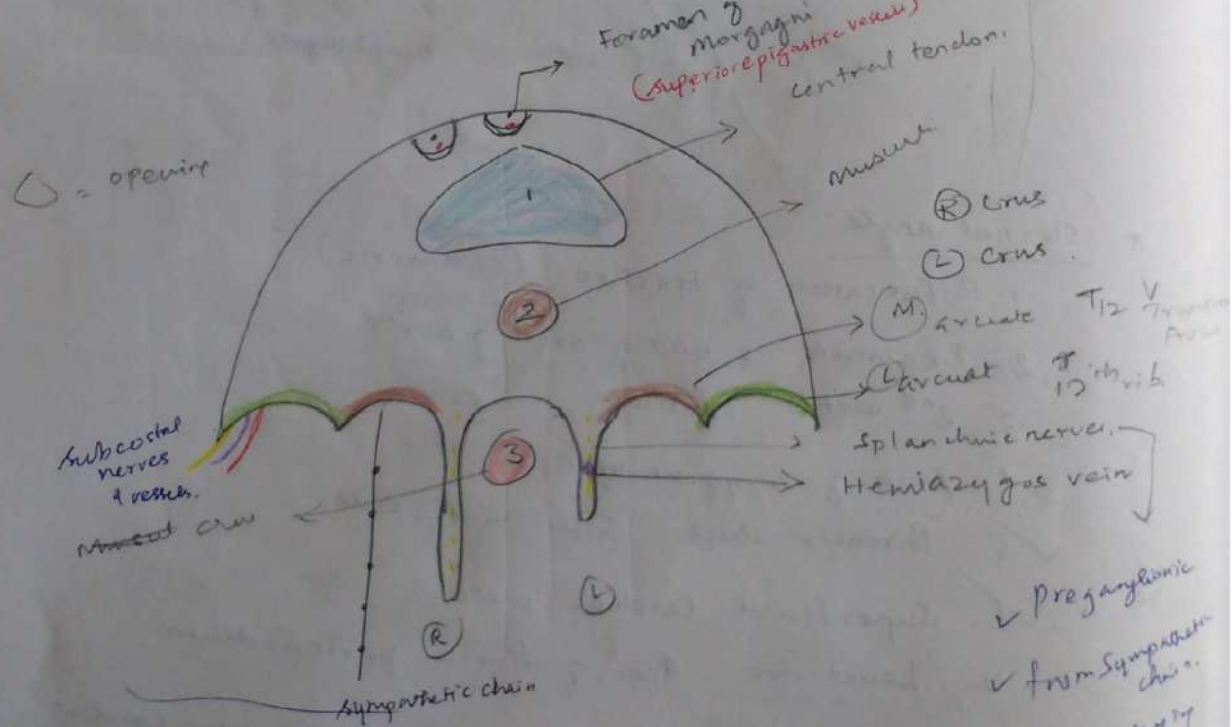

↙ Preganglionic
↙ from Sympathetic chain
without relaying in sympathetic chain

www.FirstRanker.com
Scanned by CamScanner

FirstRanker.com
Firstranker's choice
www.FirstRanker.com www.FirstRanker.com

Major openings:

1) Venacaval opening [In central tendon]
- IVC
- (R) phrenic nerve IVC.



2) Oesophageal opening (T_{10}) (in muscular part)
- Oesophagus.
- (R) & (L) vagus nerve.
- Oesophageal br of Left Gastric Artery.

3) Aortic opening (T_{12}) (B/w crus of Diaphragm)
- Aorta.
- Thoracic Duct.
- Azygous vein.

Inter costal Spaces:-

Inter costal muscles:-

(a) → (3) Innermost
(b) → (2) internal
(c) → (1) External

(1)
(2)
(3)
- Subcostalis. (a)
- Intercostalis intima (b)
- Stemocostalis (c) (Transverse Thoracis)

MCQ

(1) Downwards, forwards medially
(2) Downwards, backwards laterally
(3) " " "

* Neurovascular bundle is present b/w internal innermost intercostal muscles.

V A N except 1st inter Inter costal space M A V

www.FirstRanker.com
Scanned by CamScanner

FirstRanker.com
Firstranker's choice
www.FirstRanker.com www.FirstRanker.com

Intercostal nerves :-

T_1 – Brachial plexus.
T_2 – intercosto brachial nerves.

T_3, T_4, T_5, T_6 ⇒ Typical intercostal nerve supply Intercostal spaces. and nothing else

T_7, T_8, T_9, T_{10}, T_{11} → thoracoabdominal nerves.

T_{12} – subcostal nerve / skin in gluteal region.

Intercostal arteries :-

Post. Intercostal artery → Internal thoracic artery

AICA = Anterior intercostal artery

Branch of ITA from 1st to 5th ICS

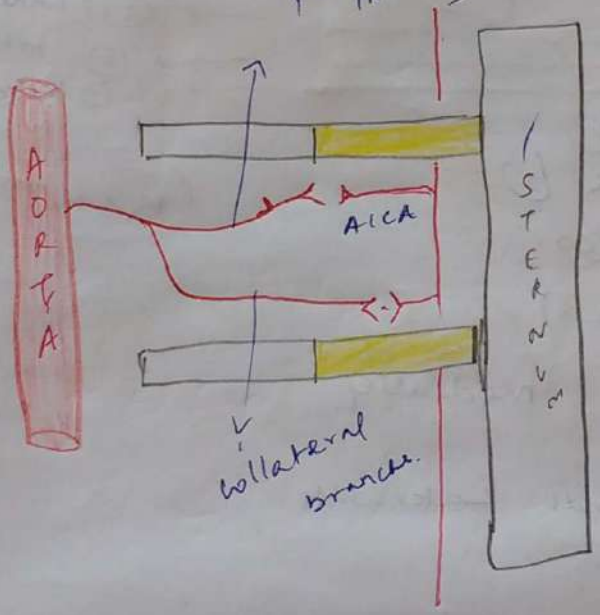

www.FirstRanker.com
Scanned by CamScanner

FirstRanker.com
Firstranker's choice
www.FirstRanker.com www.FirstRanker.com

Internal thoracic artery :-

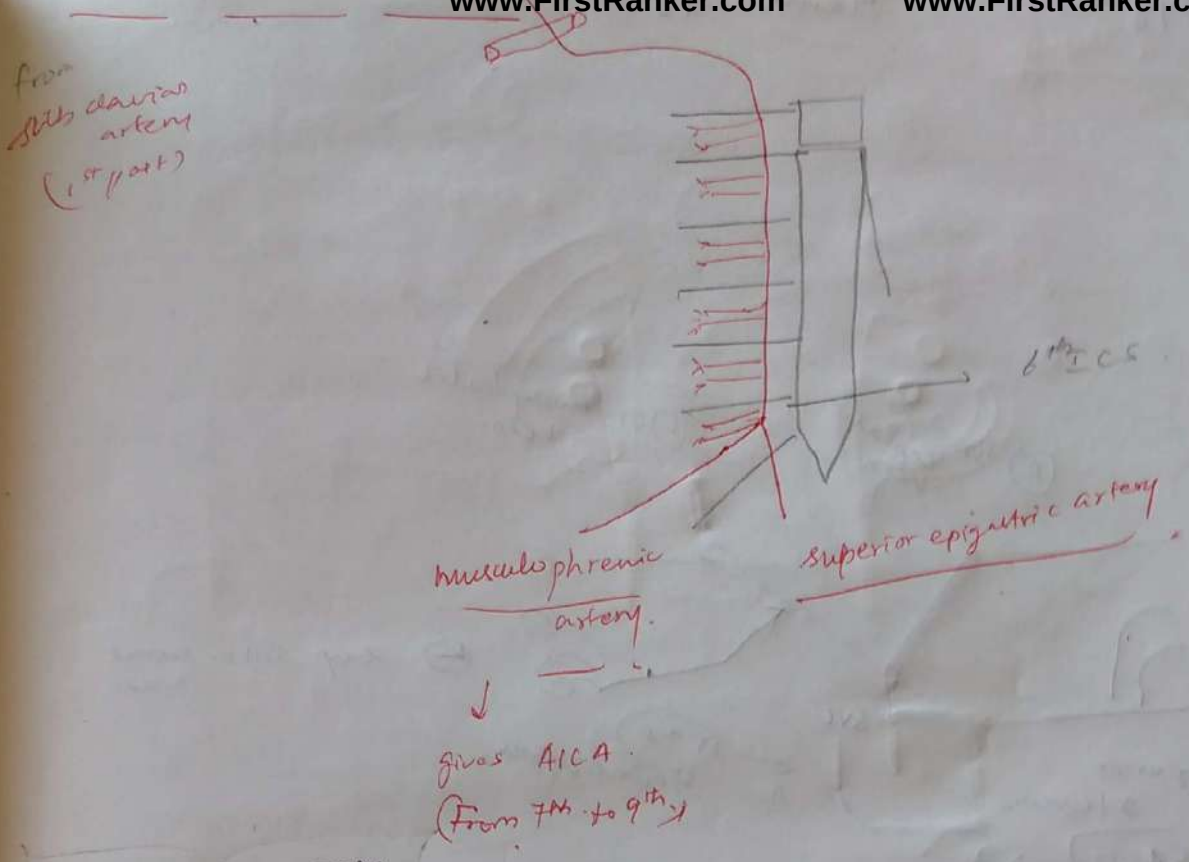

Branches of ITA :-

1. Superior Epigastric a.] Terminal branches.
2. Musculophrenic
3. AICA
4. mediastinal branch. → Remains of thymus.
5. Pericardiophrenic art → supplies → fibrous pericardium
   - Diaphragm
6. ~~Inferior~~ :- Perforating mamary br.
   (Supplying 2nd to 6th I/c space)

www.FirstRanker.com
Scanned by CamScanner

FirstRanker.com
Firstranker's choice
www.FirstRanker.com www.FirstRanker.com

Azygous & Hemiazygous veins.

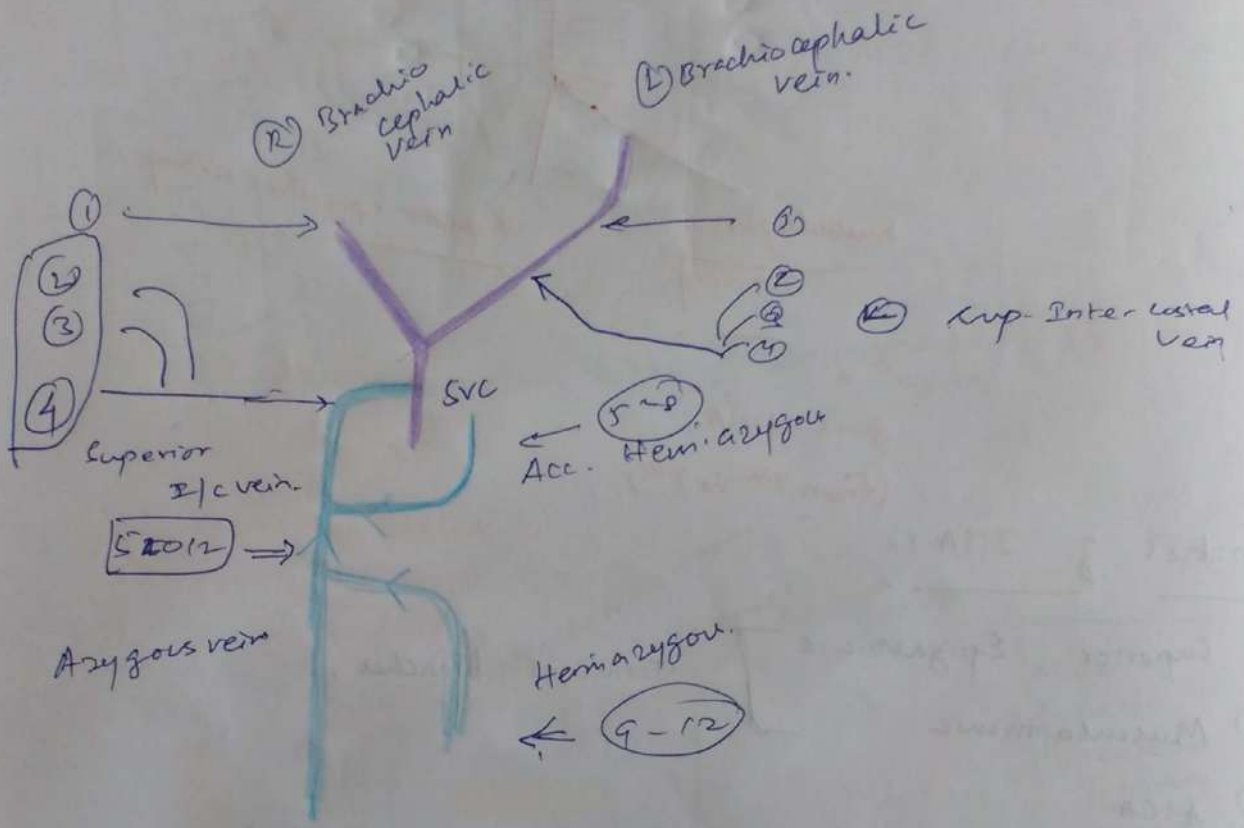

* (R) Sup. I/c vein tributary of Azygous vein.

* (L) Sup. I/c vein tributary of

(L) Brachiocephalic vein.

www.FirstRanker.com
Scanned by CamScanner

FirstRanker.com
Firstranker's choice
www.FirstRanker.com www.FirstRanker.com

Formative tributaries :-

☆ Azygous vein

a) ® Subcostal vein
b) ® Lumbar azygous vein.
c) ® Lumbar Ascending vein.

☆ Hemi azygous vein.

a.) (L) Sub costal
b.) (L) Lumbar azygous
c.) (L) Lumbar Ascending.

☆ ® Bronchial vein is the last tributry of azygous vein.

Pleura.

Parietal pleura.
1. Cervical pleura
2. Costal pleura
3. Diaphragmatic pleura
4. Mediastinal pleura.

Visceral pleura.
↓
Pulmonary Septae
↓
Broncho Pulmonary Segments

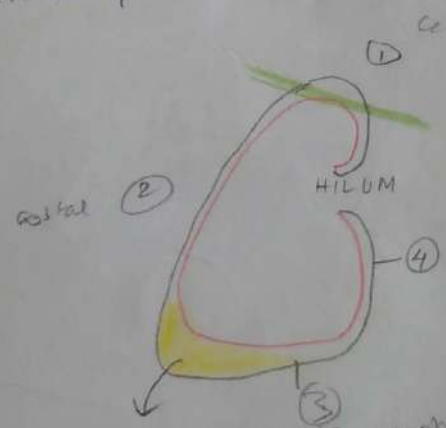

Costo Diaphragmatic recess.

Diaphramatic (most dependent site of pleural cavity).
pleural tap 9th ICS mid axillary line.

www.FirstRanker.com
Scanned by CamScanner

FirstRanker.com
Firstranker's choice
www.FirstRanker.com www.FirstRanker.com

Root of lung.

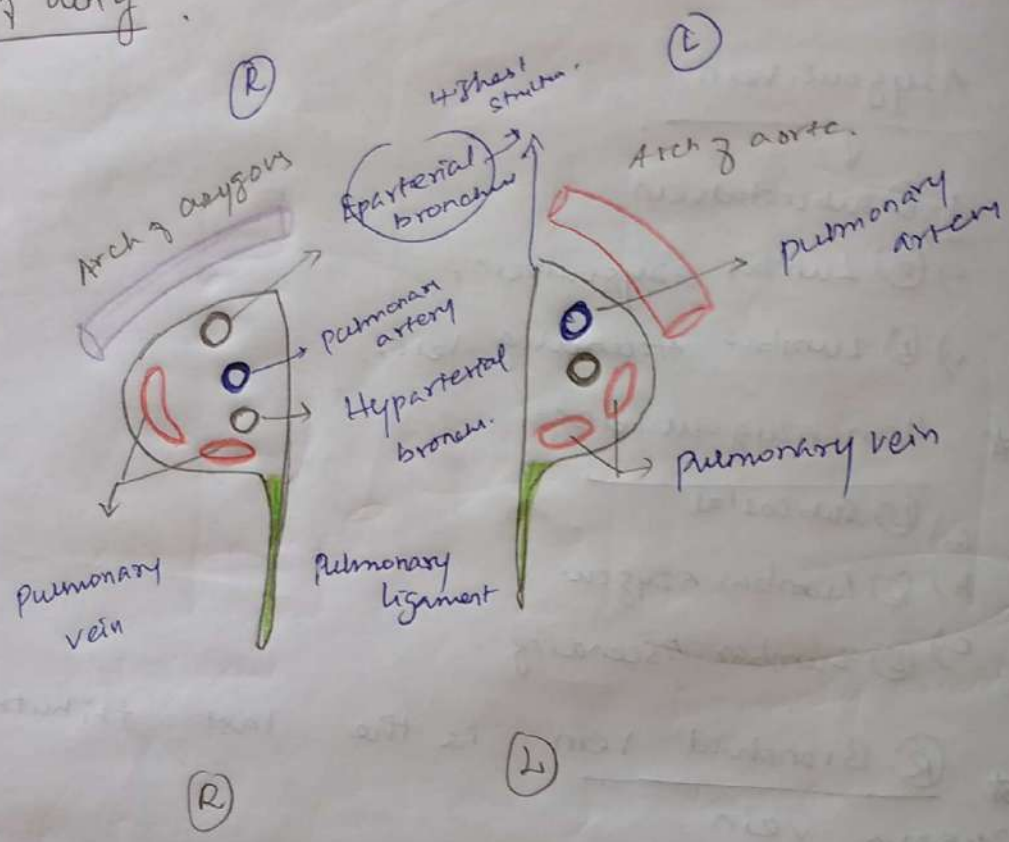

Bronchial artery

Left Lung → two bronchial arteries (Branch of aorta).

Right lung → one br. artery (R) 3rd posterior intercostal arteries.

* Bronchial arteries supplies Trachobronchial tree till Respiratory Bronchioles.

www.FirstRanker.com
Scanned by CamScanner

FirstRanker.com
Firstranker's choice
www.FirstRanker.com www.FirstRanker.com

Broncho pulmonary Segments

Features:-

1. Area of lung created by tertiary bronchus / Segmental bronchus / IIIrd generation bronchus.
2. Pyramidal in shape; Apex is towards lung (Hilum) (principle for postural Drainage)
3. Surgically resectable. (Bcoz they are divided by visceral pleura)
4. Broncho pulmary segments :- No vein. pulmonary veins are inter segmental not intra segmental.

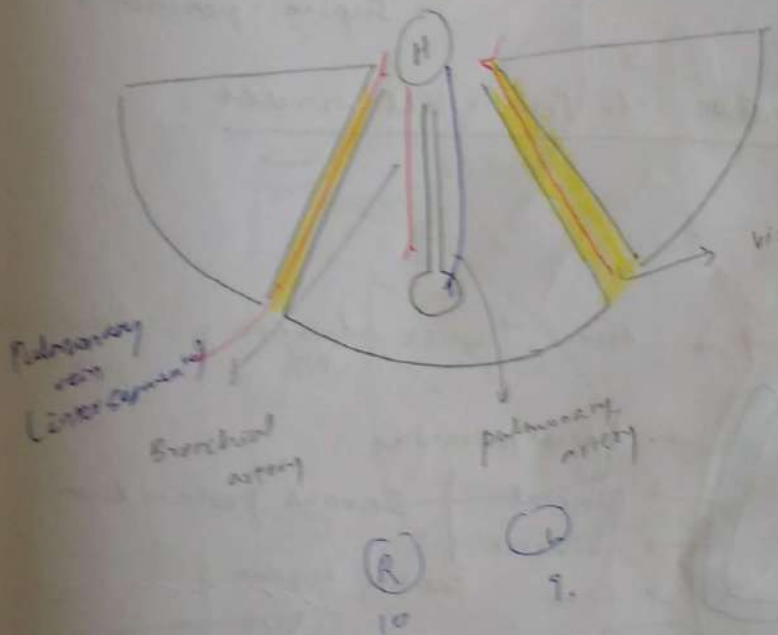

R 10 L 9.

www.FirstRanker.com
Scanned by CamScanner

FirstRanker.com
Firstranker's choice

(R) Lung (10)

www.FirstRanker.com

(L) Lung (9)

www.FirstRanker.com

Upper lobe
- A - Apical
- P - Posterior
- A - Anterior.

Middle lobe
- L - Lateral
- M - medial.

Lower lobe
- A - Apical Basal. (Superior)
- P - posterior Basal.
- A - Anterior Basal
- L - Lateral Basal
- M - Medial Basal

Upper lobe
- A - Apical
- P - posterior
- A - Anterior.
- S - Superior
- I - Inferior.

A + P may form Apicoposterior

S + I : Lingular Bps.

Lower lobe
- A - Apical
- P - posterior
- A - Anterior
- L - Lateral
- M - medial

Basal

Commonly Absent.

★ (R) Posterior Basal => most dependent BPS. in Erect posture.

★ (R) Apical Basal => most dependent BPs in Supine position.

Pericardium & Pericardial sinuses

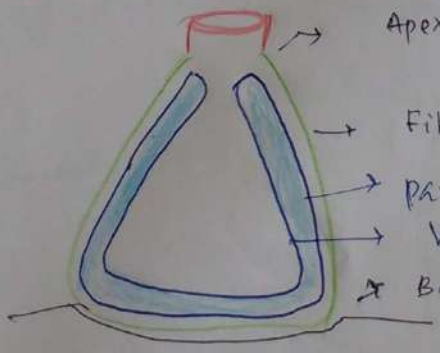

Apex : Tunica adventitia of Great vessels

Fibrous pericardium.

Parietal | Serous pericardium.
Visceral |

★ Base : central tendon of Diaphragm.

www.FirstRanker.com

Scanned by CamScanner

FirstRanker.com
Firstranker's choice
www.FirstRanker.com www.FirstRanker.com

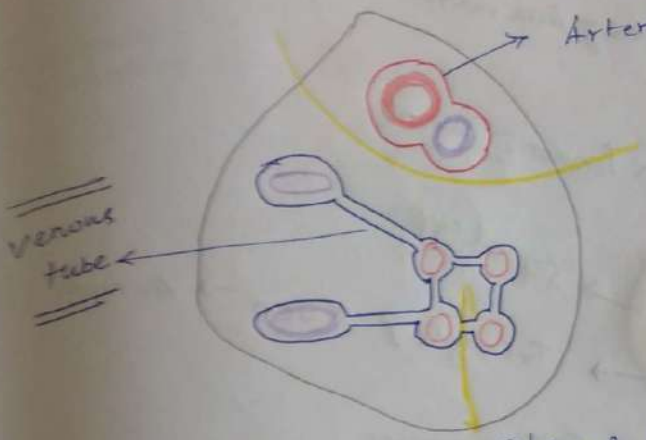

Transverse Sinus
↓
Can be used to ligate great vessels. (Asc. Aorta & PT) during Cardiac Sx

Oblique sinus.
↓
Additional Dead space behind (L) atrium for its Expansion in ↑VR.

HEART

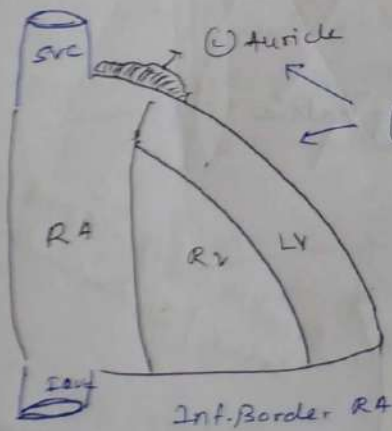

(L) auricle
LV + L auricle
(L) Border
(R) Border RA
Inf. Border RA+RV
Apex :- (L) 5th intercostal space. Just lateral to mid clavicular line
Base
½ RA + ½ LA

www.FirstRanker.com
Scanned by CamScanner

FirstRanker.com
Firstranker's choice
www.FirstRanker.com www.FirstRanker.com

Right atrium :-

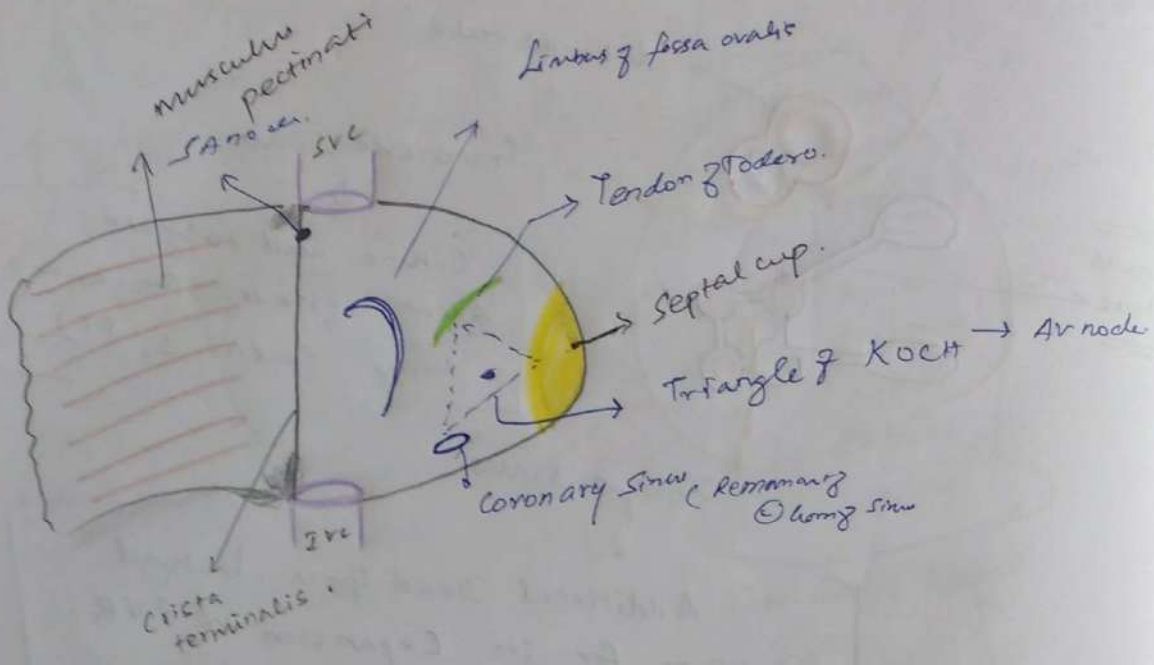

* Musculus Pectinati
  - it reduced the turbulence b/w
  - Blood of SVC & IVC
  - it guides the blood towards AV valve.
* SVC - Devoid of valve.

(R) ventricle :-

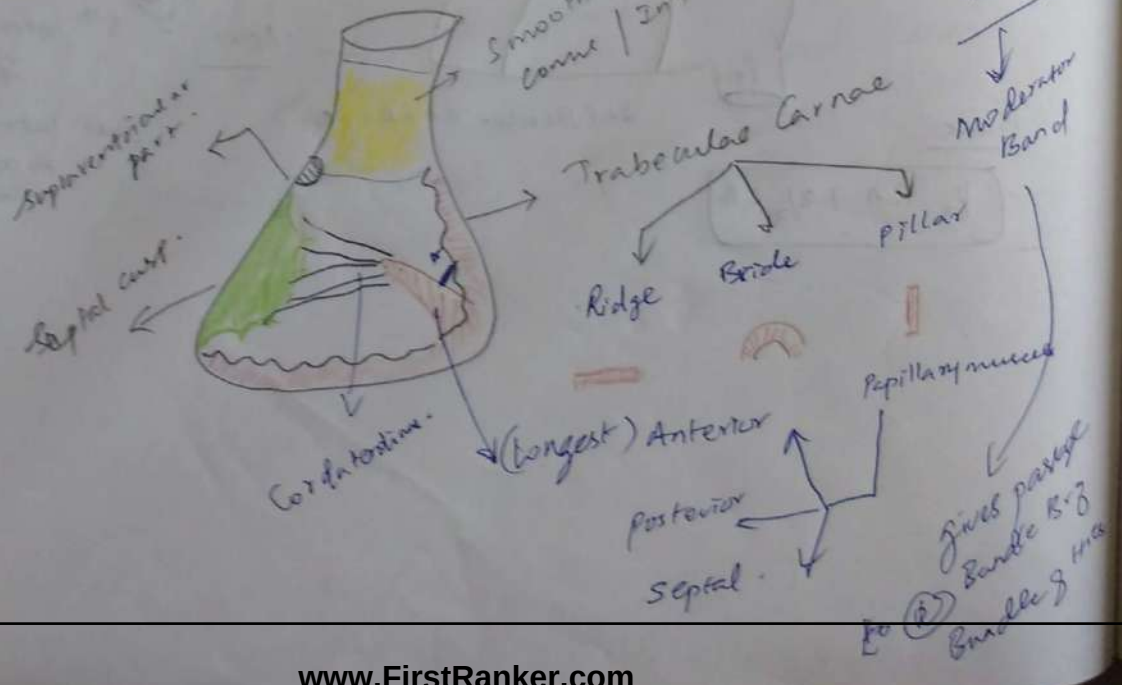

www.FirstRanker.com
Scanned by CamScanner

FirstRanker.com
Firstranker's choice
www.FirstRanker.com www.FirstRanker.com

CORONARY CIRCULATION :-

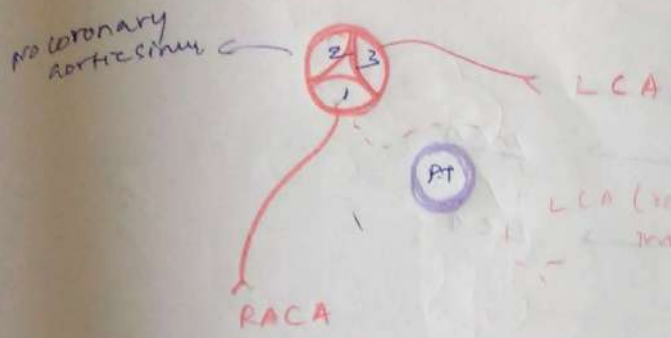

1. Ant. Aortic sinus
2. (R) Post. Aortic sinus.
3. (L) Post. Aortic sinus

One of the causes Sudden Cardiac Death.

SA node

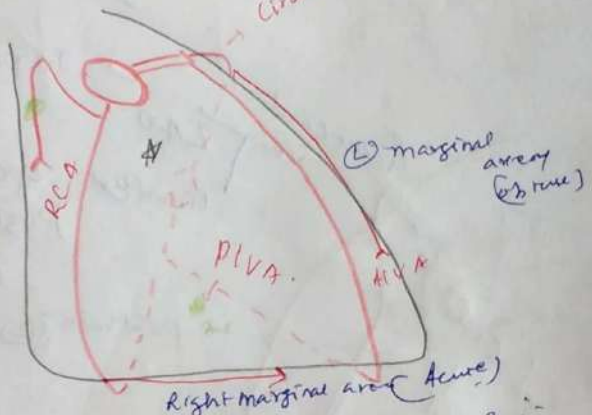

(Posterior Interventricular Artery)

Anteri
(L) Anterior descendry

AV node
Septal branch of PIVA

* Right Cardiac Dominance :-
PIVA br of RCA 65% population.

RCA infundibulum

* Left Cardiac Dominence :-
PIVA br. circumflex 25% population.

* Co Dominence :-
  * Post. Interventricular groove shared by both RCA & LCA.
  * 10% population.

Annulus of Vieussens

Pregnant.

MCQ

- Optic nerve
- Sciatic
- SA node.

www.FirstRanker.com
Scanned by CamScanner

FirstRanker.com
Firstranker's choice
www.FirstRanker.com www.FirstRanker.com

Blood Supply to Conducting System :- MCQ

SA node, AV node, BOH.

↑

RCA.

R Bundle Br ⟶ LCA

L Bundle Br ⟶ LCA.

Coronary Sinus :-

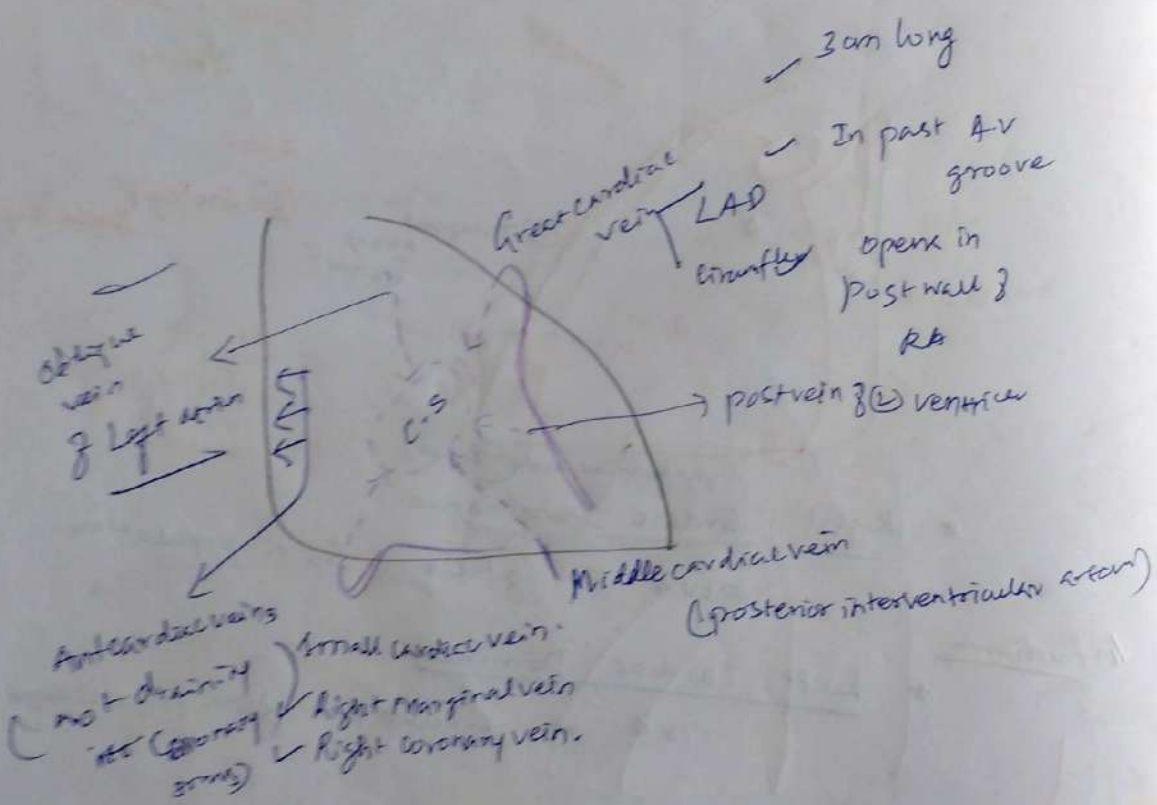

www.FirstRanker.com
Scanned by CamScanner

FirstRanker.com
Firstranker's choice
www.FirstRanker.com www.FirstRanker.com

Lower Limb

Fascia Lata

Intermuscular septum

Iliotibial Band

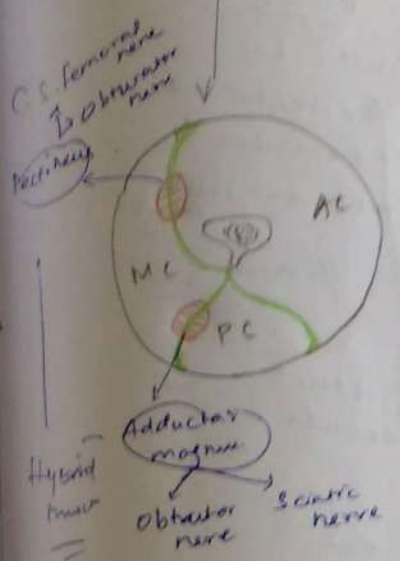

(>2 nerve supply
perform same function)

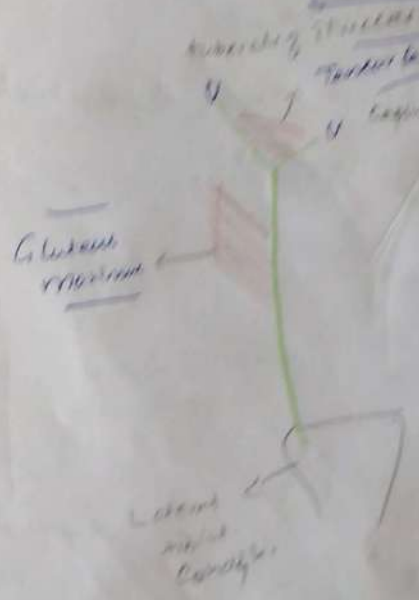

Contracture of Iliotibial band

Hip joint → FABER

Knee joint → Flexion, Ext. rotation of tibia

Post. Subluxation

Anterior Compartment :-

Nerve → Femoral nerve → $L_2 L_3 L_4$

Dorsal Division

Lateral Circumflex femoral artery

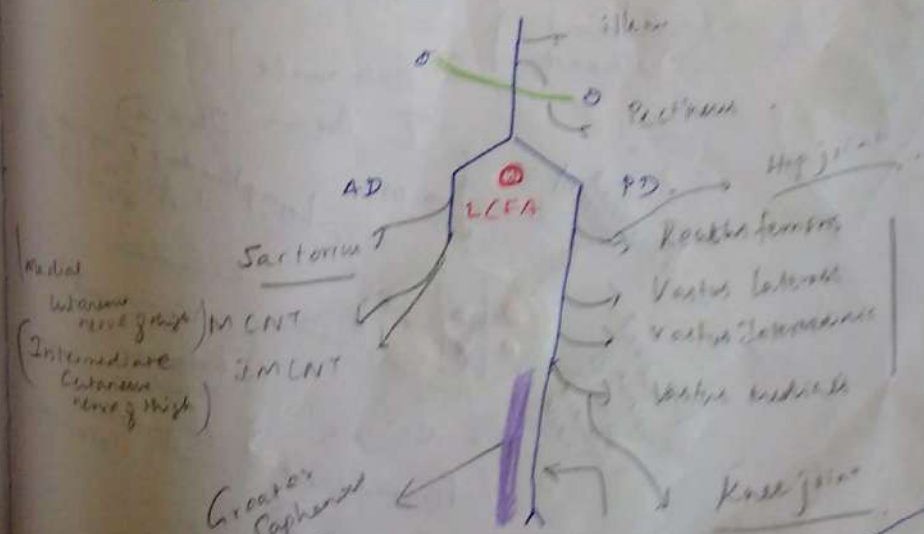

www.FirstRanker.com
Scanned by CamScanner

FirstRanker.com
Firstranker's choice
www.FirstRanker.com www.FirstRanker.com

femoral triangle :-

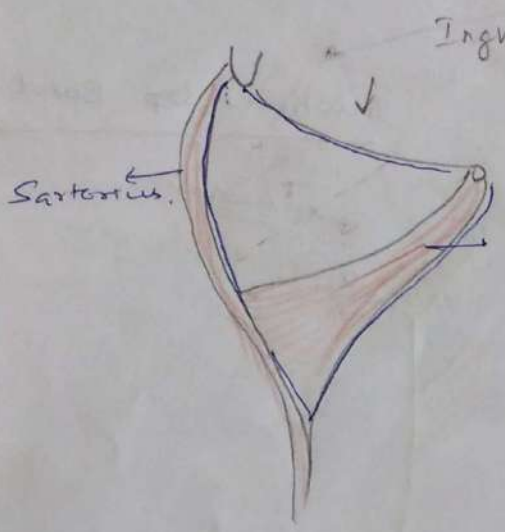

Floor

Med - Lat

1. Adductor longus
2. pectineus.
3. tendon psoas major.
4. Iliacus.

Roof

Superficial epigastric Vessels -

Superficial circumflex Iliac vessels

Superficial ext. pudental vessels.

Superficial Inguinal Lymphnodes.

Fascia lata.

Superficial fascia.

Skin

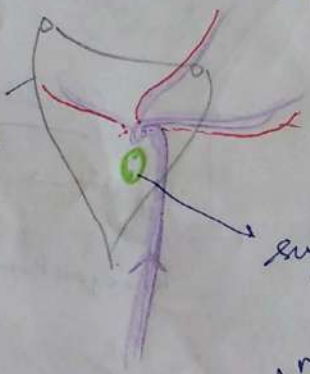

Contents :-

femoral nerve.

Lateral cutaneous nerve of thigh

femoral Sheath → Ant wall (Fascia transversalis)

post wall.

& fascia Iliaca

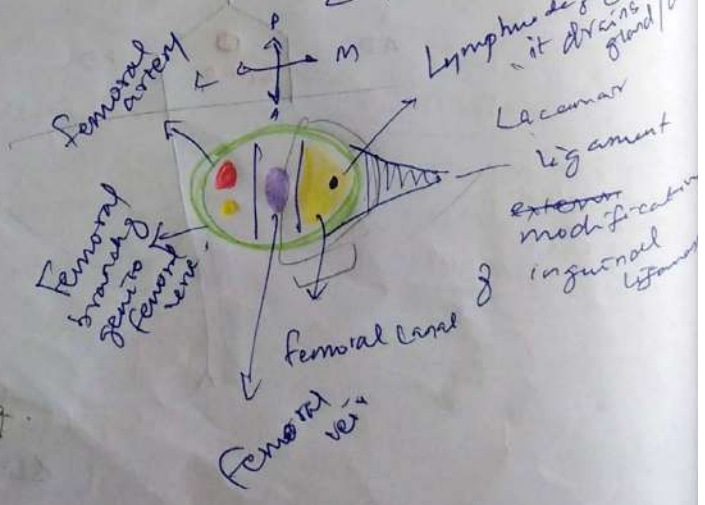

www.FirstRanker.com
Scanned by CamScanner

FirstRanker.com
Firstranker's choice
www.FirstRanker.com www.FirstRanker.com

→ most superior Deep inguinal lymph node.
→ most inferior ext. Illac lymph node.

→ most sup Deep inguinal lymphnode
→ most Inf. External Illac Lymphnode

Cremastric reflex :-

Afferent (i) | 1. Ilioinguinal nerve
2. Femoral branch of genitofemoral nerve.

Efferent 1. Genital branch of genitofemoral nerve.

Adductor canal | Sub sartorial canal | Hunter's canal :-

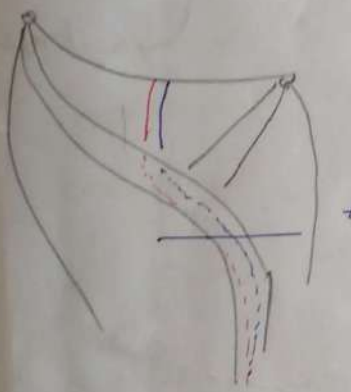

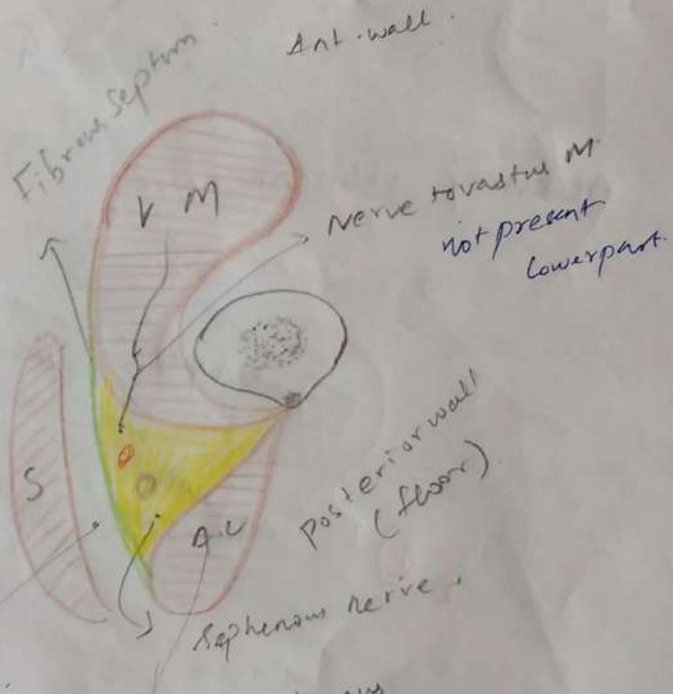

Contents :-

- ✓ femoral vessels.
- ✓ Nerve to vastus medialis.
- ✓ Saphenous nerve.
- ✓ Deep lymph vessels.
- ✓ Descending genicular artery.
- ✓ Two divisions of Obturator Nerve.

www.FirstRanker.com
Scanned by CamScanner

FirstRanker.com
Firstranker's choice
www.FirstRanker.com www.FirstRanker.com

Medial compartment (Adductor)

muscles GOA[3]

G - Gracilis

O — obturator Externus.

A - Adductor Longus.

A - Adductor Brevis

A - Add. Magnus.

Nerve

Obturator nerve (Ventral div.) ($L_2 L_3 L_4$)

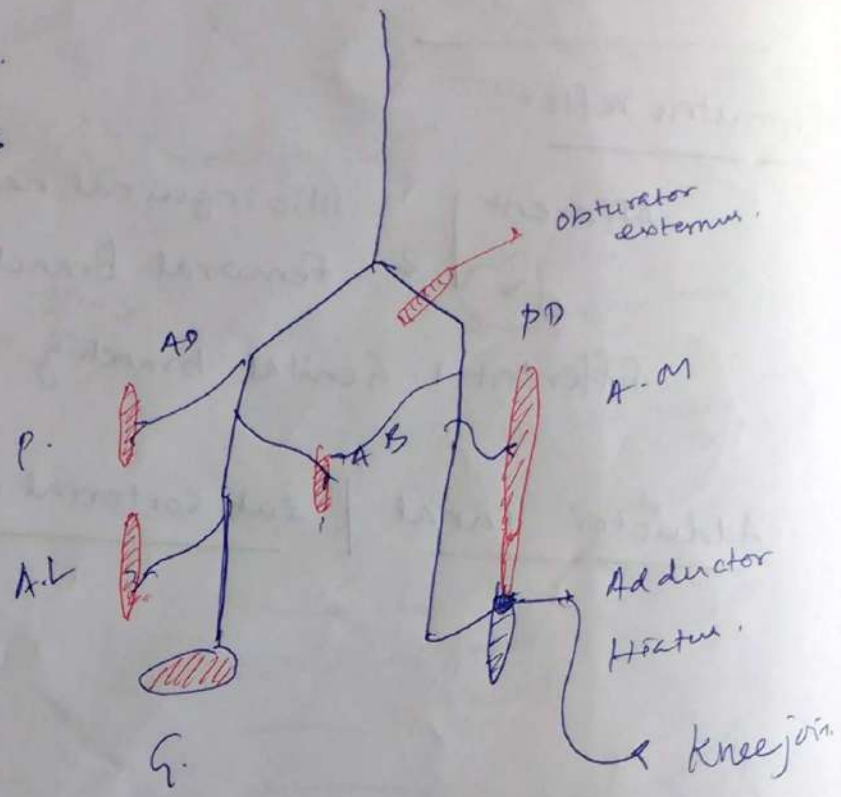

Accessory obturator nerve

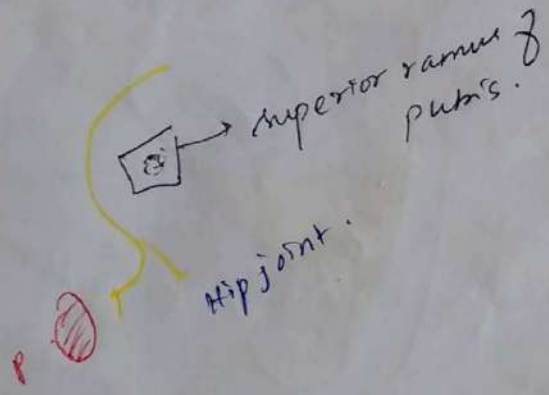

www.FirstRanker.com
Scanned by CamScanner

FirstRanker.com
Firstranker's choice

Gluteal region

www.FirstRanker.com www.FirstRanker.com

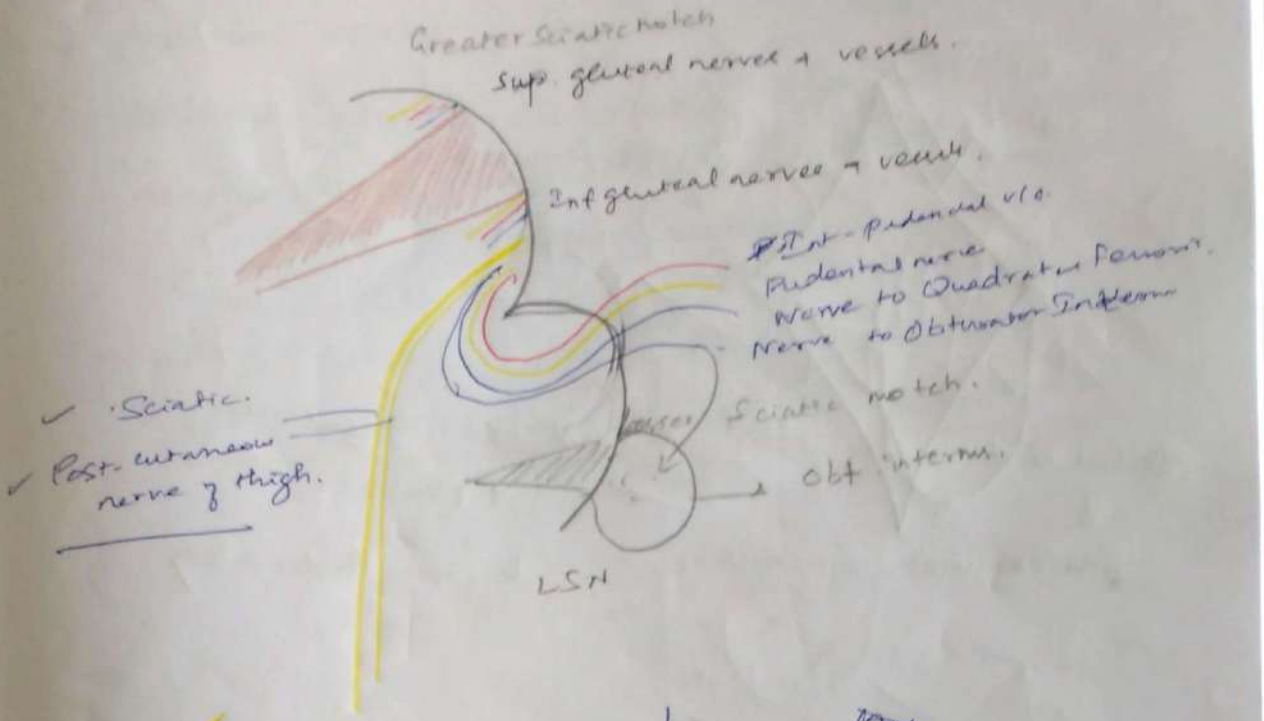

Gemellus Superior.
Obturator internus
Gemellus Inferior.
Quadratus femoris
N/v to
N/v to

Sciatic nerve

Hamstrings

Muscles

1.) Semitendinosus.

2.) Semimembranosus.

3.) Biceps femoris → Longhead
→ short head.

4.) Adductor magnus.



True hamstrings.

Modified Hamstrings.

www.FirstRanker.com
Scanned by CamScanner

FirstRanker.com
Firstranker's choice
www.FirstRanker.com www.FirstRanker.com

Popliteal fossa

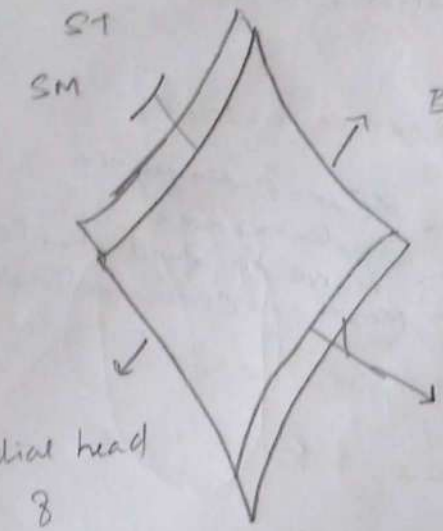

Popliteal sulcus of femur.

Capsule of Knee joint.

popliteus muscle & Otic capsule.

Locking of knee → During terminal 30° extension at knee.
medial rotation of femur on Tibia. (Vise versa)

muscle :- Vastus medialis.

Unlocking of knee → Lateral rotation of femur on Tibia.
to initiate flexion at knee.

muscle - popliteus.

www.FirstRanker.com
Scanned by CamScanner

FirstRanker.com
Firstranker's choice
www.FirstRanker.com www.FirstRanker.com

Contents (Deep to superficial)

→ Popliteal artery 2 branches. ✓
→ Popliteal vein 2 tributries.
→ Sciatic nerve — Tibial nerve. ✓
Common peroneal nerve

Posterior femoral cutaneous nerve.
Genicular branch of posterior division of obturator nerve.

NCQ Popliteal artery Deep seated Structure not present against Bony prominence ✓

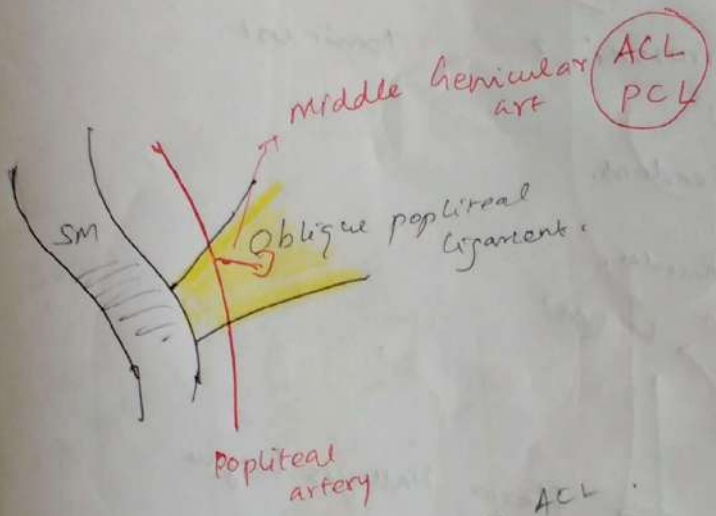

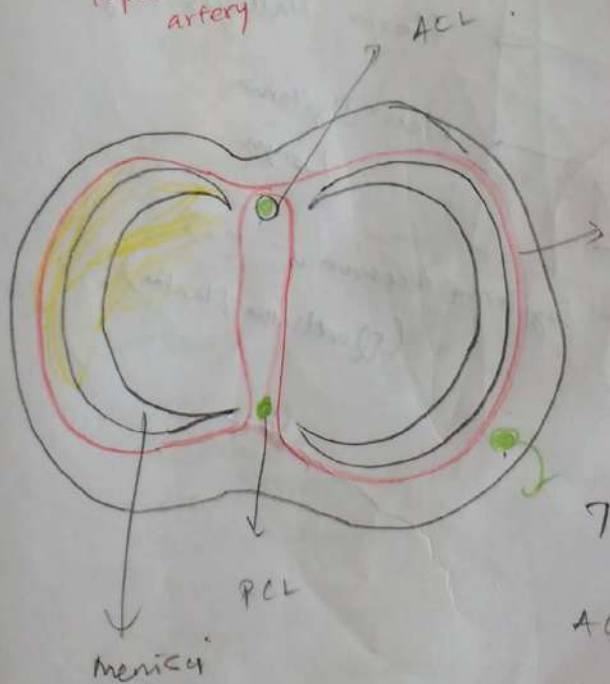

Tendon of popliteus.
ACL & PCL

www.FirstRanker.com
Scanned by CamScanner

FirstRanker.com
Firstranker's choice

Foot

www.FirstRanker.com www.FirstRanker.com

Sole of foot

(4 Layers)

Tibial nerve



Dominant nerve.

(I)

Adductors & interossei

Dominant

(II) Layer — 2 tendons, 2 muscles.

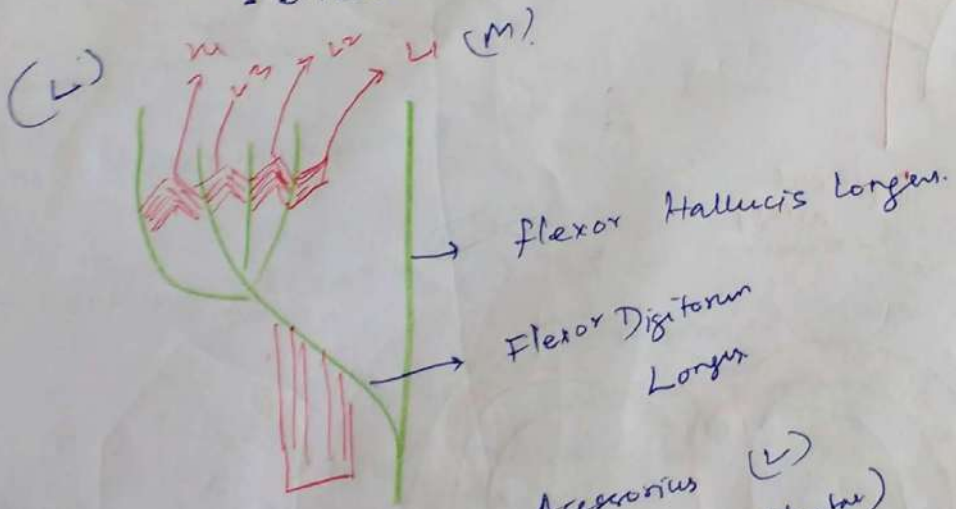

www.FirstRanker.com
Scanned by CamScanner

FirstRanker.com
Firstranker's choice
www.FirstRanker.com www.FirstRanker.com



IV Layer :- Layer of interossei { 3 plantar (unipinnate) (L) ; 4 Dorsal (Bipinnate) }

Arches of foot :-

Bones of Medial Longitudinal arch.

Bones of Lateral Longitudinal arch.

Features	MLA	LLA
① Summit (key stone)	Talus	Calcaneus
② Joint	Talocalcaneo navicular joint (Ball & Socket)	
③ Ligament	Spring Ligament, Plantar Calcaneo	Short & long plantar ligament
④ Tie beam	Plantar aponeurosis	
⑤ Strings	Tibialis Ant (Inverter), Tibialis post	Peroneus longus, peroneus brevis (Everter)

www.FirstRanker.com
Scanned by CamScanner

FirstRanker.com
Firstranker's choice
www.FirstRanker.com www.FirstRanker.com



Bigelow => illeofemoral ligament
(Strongest ligament)

Sciatic Nerve :-

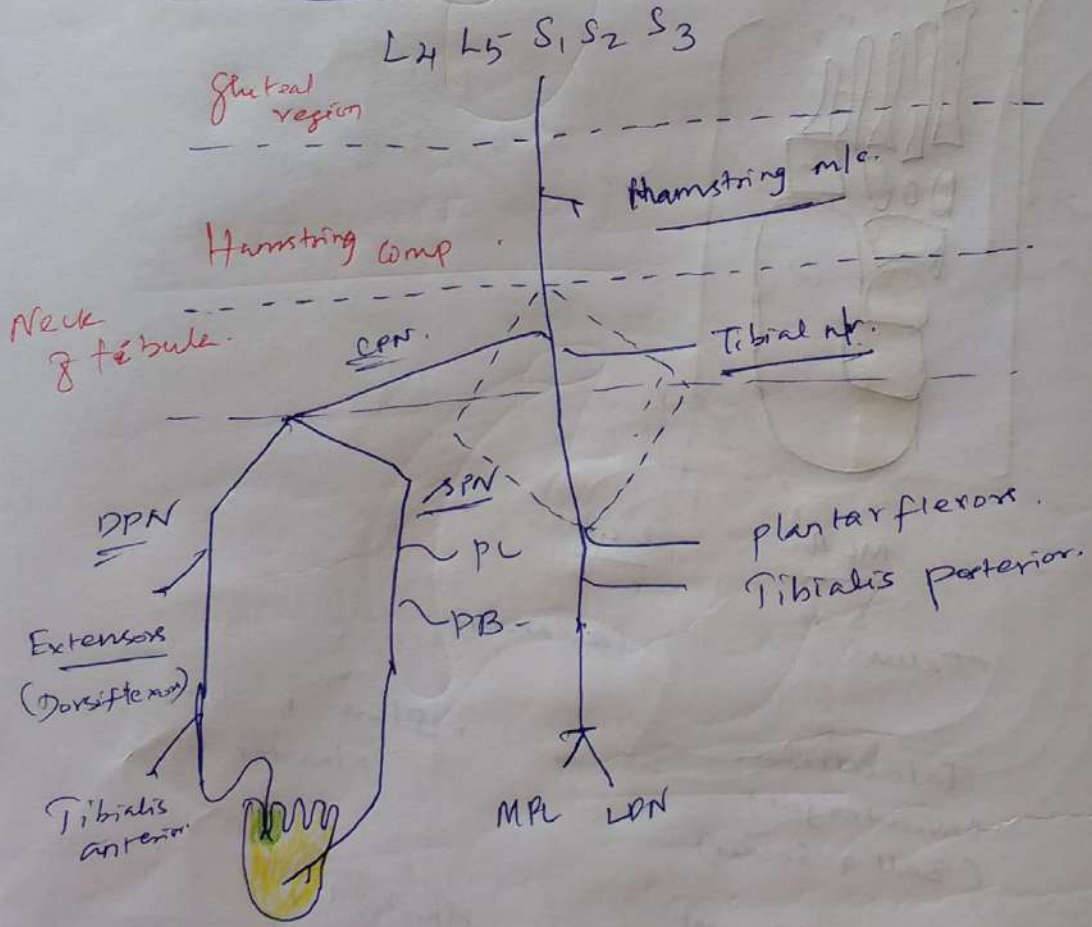

www.FirstRanker.com
Scanned by CamScanner

FirstRanker.com
Firstranker's choice
www.FirstRanker.com www.FirstRanker.com

Axillary artery :-

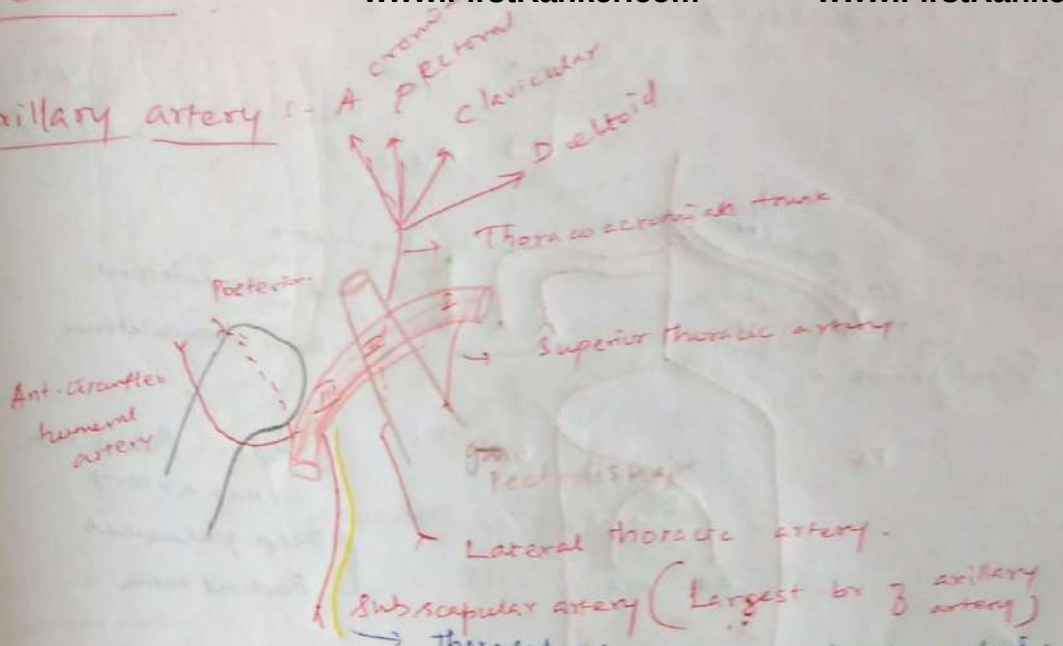

Anastomosis around Scapula :-

★ Anastomose b/w 1st part of Subclavian & 3rd part of axillary artery.

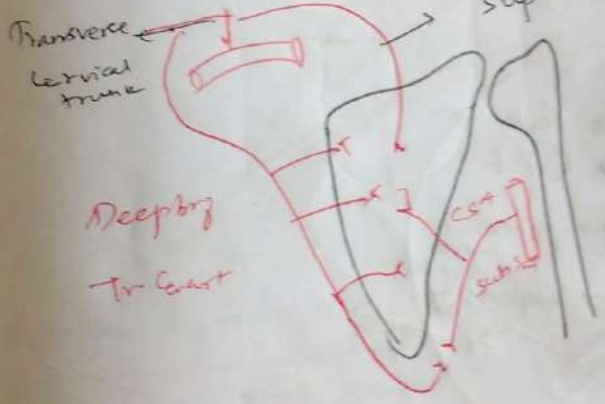

CSA

★ Circumflex Scapular artery

www.FirstRanker.com
Scanned by CamScanner

FirstRanker.com
Firstranker's choice
www.FirstRanker.com www.FirstRanker.com

Brachial artery :-

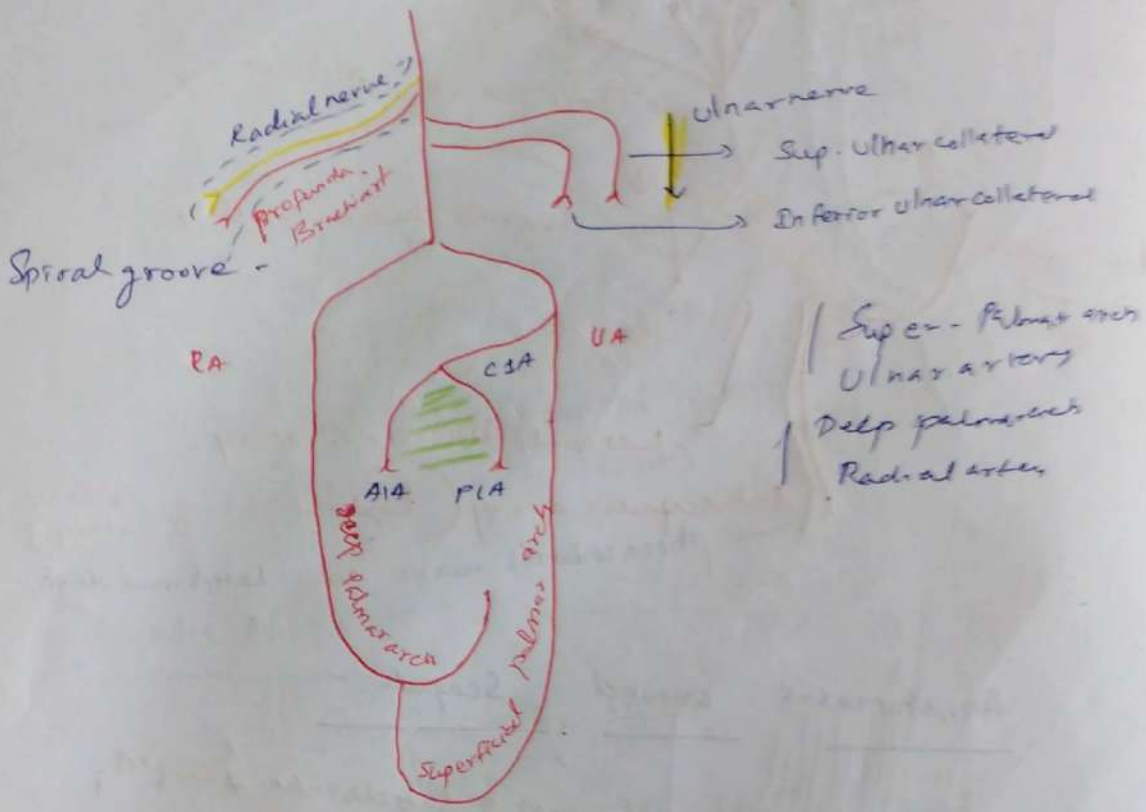

Clavipectoral Fascia :-

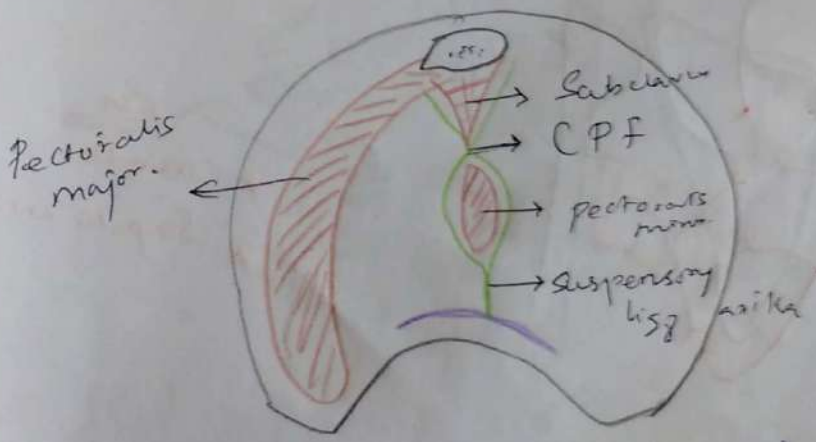

Muscles Enclosed

1. Subclavius
2. Pectoralis minor

Structu opening

www.FirstRanker.com
Scanned by CamScanner

FirstRanker.com
Firstranker's choice
www.FirstRanker.com www.FirstRanker.com

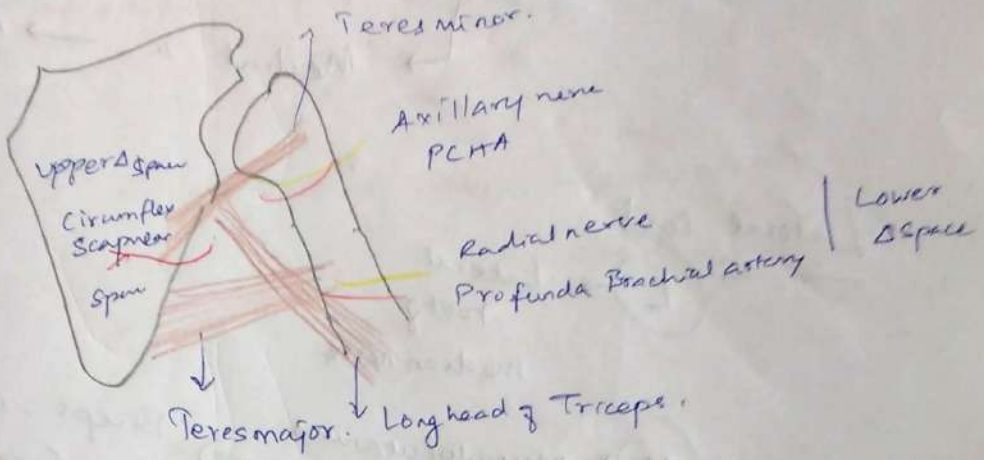

Brachial plexus

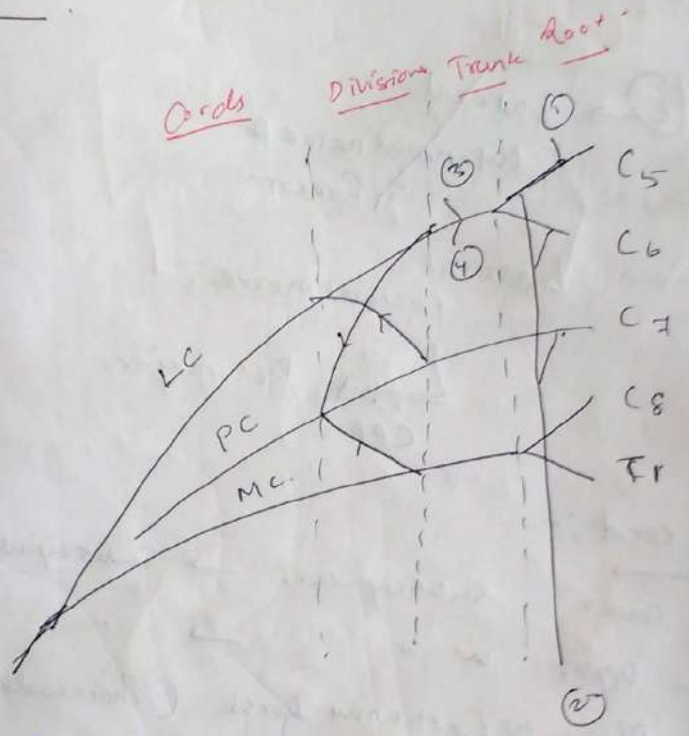

Branches from the Root.

1. Dorsal scapular nerve → Rhomboidus major, minor.
2. Long thoracic nerve → Serratus anterior.

Branches from the Trunk

3. Supra Scapular Nerve → Supraspinatus, Infra Spinatus
4. Nerve to Subclavius

www.FirstRanker.com
Scanned by CamScanner

FirstRanker.com
Firstranker's choice
www.FirstRanker.com www.FirstRanker.com

Branches from Cords → Lateral cords → LML
→ Post " → LUNAR
→ Medial " → MMV

Lateral cord

(L) → Lateral root of median nerve

(M) → Musculocutaneous nerve. ⇒ Biceps, Brachialis, CoracoBrachialis

(L) → Lateral cutaneous nerve of forearm.

Lateral pectoral nerve.
→ Pect. major.
CAT

Posterior cord :-

L - Lower Subscapular, → Subscapularis, Teres major
U - Upper. " → "
N - Nerve to Latissimus Dorsi (Thoracodorsal)
A - Axillary nerve → Deltoid & Teres minor
R - Radial nerve.

Medial cord :-

M - Medial root of median nerve.
M - Medial pectoral nerve → pectoralis minor & major
M - Medial cutaneous nerve of arm
M - " forearm.
U - Ulnar nerve.

www.FirstRanker.com
Scanned by CamScanner

FirstRanker.com
Firstranker's choice
www.FirstRanker.com www.FirstRanker.com

Erb's palsy :-

Root Value involved (C5 + C6) MCQ

↓

Axillary nerve & Musculocutaneous nerve.

(C5, C6) (C5 C6 = C7)

Coracobrachialis.

↓ ↓

Deltoid Biceps & Brachialis.

↓ ↓

Addicted shoulder Extended Elbow & pronated forearm

- ✓ Police man tip hand.
- ✓ Porter's "
- ✓ waiters "

Klumpke's palsy :-

Root Value involved C8, T1.

↓

major root value & intrinsic muscles of hand.

↓

Hyper Extension @ Metacarpophallangeal joint
Flexion @ IP joints.

↓

Claw hand

www.FirstRanker.com
Scanned by CamScanner

FirstRanker.com
Firstranker's choice
www.FirstRanker.com www.FirstRanker.com

Horner syndrome :-

- ✓ ptosis → muller muscle (Smooth muscle component of LPS)
- ✓ miosis → Dilator pupillae. (muller)
- ✓ Enophthalmos → Apparent : Reduction in size of palpebral fissure
  True :- orbitalis muscle involvement.
- ✓ Heterochromia iridis.
  - Failure of Deposition of melanin.
  - If the injury is before the age of 2

Hand

- ✱ 20 m/s
- ✱ Thenar m/s (4)
  - → Abductor pollicis brevis
  - → Flexor pollicis brevis
  - → Opponens pollicis.
  - → Adductor pollicis.

  (Abductor pollicis brevis, Flexor pollicis brevis, Opponens pollicis) — Median nerve
  (Adductor pollicis) — Ulnar nerve

✱ Function of thumb completely lost in median nerve injury @ carpal tunnel injury

✱ Function of thumb completely lost in Ulnar nerve # Adduction.

✱ Radial nerve ↓ Extension.

✱ movement of thumb can be used to Test all long nerves of upper Limb.

www.FirstRanker.com
Scanned by CamScanner

FirstRanker.com
Firstranker's choice
www.FirstRanker.com www.FirstRanker.com

2) Hypothenar M/s :- (4)

- Abductor digiti minimi
- Flexor digiti minimi
- opponens digiti minimi
- palmaris brevis.

Ulnar nerve
Dominant Nerve of Hand.

⇓ S/c no bony attach

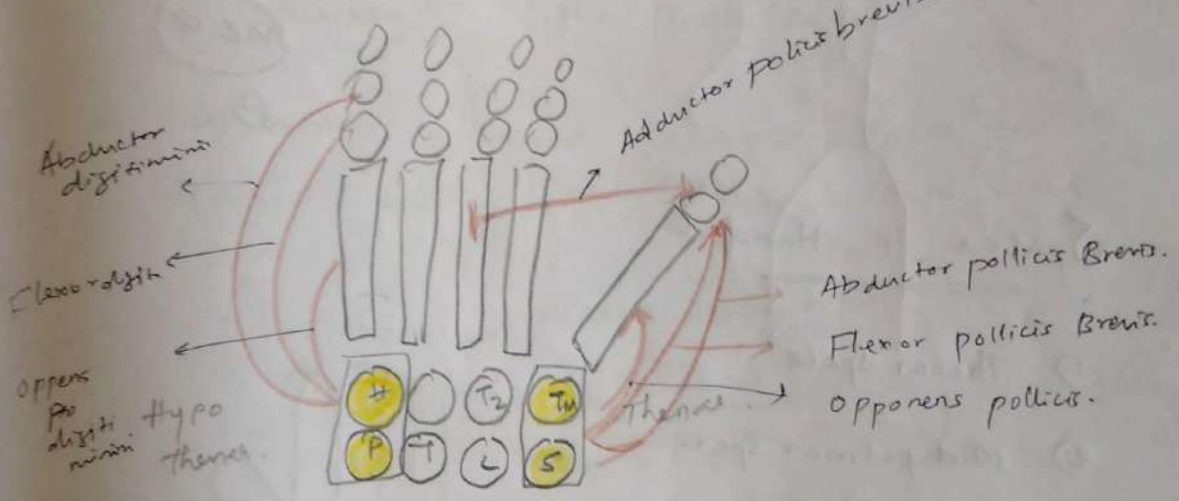

(* Bennet's # → muscle involved → oppens pollicis.)

Lumbricals :-

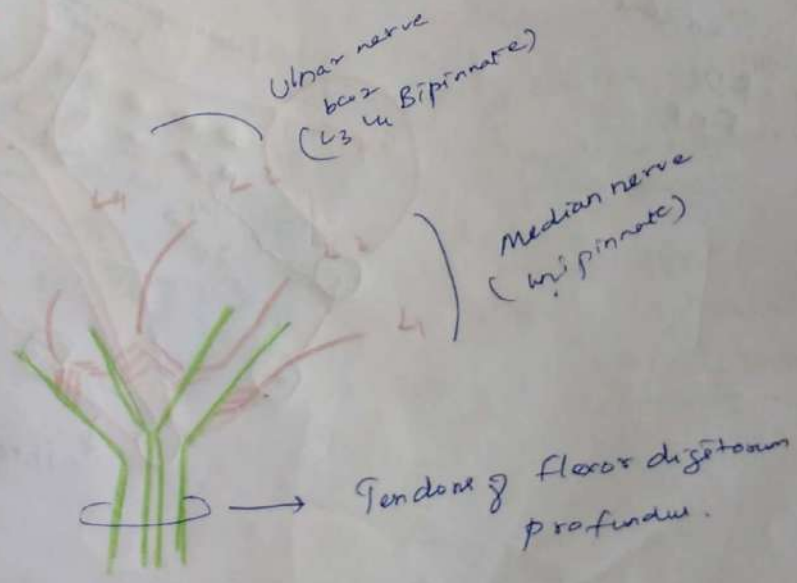

www.FirstRanker.com
Scanned by CamScanner

FirstRanker.com
Firstranker's choice
www.FirstRanker.com www.FirstRanker.com

Interossei → Palmar (4) Unipinnate (UN)
→ Dorsal (4) Bipinnate (UN)

P - AD → is absent on Middle finger.
D - AB. → is absent on Thumb & Little finger.

MCQ

Spaces in Hand :-

1) Thenar Space
2) Mid palmar Space.
3) pulp Space.
4) Forearm Space & parona.

Tendons
FDS
FDP

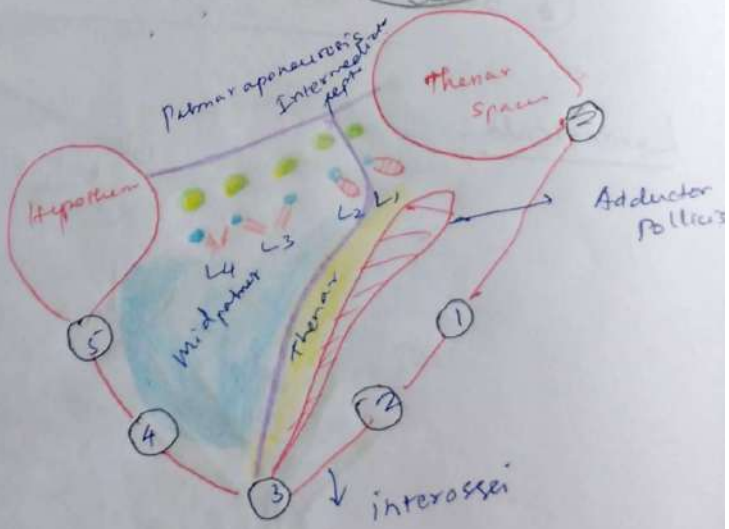

www.FirstRanker.com
Scanned by CamScanner

FirstRanker.com
Firstranker's choice
www.FirstRanker.com www.FirstRanker.com

* Thenar space communicates c̄ facial sheath of 1st Lumbricals.

* Mid palmar space communicates c̄ facial sheath of 2, 3, 4th lumbricals.

* Infections of Thenar space can be drained by incising 1st web space.

* Infections of mid palmar space can be drained by 3rd, 4th web space

[Flexor digitorum profundus.
(← Space →)
Forearm of parona.
Pronator Qudratus]

Pulp Space :-

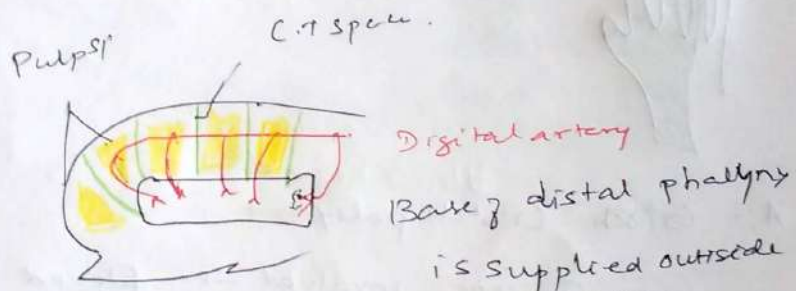

Base of distal phallynx is supplied outside pulp space

Prolonged PS inf ⟹ AVN Distal 4/5th of Distal Phx.

www.FirstRanker.com
Scanned by CamScanner

FirstRanker.com
Firstranker's choice
www.FirstRanker.com

Radial Nerve (C5-T1)

www.FirstRanker.com

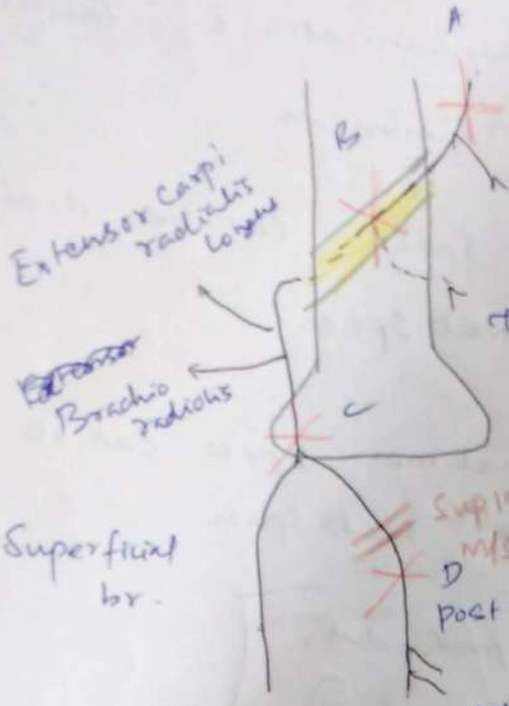

Skin of lat 3½ & Dorsum of hand

Except nail bed

A:- ~~Cat~~ Crutch palsy

Triceps involved → flexed Elbow

Wrist Extensor " → wrist drop

Finger " " → finger drop.

B: Saturday night palsy :-

* Triceps is partly involved → weakness in Elbow extension

* Wrist Extensors involved → wristdrop.

* Finger " " → fingerdrop.

Sensory loss on dorsum of hand

www.FirstRanker.com
Scanned by CamScanner

FirstRanker.com
Firstranker's choice
www.FirstRanker.com www.FirstRanker.com

Lat. epicondylar ~~#~~.

- ECRL is Saved → no wrist drop.
- Extensor Digitorum is involved → Finger Drop.

Sensory loss on Dorsum of hand.

D:- Radial ~~Nerve~~ head # / Inj to PIN

no wrist Drop.

Finger Drop (+)

Sensory on Dorsum of hand INTACT.

Median nerve (C5–T1)

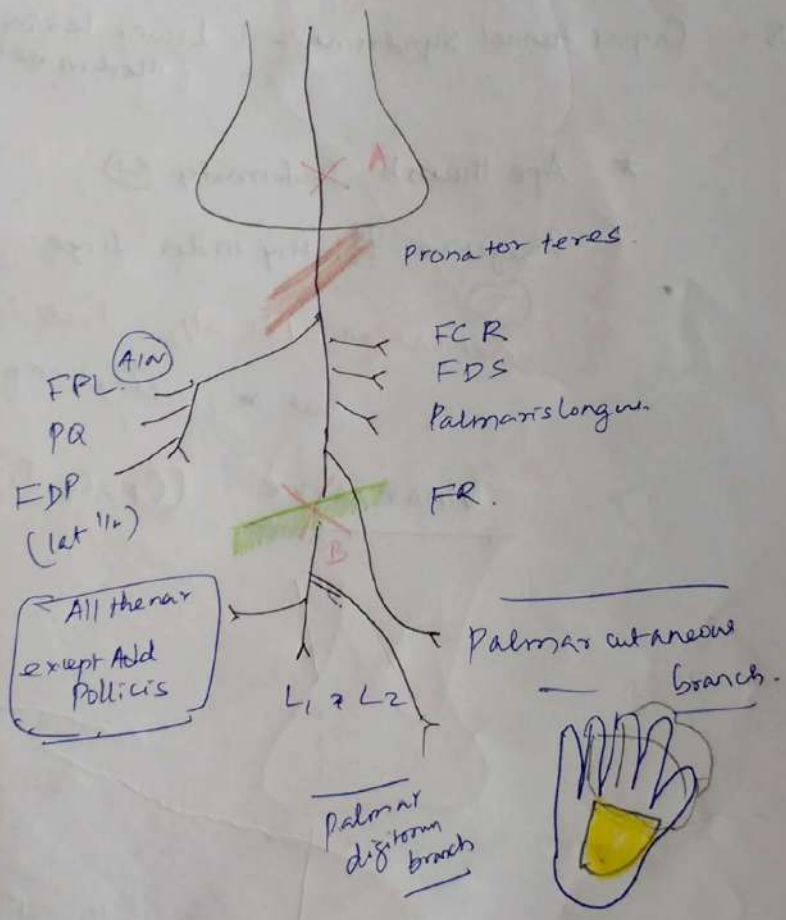

www.FirstRanker.com
Scanned by CamScanner

FirstRanker.com
Firstranker's choice
www.FirstRanker.com www.FirstRanker.com

A :- Higher Medial [illegible]
- Supra condylar #
- pronator teres syndrome.

* Oppenens pollicis involved → Ape thumb deformity

* FDS & Lat 1/2 FDP → pointing index finger.

Sensory loss lat 3 1/2 of palm & fingers.

B :- Carpal tunnel Syndrome :- (Lower lesion of Median nerve)

* Ape thumb Deformity (+)
- Negative Pointing index finger (−)

Sensation lat 3 1/2 loss but inctact on palm

Ulnar nerve (C7, C8, T1)

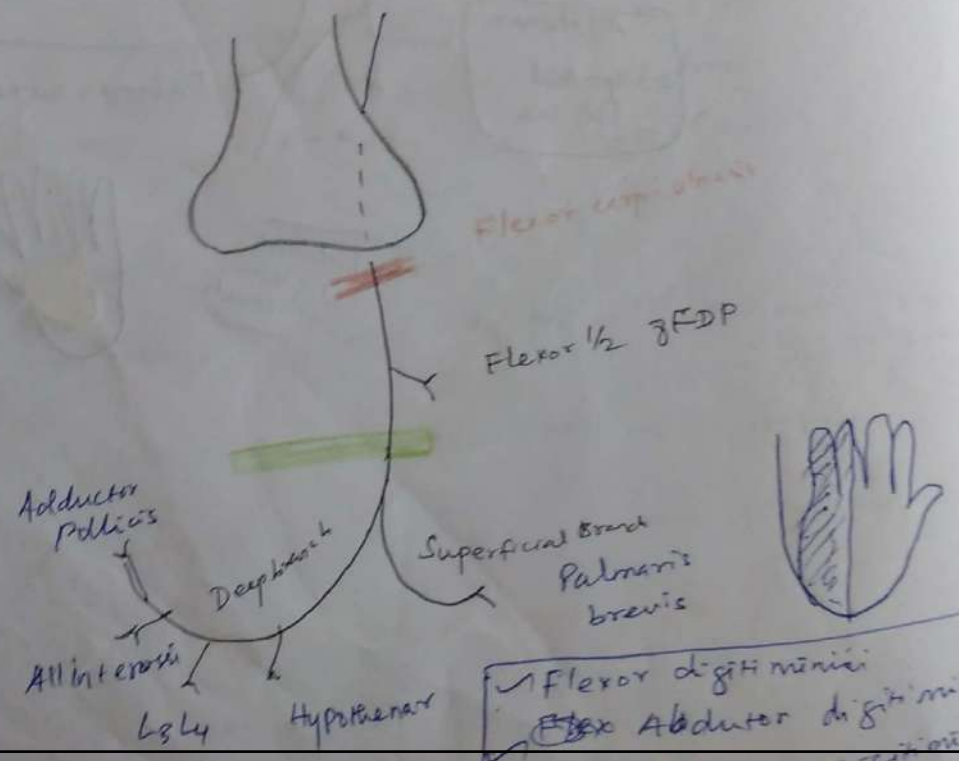

- Flexor digiti minimi
- Abdutor digiti minimi
- Opponens digiti minimi

www.FirstRanker.com
Scanned by CamScanner

FirstRanker.com
Firstranker's choice
www.FirstRanker.com www.FirstRanker.com

* Proximal Ulnar nerve injury => less severe

as muscle producing flexion @ Distal Interphalangeal joint also involved.

Ulnar Paradox

* Recovery phase also shows paradox.

Hybrid muscles :-

* SCM, T_2.
* Pectineus, Adductor magnus.
* Pectoralis Major.
* Subscapularis.
* Brachialis.
* Flexor digitorum profundus
* Flexor pollicis brevis.

Tashwani.7@gmail.com

www.FirstRanker.com
Scanned by CamScanner

FirstRanker.com
Firstranker's choice
www.FirstRanker.com www.FirstRanker.com

osteology

flat bone

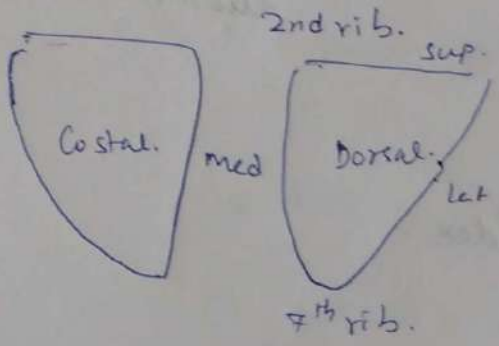

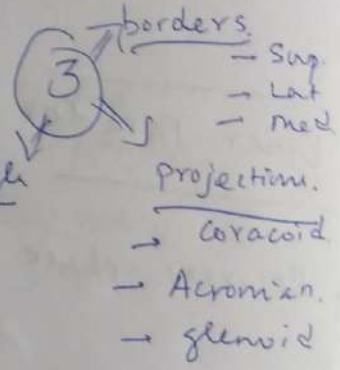

Sup border.

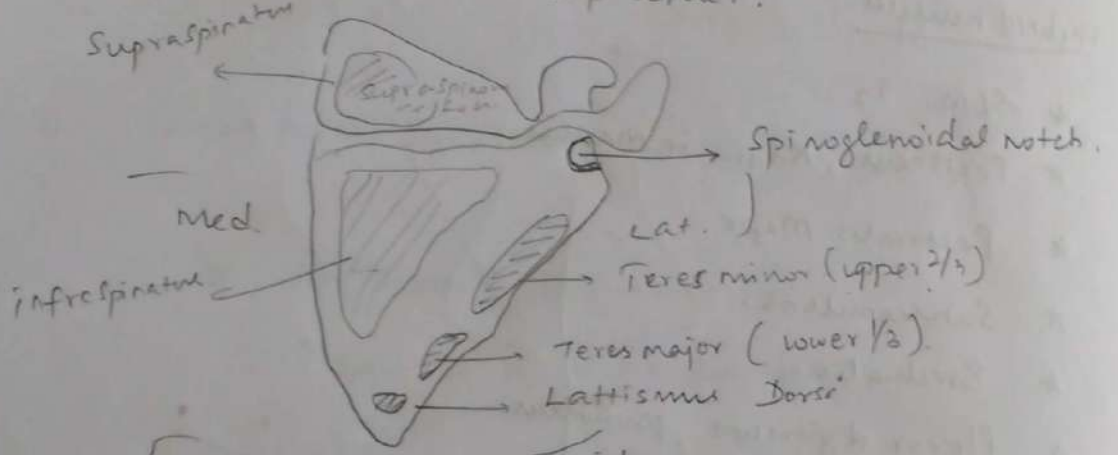

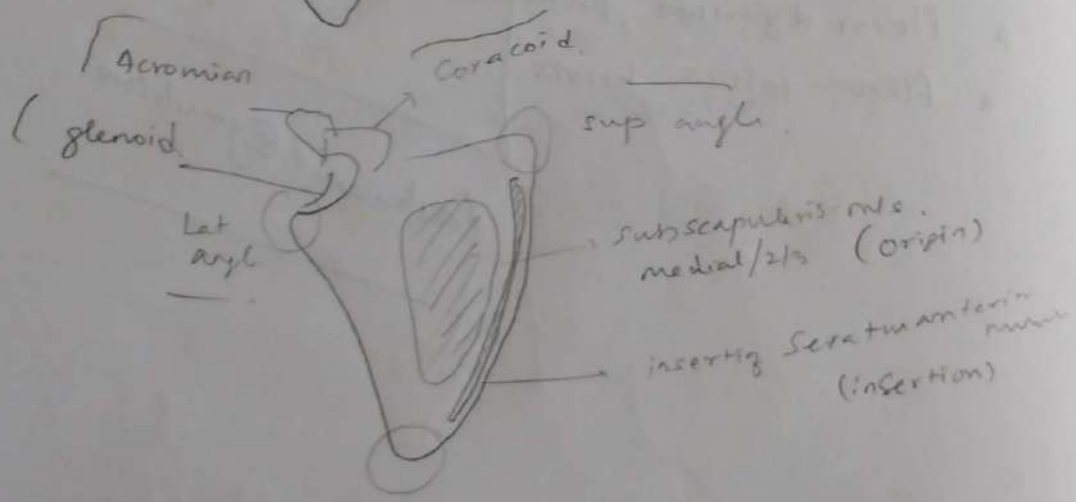

Inferior angle.

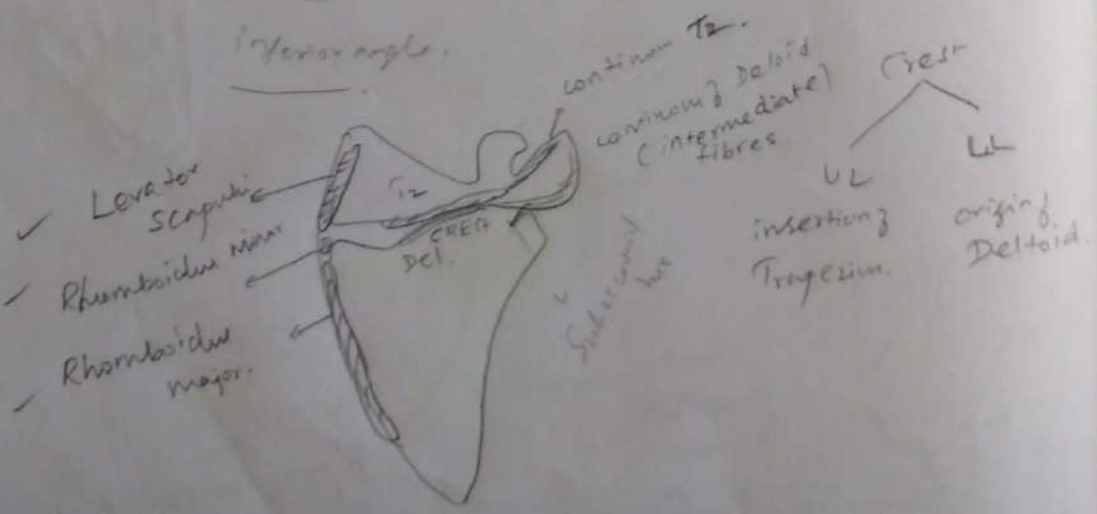

www.FirstRanker.com
Scanned by CamScanner

FirstRanker.com
Firstranker's choice
www.FirstRanker.com www.FirstRanker.com

Atypical epiphysis :-

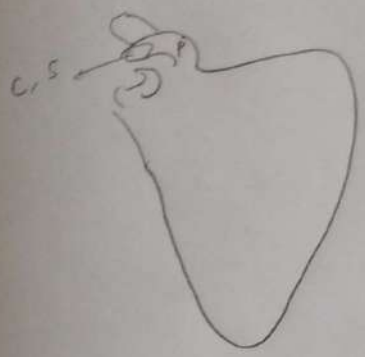

Pectoralis minor
Coracobrachialis
Short head of Biceps Brachii

Ossified from
- Body — 1 primary centre → 8th wk of IUL
- 7 secondary centre :

1st yr Postnatal :-
- 2 - Acromion.
- 2 - Coracoid.
- 1 - medial border of scapula.
- 1 - inferior angle.
- 1 - lower of glenoid cavity

appears in puberty
fuses. 20 yr

www.FirstRanker.com
Scanned by CamScanner