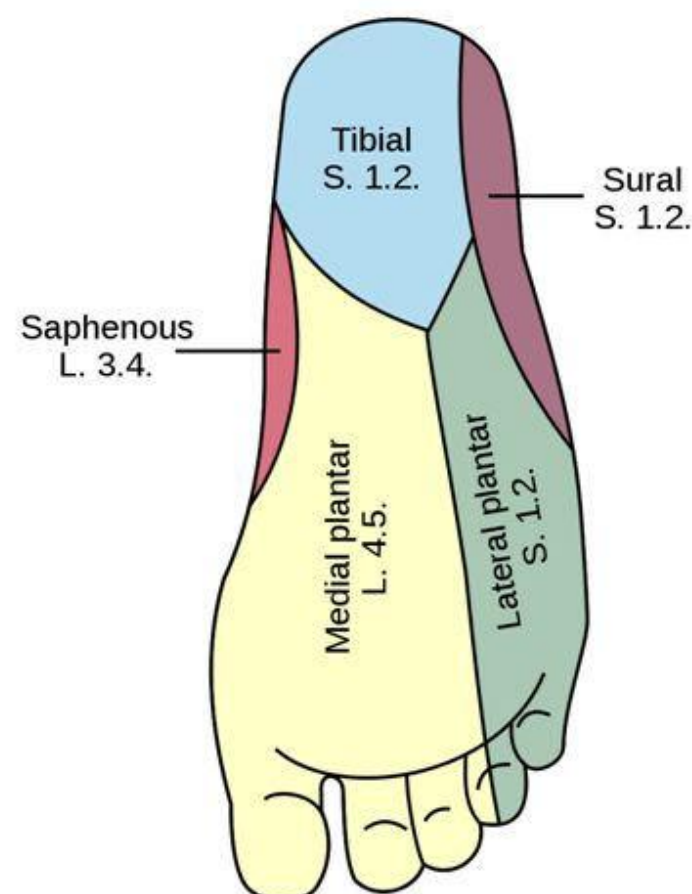


Learning Objectives

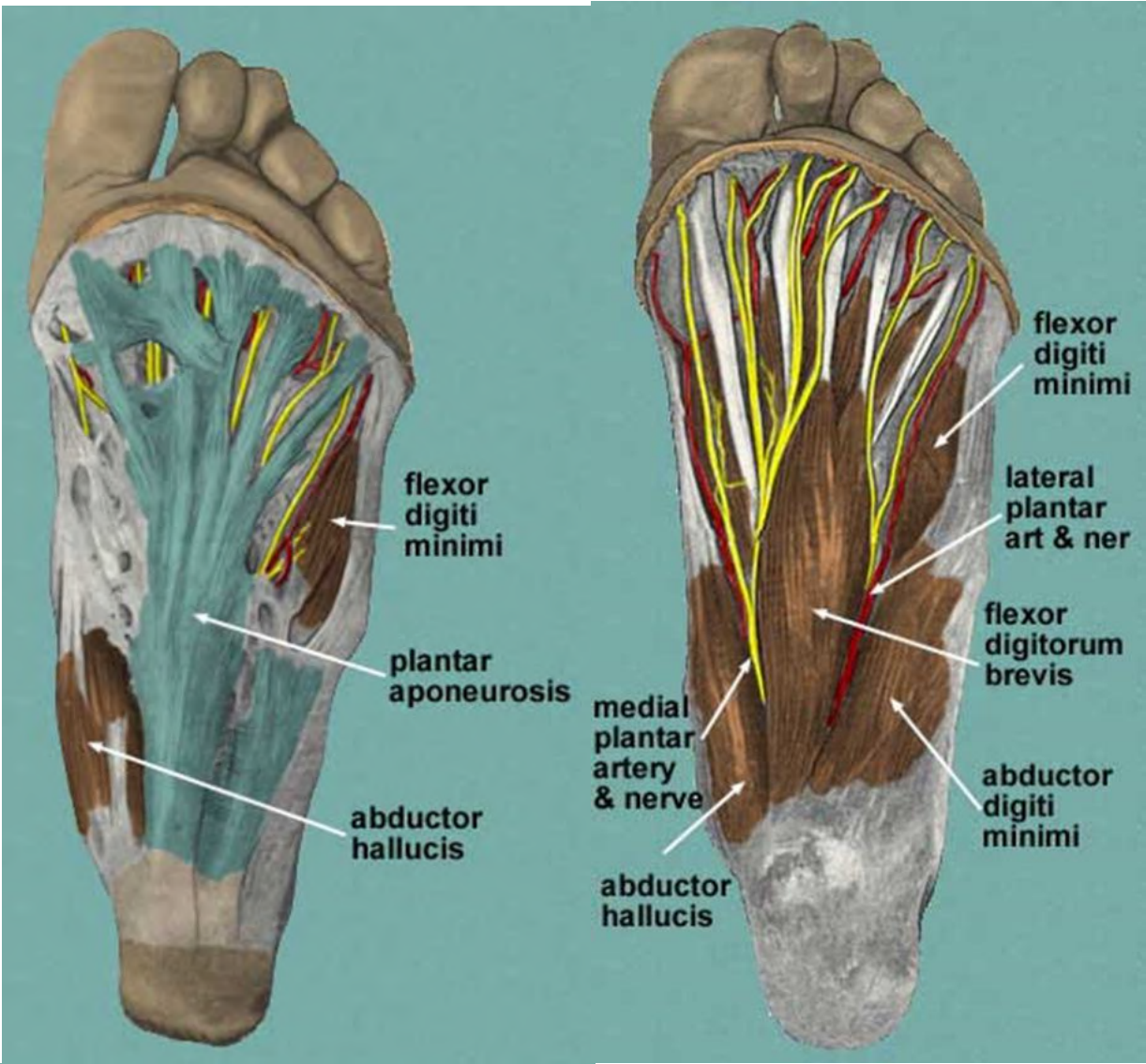
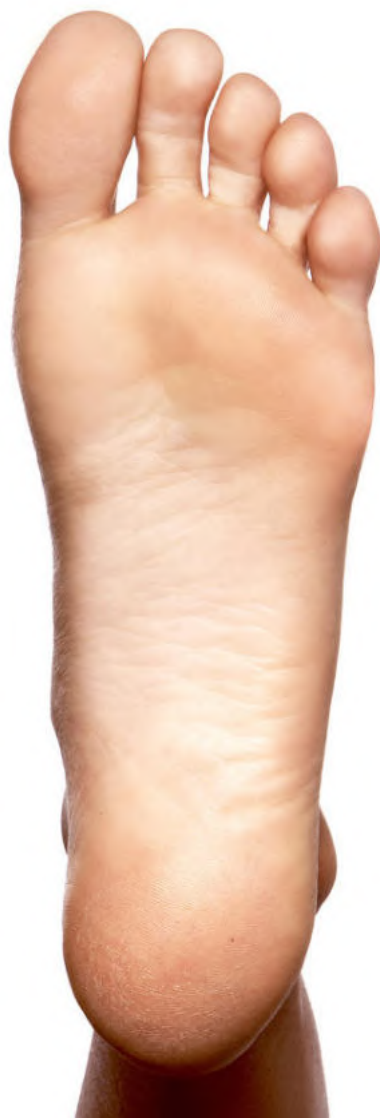- Cutaneous nerve and blood supply
- Plantar aponeurosis
- Muscles, attachment, actions, innervations
- Plantar nerve and Vessels
- Clinical correlates

CUTANEOUS NERVES

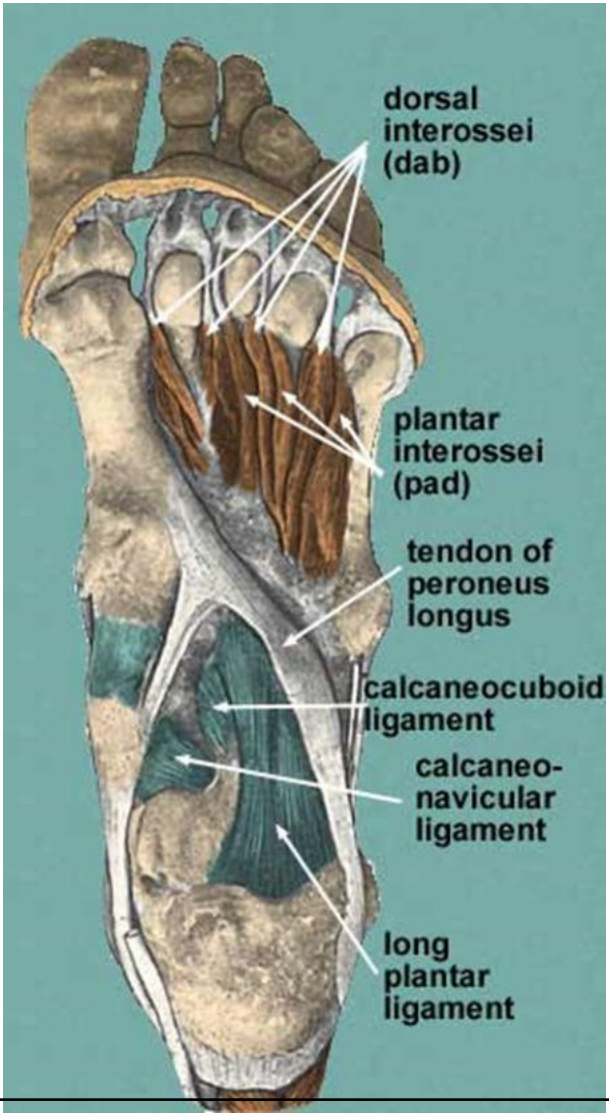
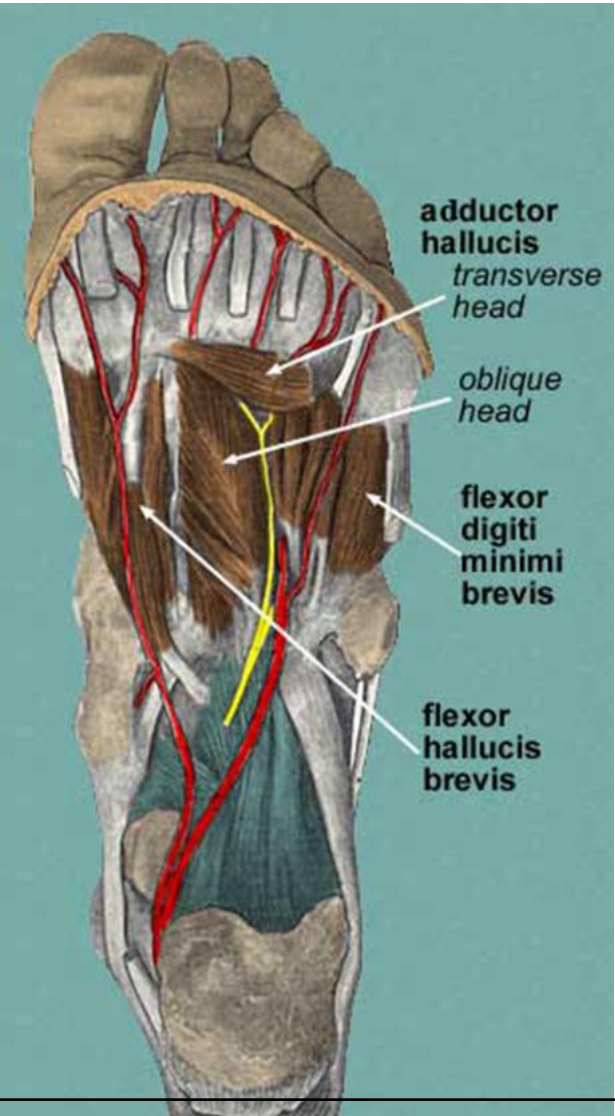
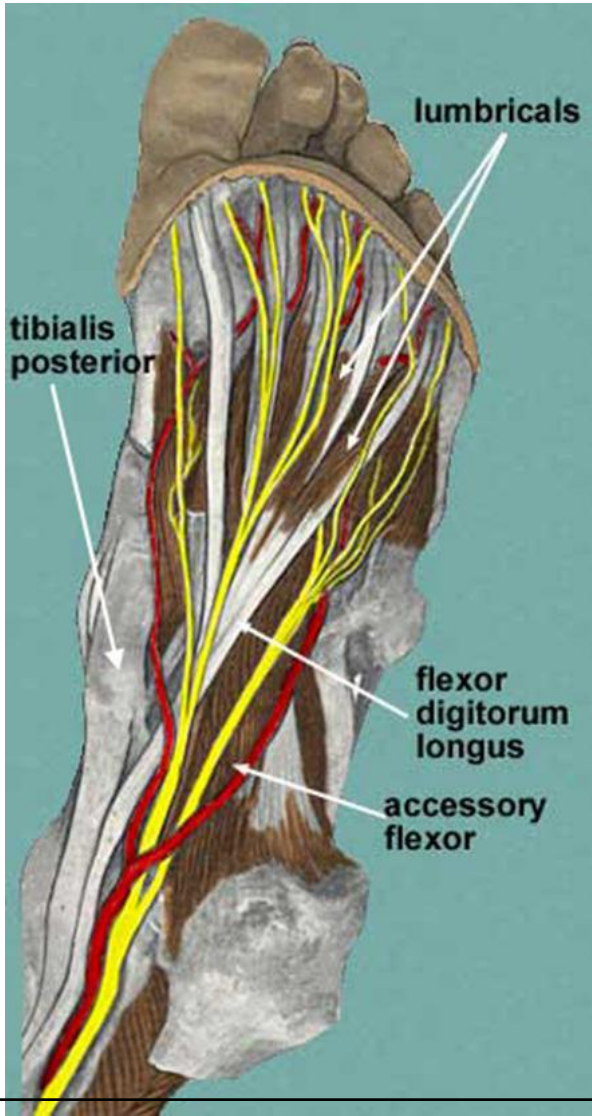
- ✓ **Medial calcaneal branch of the tibial nerve**
- ✓ **Medial plantar nerve**
- ✓ **Lateral plantar nerve**
- ✓ **Sural & saphenous nerve**



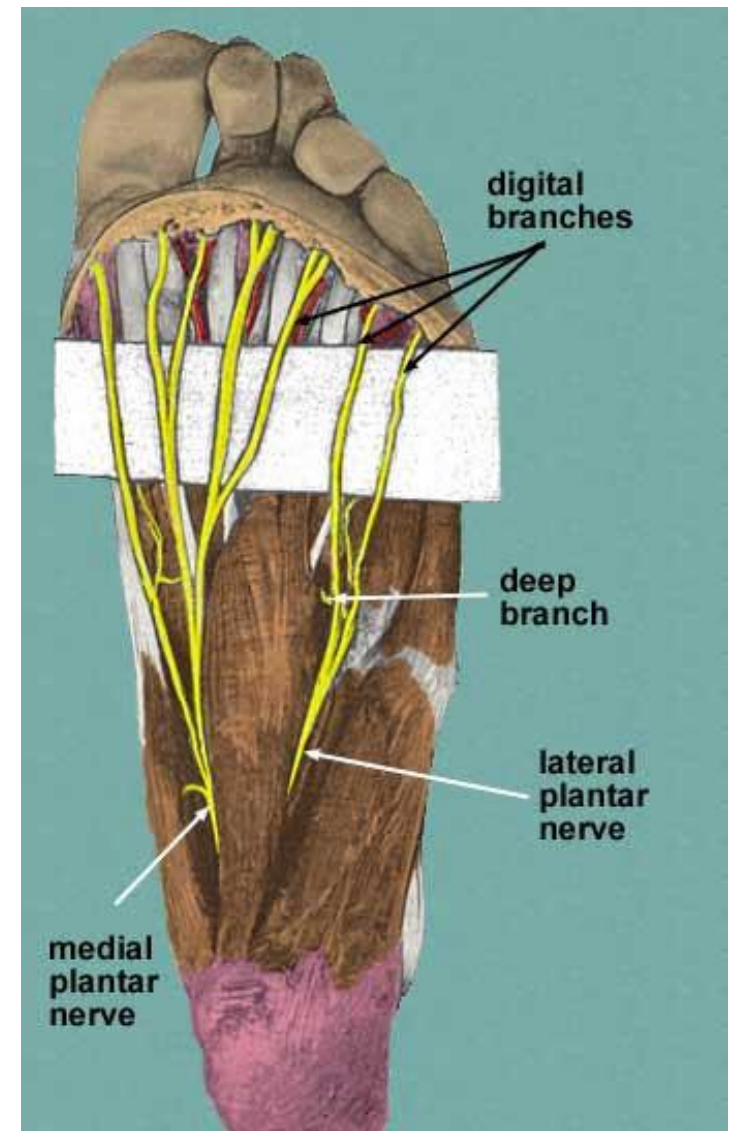
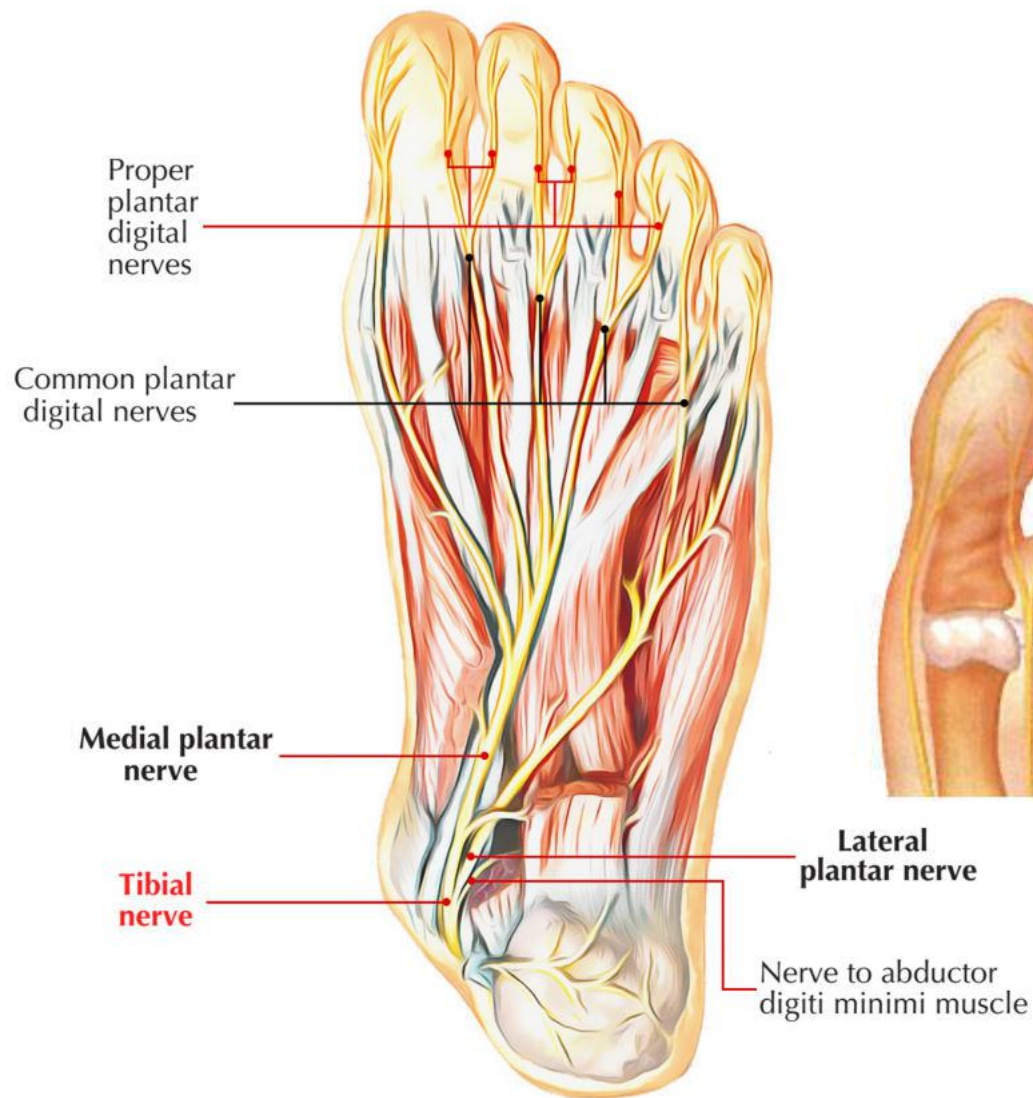
Sole of Foot/Layers



Different Layers of Sole of Foot



Lateral and Medial Plantar Nerves



Clinical Correlates

- Entrapment neuropathies
- Baxter's nerve and neuropathy
- Knot of Henry
- Morton's Neuroma

MCQs

Q. Baxter's neuropathy in which there is pain on the bottom of the foot is due to involvement of which of the following nerve?

- a. Inferior Calcaneal Nerve
- b. Medial Plantar Nerve
- c. Superficial branch of Lateral Plantar Nerve
- d. Deep Branch of Lateral Plantar Nerve

www.FirstRanker.com