

Learning Objectives

- Dermatomes of lower limb
- Cutaneous nerves of lower limb:
 - Areas of distribution and
 - Spinal segments of origin
 - Clinical Correlates

Dermatomes of lower limb

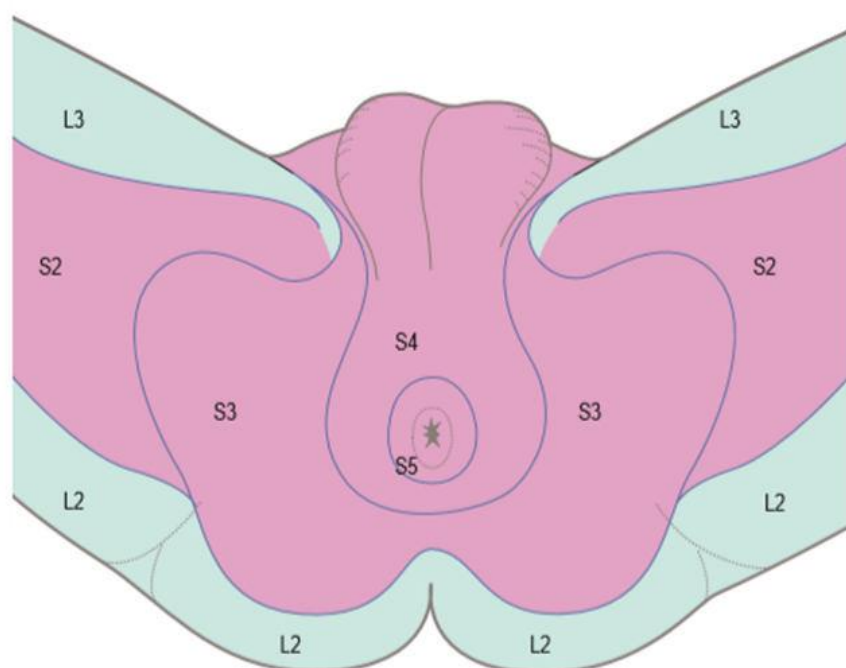


Fig. 78.13 Dermatomes of the perineum. (With permission from O'Brien M, Aids to the Examination of the Peripheral Nervous System, 5th Edition, May 2010, Elsevier, Saunders.)

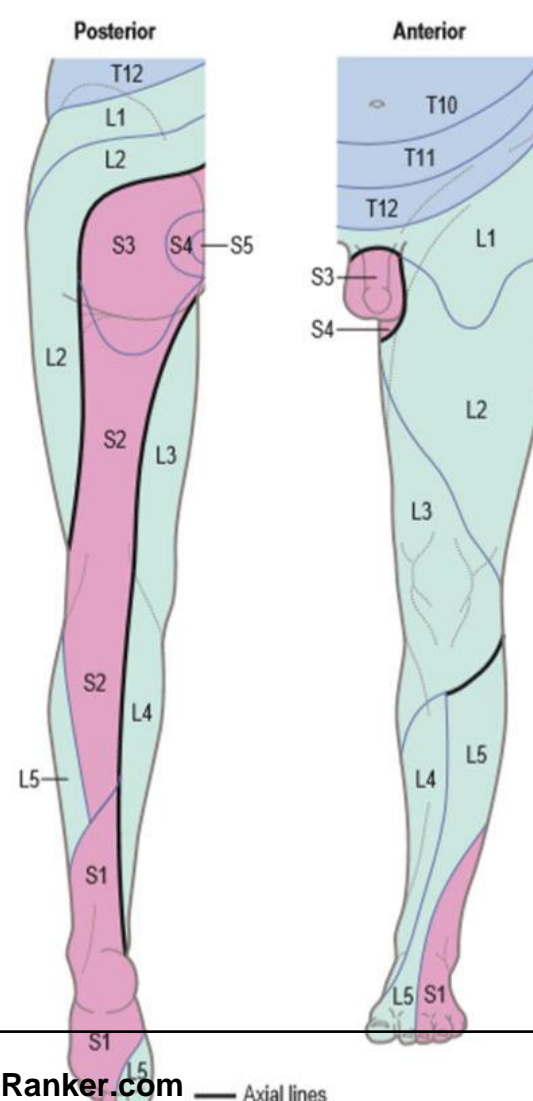


Fig. 78.14 Dermatomes of the lower limb. There is considerable variation and overlap between dermatomes, but the overlap across axial lines (heavy black) is minimal. (With permission from O'Brien M, Aids to the Examination of the Peripheral Nervous System, 5th Edition, May 2010, Elsevier, Saunders.)

Overview of Body Dermatomes

C1	No skin supply
C2	Occipital region, posterior neck and skin over parotid
C3	Neck
C4	Infraclavicular region (to manubriosternal junction), shoulder and above scapular spine
C5	Lateral arm
C6	Lateral forearm and thumb
C7	Middle fingers
C8	Little finger and distal medial forearm
T1	Medial arm above and below elbow
T2	Medial arm, axilla and thorax
T3	Thorax and occasional extension to axilla
T4	Nipple
T7	Subcostal angle
T8	Rib margin
T10	Umbilicus
T12	Lower abdomen, upper buttock
L1	Suprapubic and inguinal regions, penis, anterior scrotum (labia), upper buttock
L2	Anterior thigh, upper buttock
L3	Anterior and medial thigh and knee
L4	Medial leg, medial ankle and side of foot
L5	Lateral leg, dorsum of foot, medial sole
S1	Lateral ankle, lateral side of dorsum and sole
S2	Posterior leg, posterior thigh, buttock, penis
S3	Sitting area of buttock, posterior scrotum (labia)
S4	Perianal
S5 and Co	Behind anus and over coccyx.

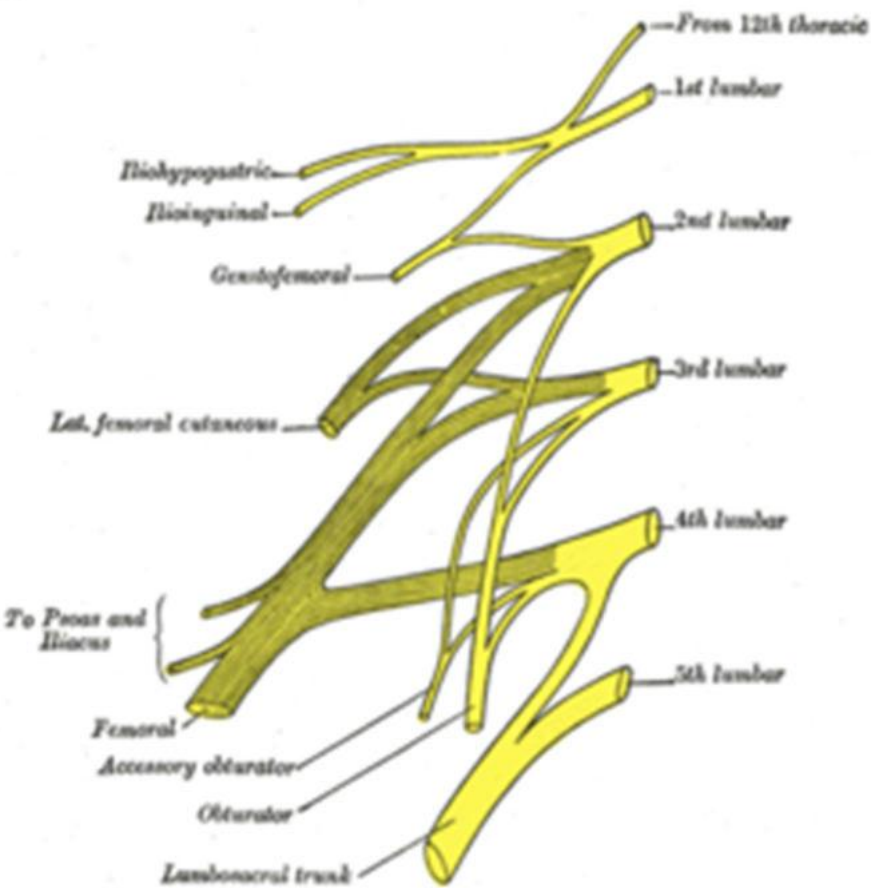
Cutaneous Nerves of Lower Limb

1. Dorsal Rami of L1,L2,L3
2. Dorsal Rami of S1,S2,S3
3. Lateral Cutaneous Branch of Subcostal Nerve(T12)
4. Lateral Cutaneous Branch of Iliohypogastric Nerve(L1)
5. Lateral, Medial and Intermediate Cutaneous Nerve of Thigh(DD-L2,L3,L4)
6. Posterior Cutaneous Nerve of Thigh(VD-S2,S3 and DD-S1,S2)
7. Perforating Cutaneous Nerve (DD-S2,S3)
8. Saphenous Nerve(DD-L2-4)
9. Lateral Cutaneous Nerve of Calf(DD-L2,L3)
10. Sural Nerve(VD-S1,S2)
11. Superficial and Deep Peroneal Nerve
12. Calcaneal Branch of Tibial Nerve(VD-S1,S2)

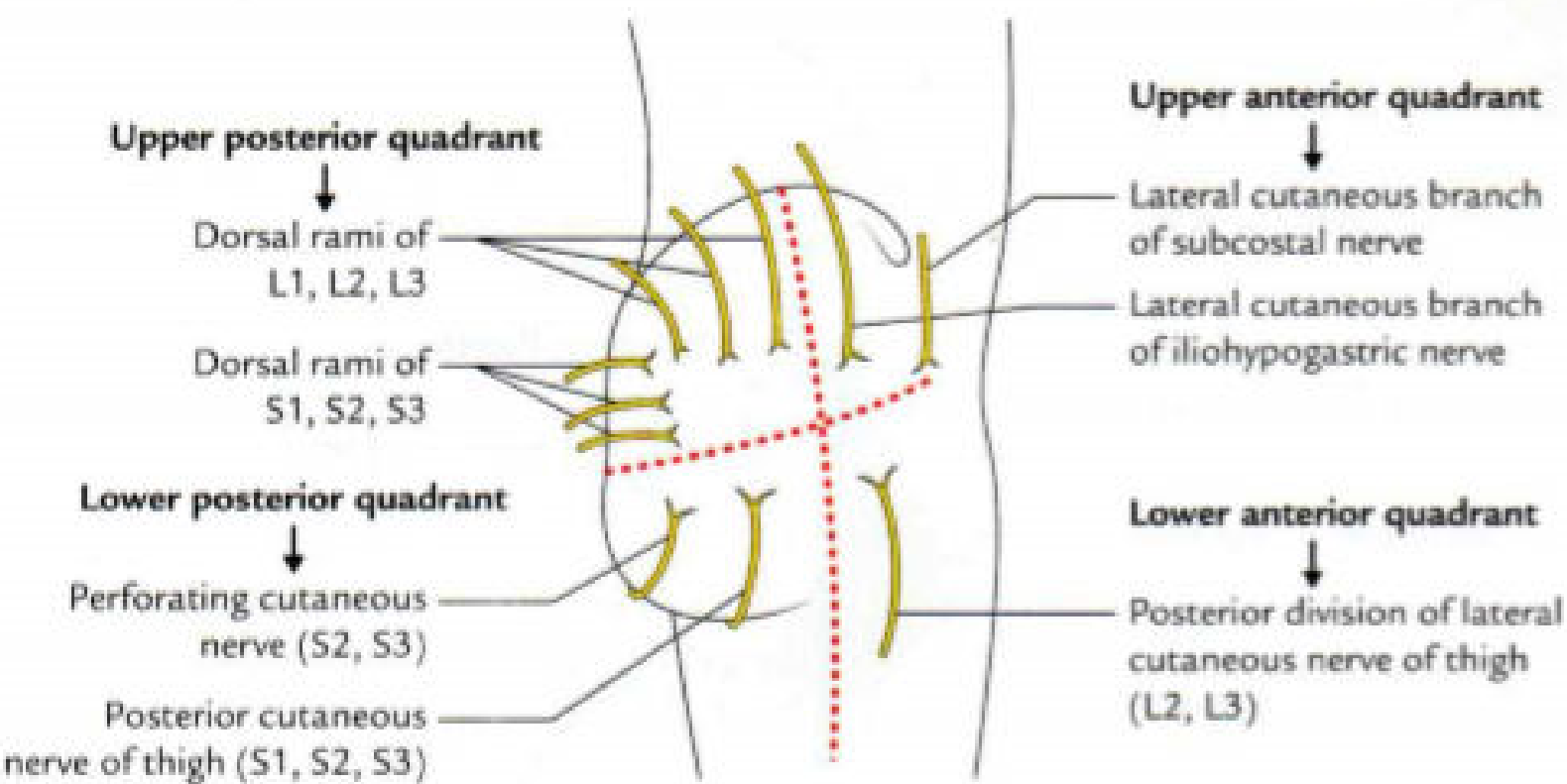
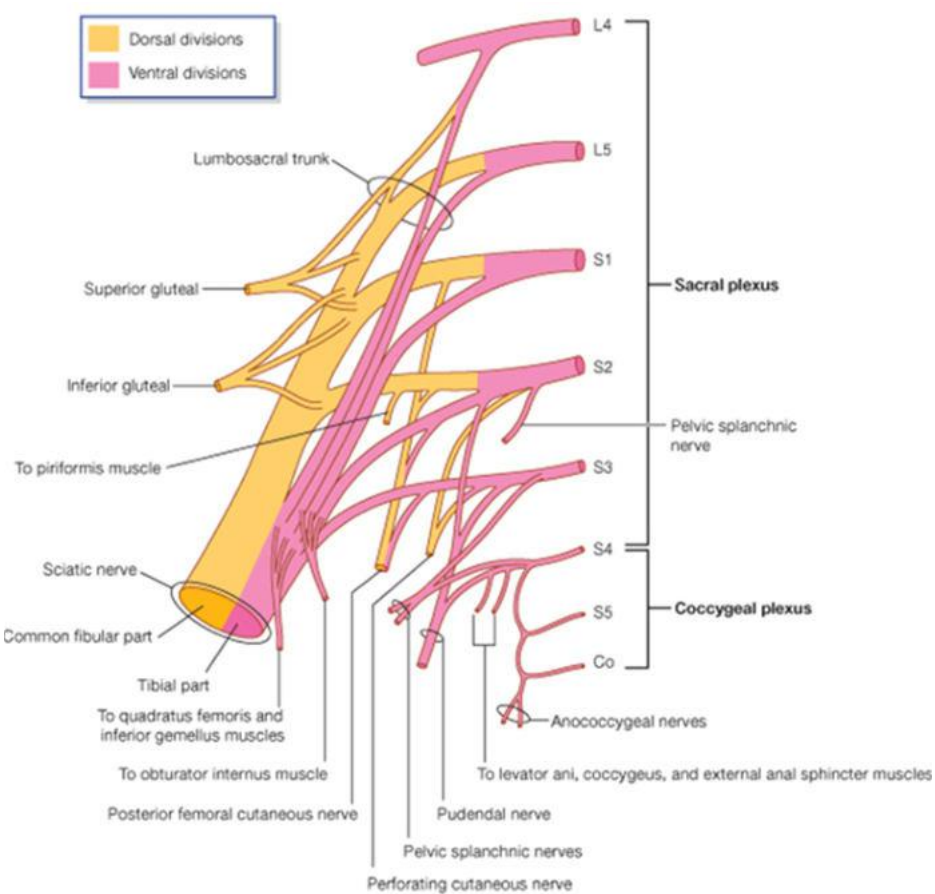
Innervation

Plexuses of the Lower Limb/Lumbosacral plexus

Lumbar Plexus

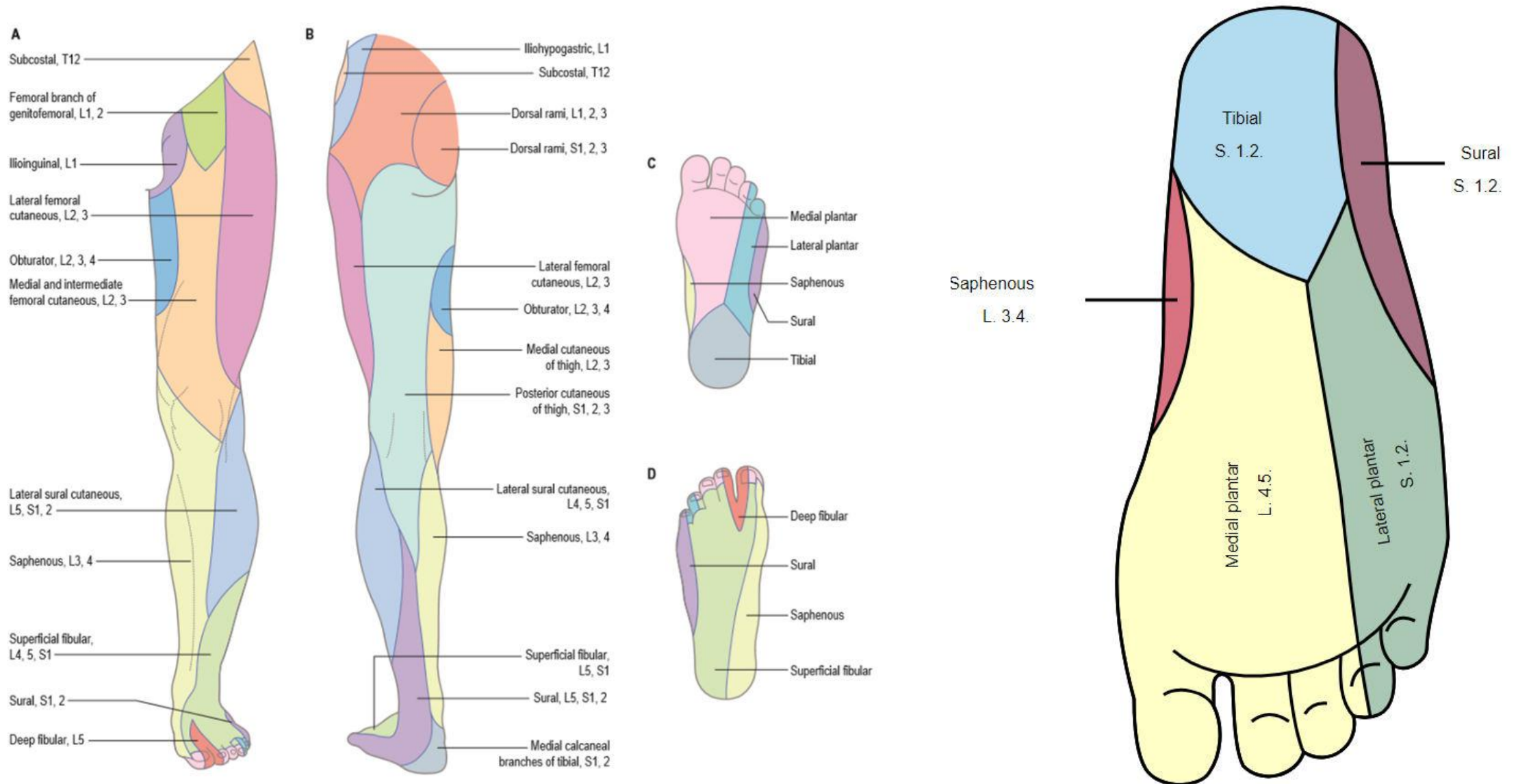


Sacral Plexus



Cutaneous nerves of the gluteal region.

Cutaneous Innervation of Lower Limb



MCQs

Question :- An examiner has asked the student about the dermatomal innervation of anterior surface of knee joint. What do you think will be the most appropriate answer of this question?

- L2
- L3
- L4
- L5

Question :- Meralgia paraesthetica is condition which produces an area of impaired sensation, often with pain and paraesthesia on the anterolateral aspect of the thigh. Injury to which of the following nerve is responsible for this condition?

- a. Medial cutaneous nerve of thigh
- b. Lateral cutaneous nerve of thigh
- c. Posterior cutaneous nerve of thigh
- d. Intermediate cutaneous nerve of thigh

www.FirstRanker.com