

# PRIMARY ANGLE CLOSURE GLAUCOMA

## Acknowledgement

- Kanski's Clinical Ophthalmology (8<sup>th</sup> Edition).
- Becker- Schaffer's Diagnosis and therapy of The Glaucomas (8<sup>th</sup> Edition).
- Comprehensive Ophthalmology (A.K.Khurana) (7<sup>th</sup> Edition).

# Learning Objectives

- **At the end of this class the students shall be able to :**
- Define primary angle closure glaucoma.
- Understand the pathophysiology and the risk factors.
- Be able to classify primary angle closure glaucoma.
- Understand the fundamentals of managing primary angle closure glaucoma

3

## Question

- Which of the following medications is least likely to be associated with the induction or aggravation of angle-closure glaucoma?
- a. pilocarpine.
- b. oral antihistamines.
- c. cyclopentolate.
- d. aspirin

## DEFINITION

- Primary angle closure glaucoma is a type of **primary glaucoma** (with no obvious systemic or ocular cause) characterized by **occludable/closed angles** leading to obstruction of aqueous outflow resulting in **rise of intra ocular pressure, optic nerve damage and visual field defects**.

5

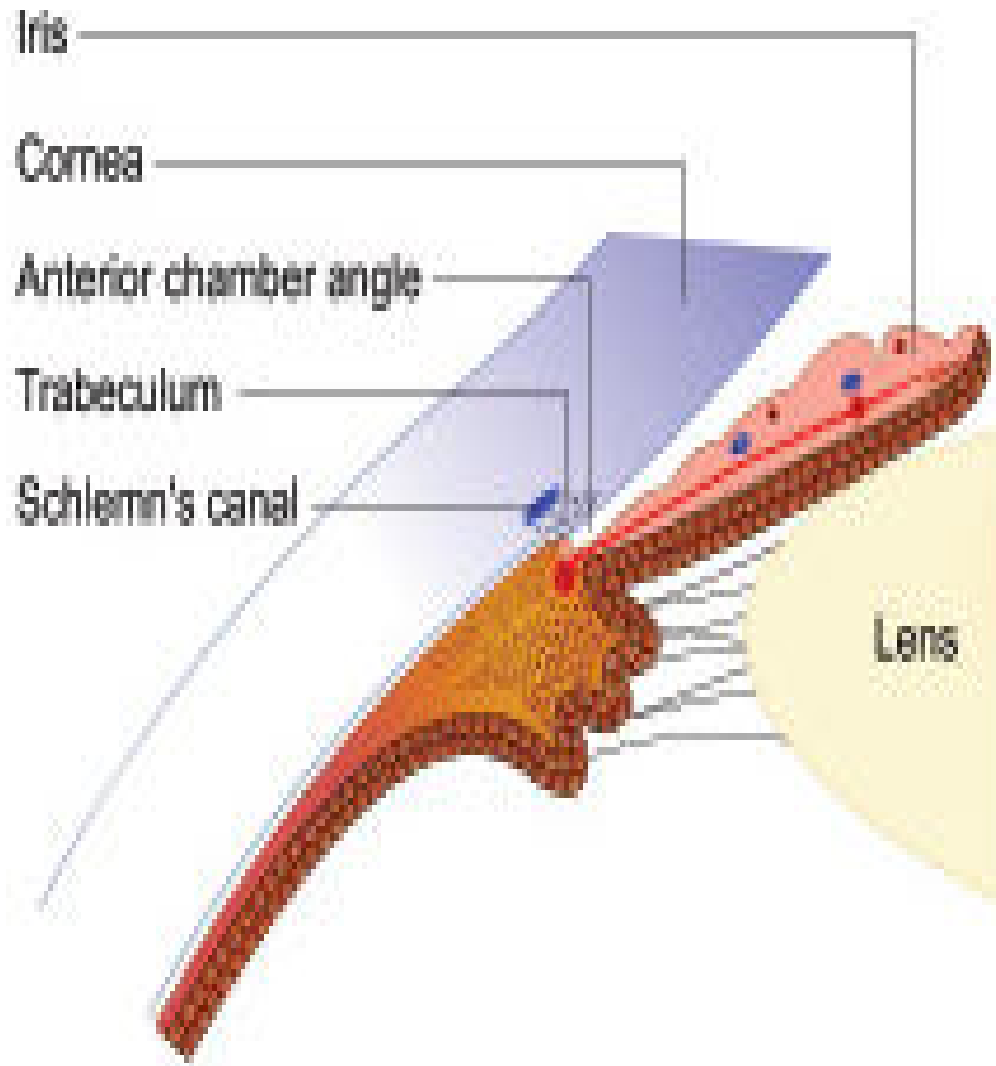
## Video on applanation tonometry



Applanation tonometry.mp4

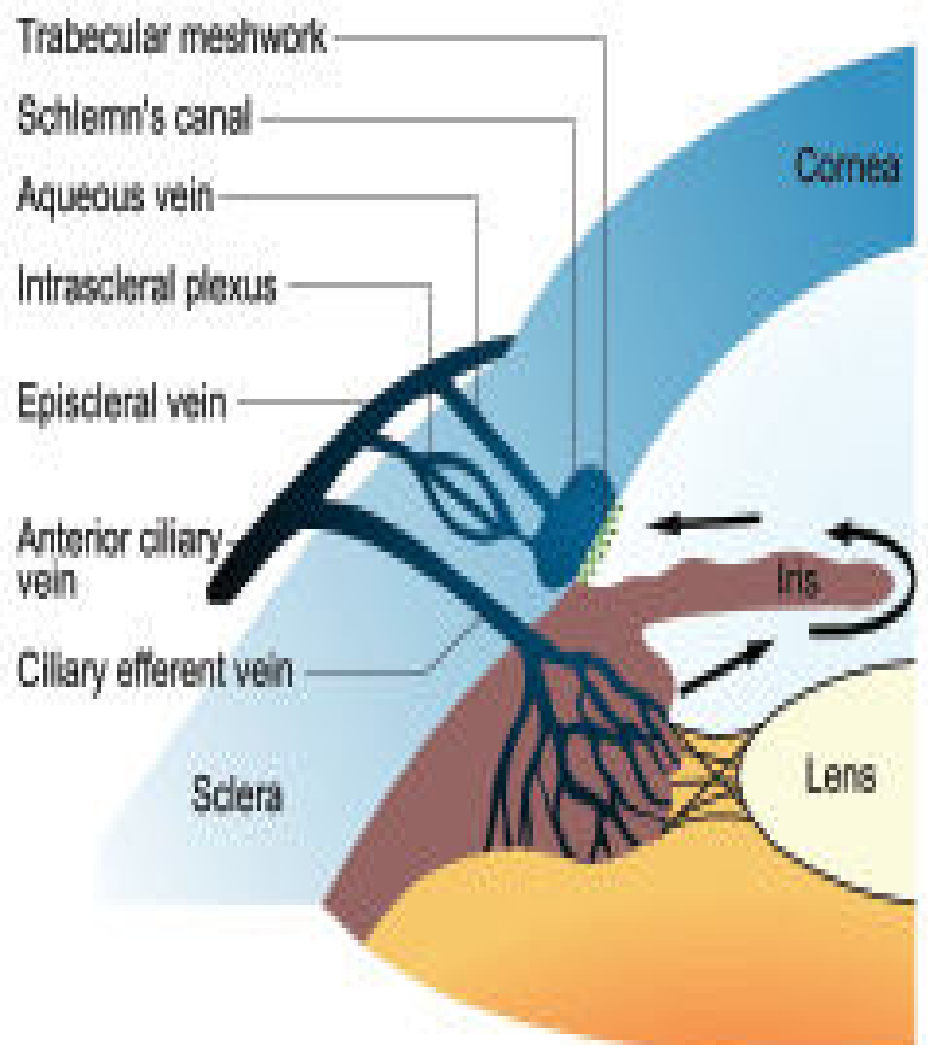
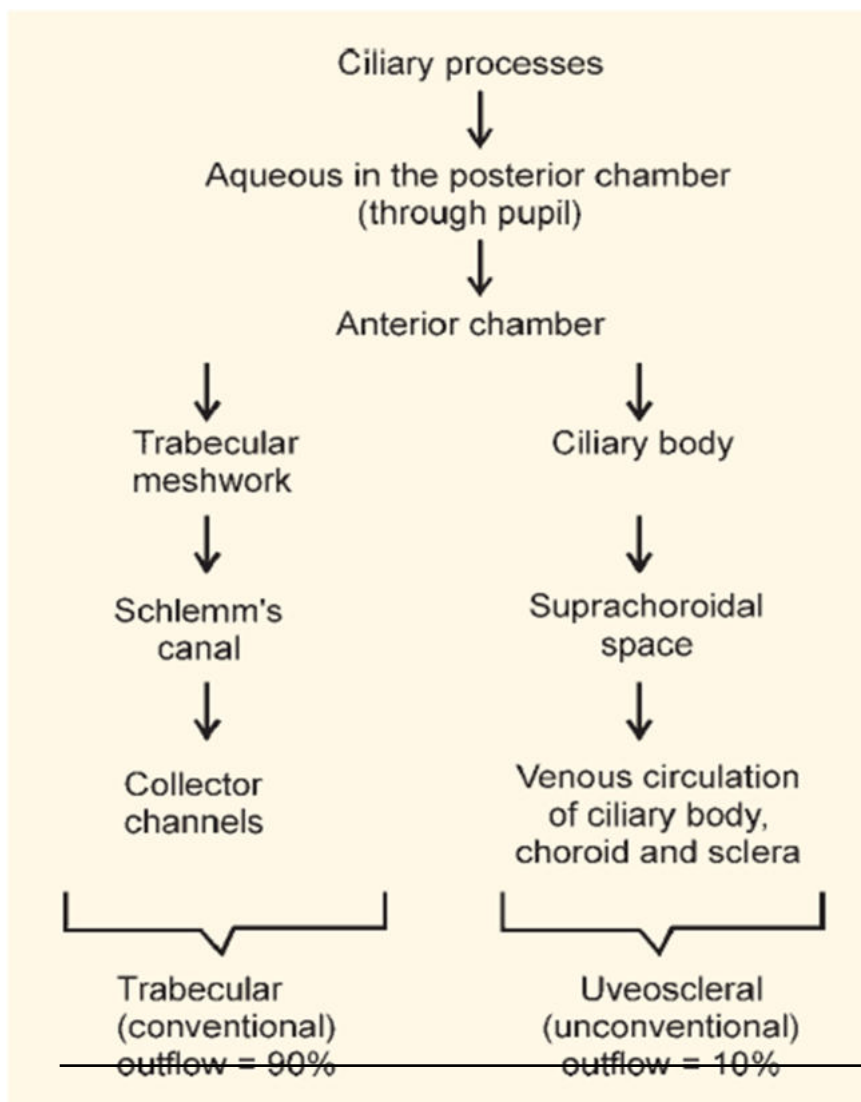
# ANGLE OF ANTERIOR CHAMBER

- STRUCTURES
  - Schwalbe's line
  - Trabecular meshwork
  - Scleral spur
  - Ciliary body band
  - Root of iris

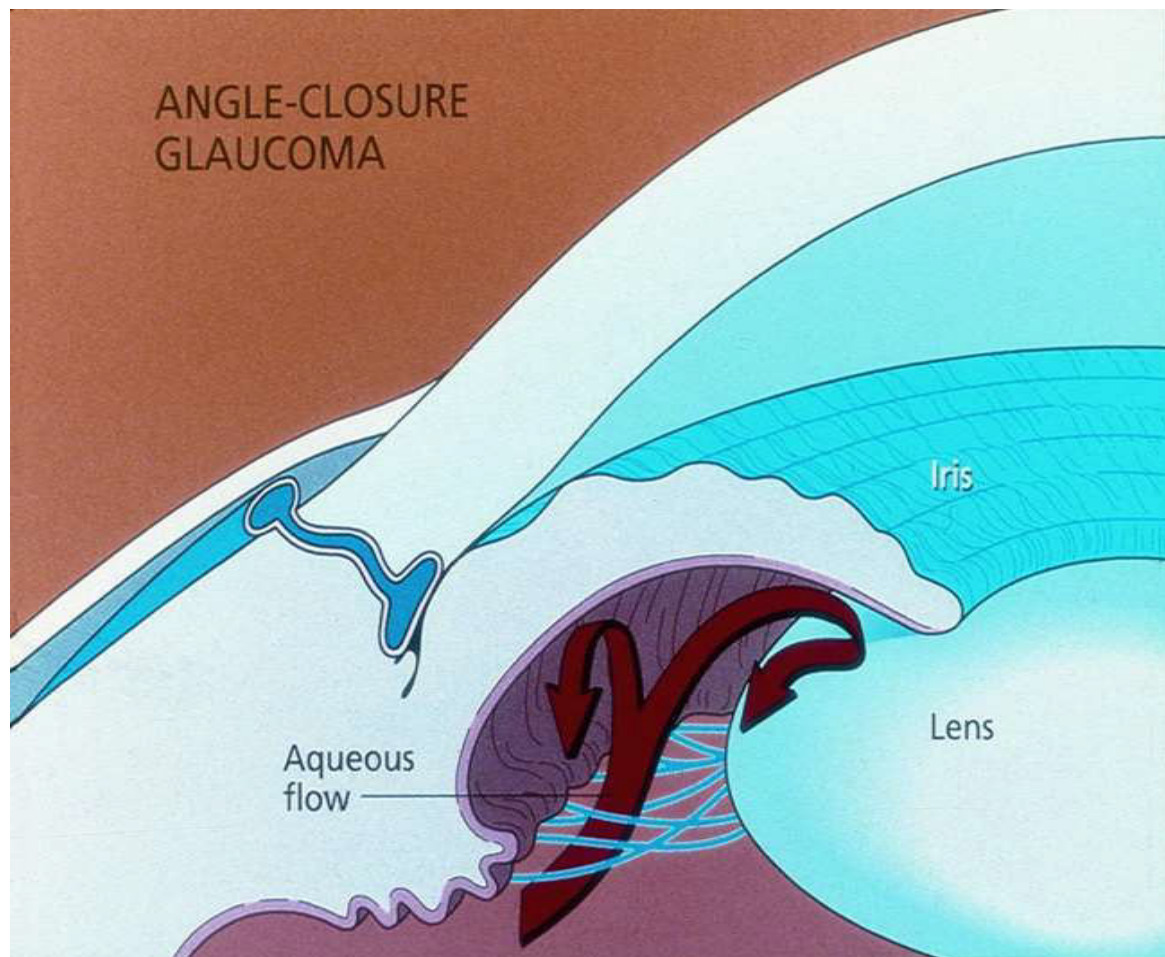


7

# DRAINAGE OF AQUEOUS HUMOR



8



9

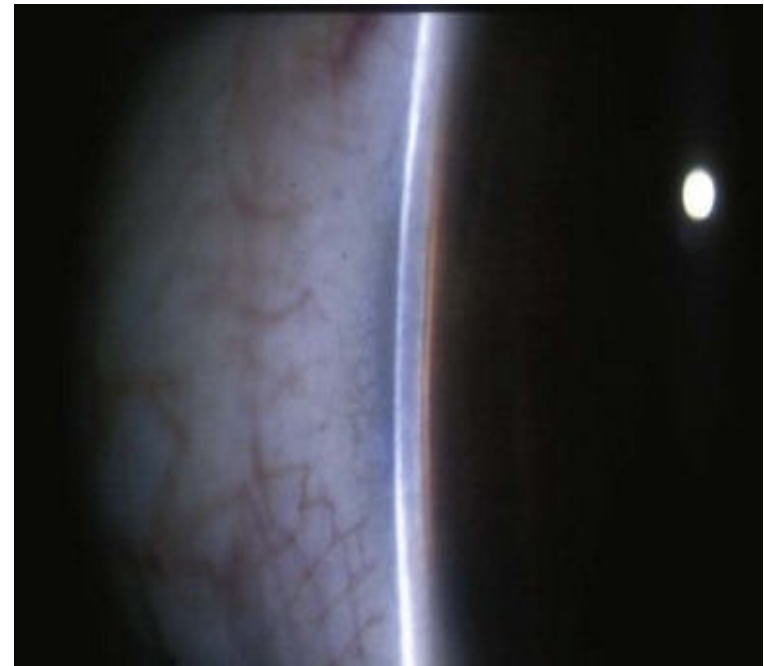
## PRIMARY ANGLE CLOSURE GLAUCOMA

### EPIDEMIOLOGY

- PACG is *the* major cause of glaucoma blindness worldwide.
- Age :- Average age at presentation 50-60 yrs
- Gender :- F > M, 4 : 1
- Race :- seen commonly in South-East Asian population, Chinese and Eskimos
- Heredity :- Mostly sporadic
- ~~Refractive error :- more common in hypermetropes~~

## Ocular risk factors

1. Shallow anterior chamber both centrally and peripherally.
2. Decreased anterior chamber volume.
3. Short axial length of the globe.
4. Small corneal diameter.



11

## Ocular risk factors

5. Decreased posterior corneal radius of curvature
6. Anterior position of the lens with respect to the ciliary body.
7. Increased curvature of the anterior surface & thickness of lens

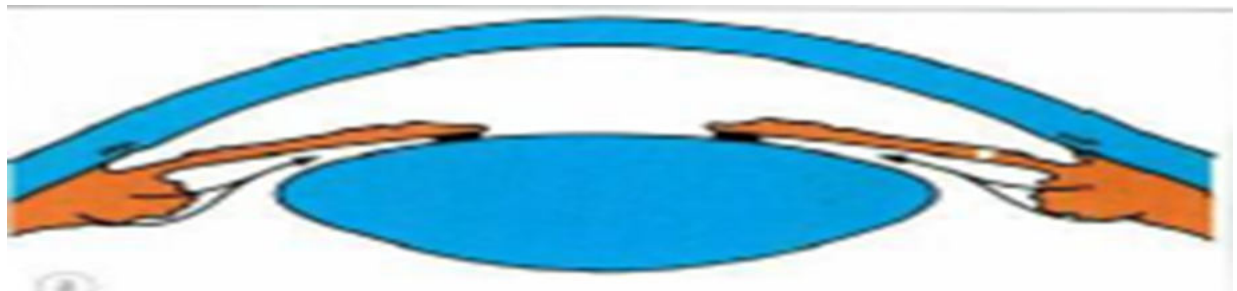


# PATHOGENESIS

- It is incompletely understood.
  - » a. Iris–pupil obstruction (e.g., ‘pupillary block’)
  - » b. Ciliary body anomalies (e.g., ‘plateau iris syndrome’)
  - » c. Lens–pupil block (e.g., ‘phacomorphic block’ (swollen lens or microspherophakia))

- **Relative Pupillary block**

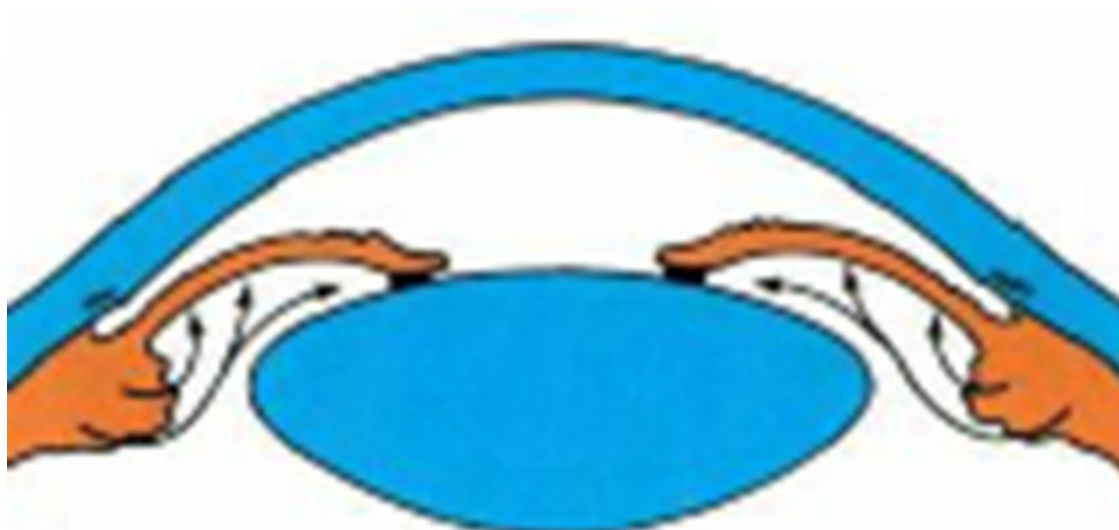
- Normally the pressure in the post. chamber exceeds that in the anterior chamber due to physiological degree of resistance at the pupil, since the iris rests posteriorly on the anterior lens capsule.



13

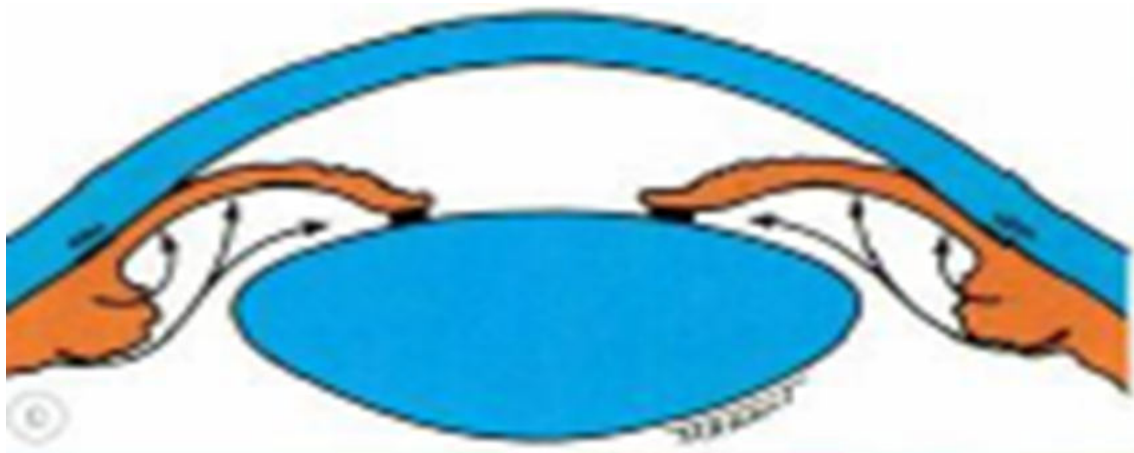
## Anterior Iris Bowing

Simultaneous dilatation of the pupil renders the peripheral iris more flaccid. The pupil block causes the pressure in the Posterior Chamber to increase & peripheral iris bows anteriorly



## Iridocorneal contact

Eventually the iris touches the posterior corneal surface, obstructing the angle and the IOP rises.



15

## Precipitating factors

### Factors that produce mydriasis

- Dim illumination
- Emotional stress(due to increased sympathetic tone)
- Drugs
  - **Mydriatic agents** :
    - cyclopentolate, tropicamide, atropine, homatropine.
  - **Antipsychotic agents**
    - » Phenothiazines: e.g., perphenazine ,fluphenazine
    - » Anticonvulsants e.g., Topiramate



- **Antidepressants**
  - » Tricyclic agents: amitriptylene , imipramine
  - » Non-tricyclic agents: fluoxetine
  
- **Antiparkinsonian agents** : Trihexyphenidryl
  
- **Antispasmodics** : Propantheline , Dicyclomine
  
- **Sympathomimetic agents** : Adrenaline (epinephrine), ephedrine, phenylephrine.

17

## CLASSIFICATION

### A. Primary angle-closure disease

- ***Irido-trabecular contact*** is the final common pathway of angle closure disease, ***obstructing aqueous outflow***

#### 1. New classification

Primary angle closure *suspect/PACS*

Primary angle *closure/PAC*

Primary angle-closure *glaucoma/PACG*

#### 2. Old classification

Angle closure suspect

Intermittent (sub acute) angle closure

Acute angle closure

Chronic angle closure

---

Absolute angle closure

# New classification of PACG

**❑ Primary angle closure suspect/PACS**

*Has occludable/narrow angles*

**❑ Primary angle closure/PAC**

*Has occludable/narrow angles +*

*High IOP/Peripheral anterior synechiae/*

*Excessive trabecular meshwork*

*pigmentation*

**❑ Primary angle-closure glaucoma/PACG**

**PAC+ Optic disc changes+ Visual field**

**defects**

## Gonioscopic grading of Angle closure

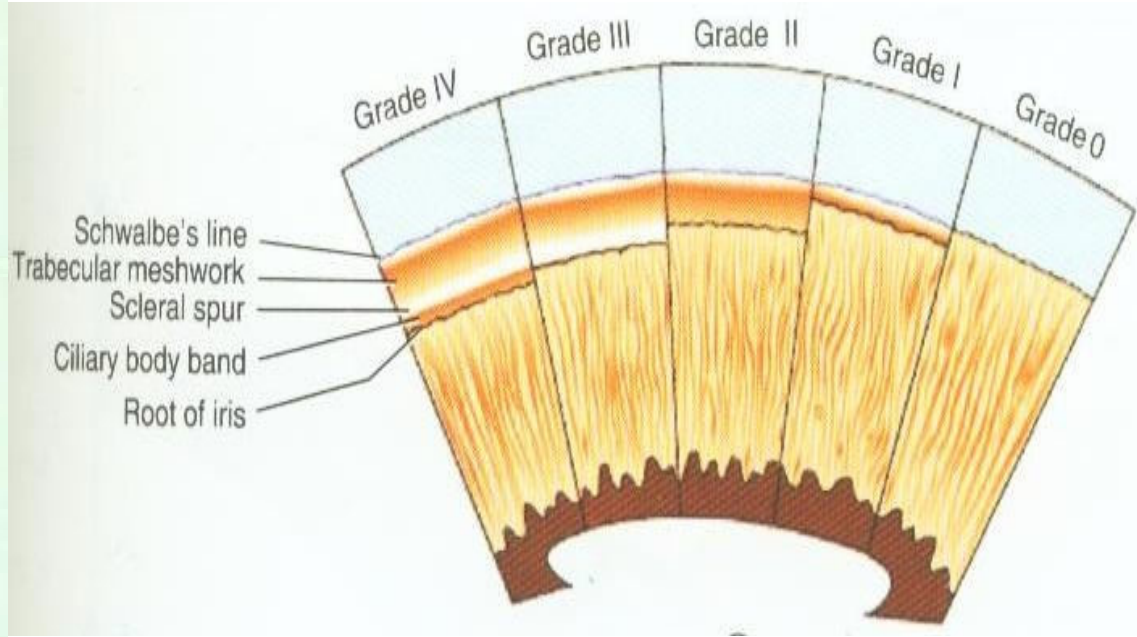
- Several grading systems :- Shaffer's, Spaeth's, Scheie's.
- Shaffer's grading

Grade	Angle width	configuration	Chances of closure	Structures visible
IV	35°-45°	Wide open	Nil	SL, TM, SS, CBB
III	20°-35°	Open angle	Nil	SL, TM, SS
II	20°	Moderately open	Possible	SL, TM
I	10°	Very narrow	Highly likely	SL only
0	0°	Closed	Closed	None

*Structures visible on gonioscopy*

**Grade**


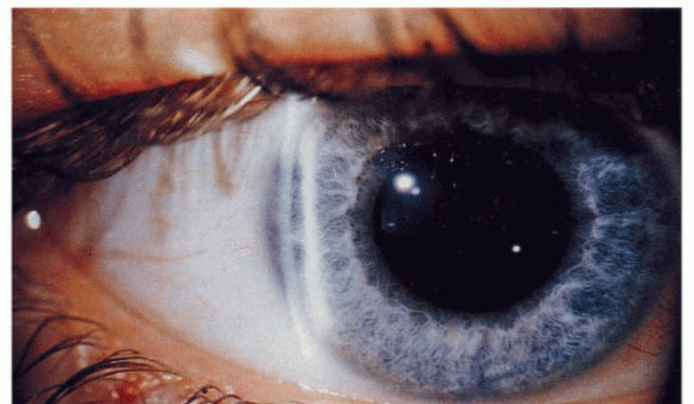
- IV From Schwalbe's line to ciliary body
- III - From Schwalbe's line to scleral spur
- II From Schwalbe's line to trabecular meshwork
- I Schwalbe's line only
- 0 None of the angle structures visible



## Van Herrick's grading

Angle	Depth
-------	-------

Grade 4 angle	Anterior chamber depth = Corneal thickness
Grade 3 angle	Anterior chamber depth = 1/4 to 1/2 corneal thickness
Grade 2 angle	Anterior chamber depth = 1/4 corneal thickness
Grade 1 angle	Anterior chamber depth = Less than 1/4 corneal thickness
Slit angle	Anterior chamber depth = Slit-like (extremely shallow)
Closed angle	Absent peripheral anterior chamber



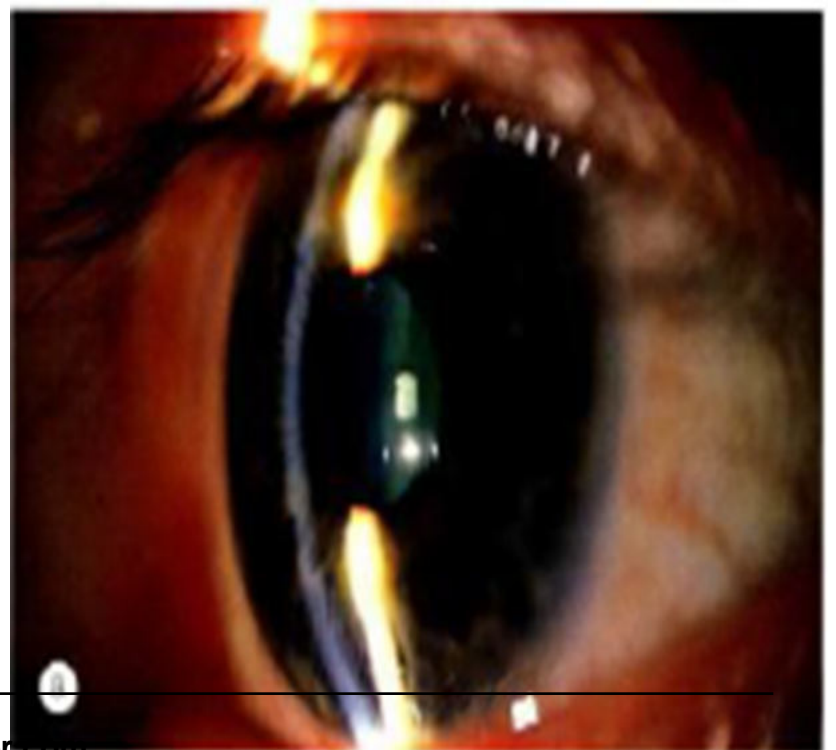
# Tests for Angle closure

- **Eclipse test** : uses flash light to make a rough assessment of angle depth
- Provocative tests for PAC suspects
- ✓ **Prone- darkroom test**: An increase in IOP of more than 8mm Hg after one hour suggests PAC
- **Fincham's Test**: Also known as stenopaeic-slit test. Glaucomatous halos remain intact , whereas halos due to cataract are broken up into segments

23

## PRIMARY ANGLE CLOSURE GLAUCOMA SUSPECT

- Also known as Latent PACG
- Essentially, the term implies an anatomically predisposed eye.
- Symptoms :- absent
- Signs :
  - Axial AC depth is < normal & iris lens diaphragm is convex
  - Close proximity of the iris to the cornea
  - Gonioscopy :- occludable angle(grade 1 or 0) without indentation in at least 3 quadrants.



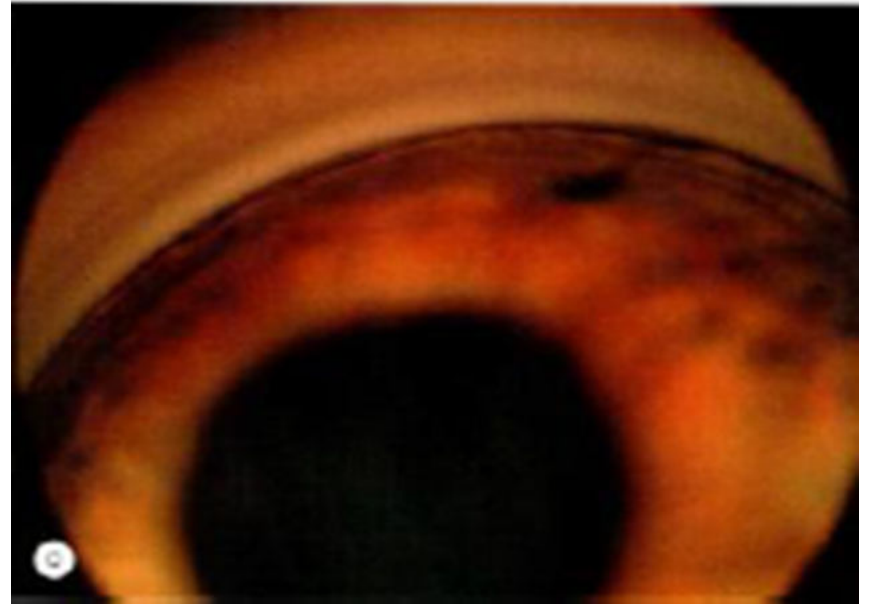
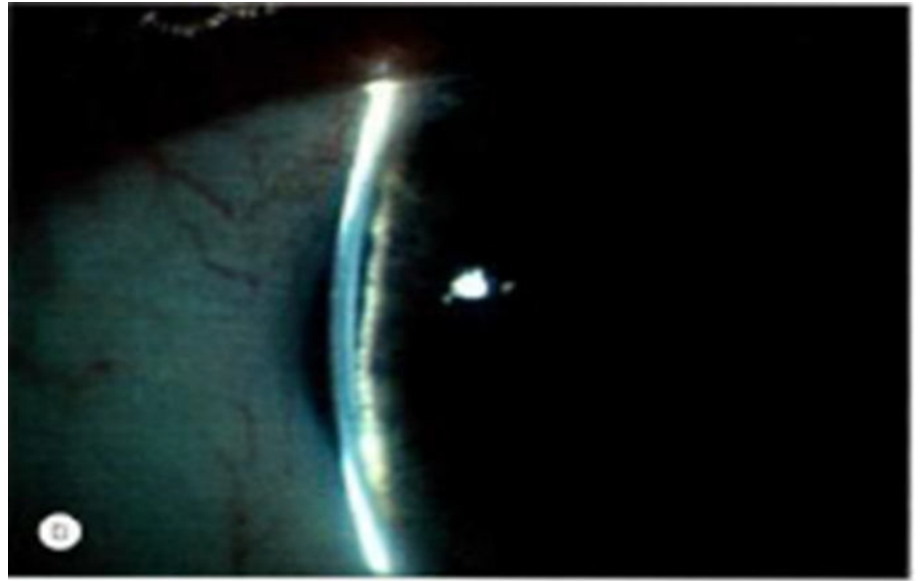


- Clinical course without treatment may be:

IOP may remain normal

Acute or sub acute angle closure may ensue

Chronic angle closure may develop, without acute or sub acute stages.



25

- Treatment

- Without treatment , risk of an acute pressure rise during the next 5 years is about 50 %.
- The need to treat is based on following criteria:-
  - If one eye has had acute or subacute angle closure, then fellow eye should undergo prophylactic peripheral laser iridotomy (Laser PI)
  - If both eyes have occludable angles, **laser PI** may be done

## INTERMITTENT(SUBACUTE)PRIMARY ANGLE CLOSURE GLAUCOMA

- A form of pupillary block glaucoma, which may not have any recognizable symptoms.
- Occurs in a predisposed eye with an occludable angle in association with intermittent pupillary block.
- Precipitating factors :- physiological mydriasis , or physiological shallowing of AC when patient assumes a prone or semi prone position ;emotional stress.

27

## INTERMITTENT(SUBACUTE)PRIMARY ANGLE CLOSURE GLAUCOMA

- Symptoms
  - Characteristic h/o transient blurring of vision with haloes around lights
  - Ocular discomfort or frontal headache
  - Attacks are recurrent and are usually broken after 1-2 hrs by physiological miosis.
- Signs
  - During an attack , eye is usually white
  - In between attacks, eye looks normal although the angle is narrow.



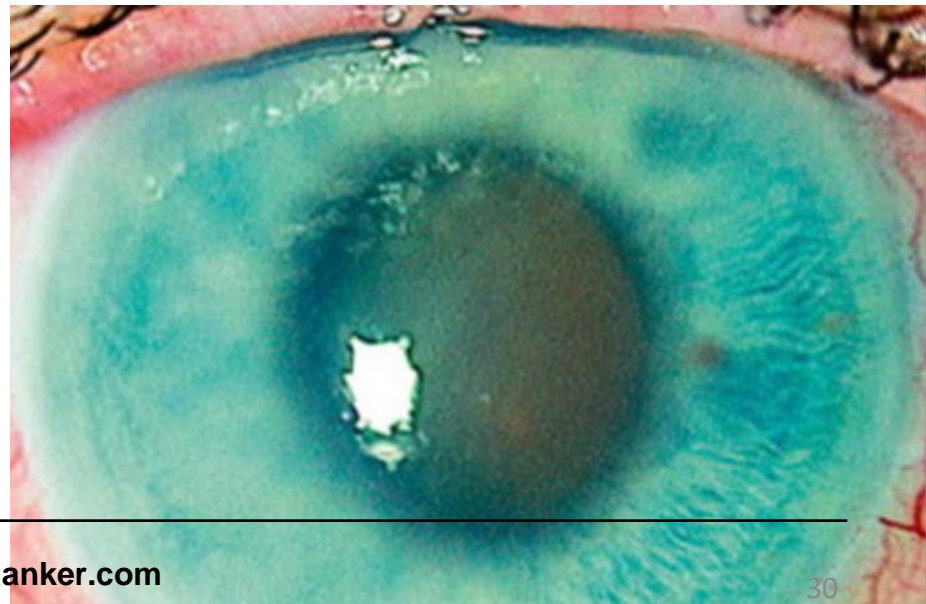
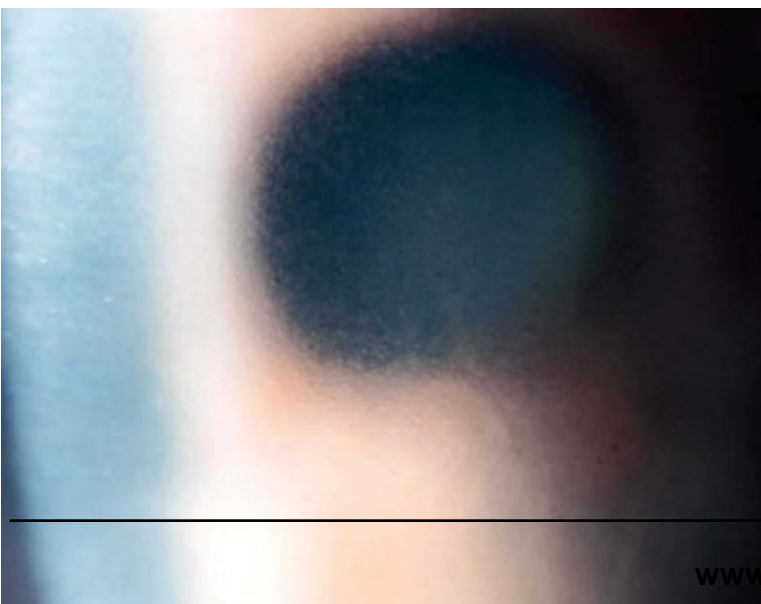
## INTERMITTENT(SUBACUTE)PRIMARY ANGLE CLOSURE GLAUCOMA

- Clinical course
  - Without treatment is variable
    - Some eyes develop an acute attack
    - Others chronic angle closure
- Treatment:- Prophylactic laser Peripheral Iridotomy(PI)

29

## ACUTE PRIMARY ANGLE CLOSURE GLAUCOMA

- Sight threatening emergency
- Painful loss of vision due to sudden and total closure of the angle.
- VA usually 6/60-Hand Movements.
- IOP is usually very high (40–70 mmHg).



## Findings during an acute attack of angle-closure glaucoma

- Two of the following symptom sets:
  - Periorbital or ocular pain
  - Diminished vision
  - Specific history of rainbow haloes with blurred vision
- IOP > 21 mmHg plus *three* of the following findings:
  - Ciliary flush (perilimbal conjunctival hyperemia)
  - Corneal edema (epithelial,stromal)
  - Shallow anterior chamber

31

## Findings during an acute attack of angle-closure glaucoma

- Anterior chamber cell and flare
- Mid-dilated ,vertically oval and sluggishly reactive pupil
- Closed angle on gonioscopy
- Hyperemic and swollen optic disc(due to decreased axoplasmic outflow)
- ~~Constricted visual fields~~

• **MANAGEMENT**

- Patient comfort ,lowering of the IOP and to break acute attack— main priorities.

- **A. Immediate medical treatment**

1. Patient should **lie supine** to allow the lens to shift posteriorly.

2. **Acetazolamide** 500 mg orally(if there is no vomiting).  
or **I.V Mannitol** 20% 1-2 g/kg over 1 hour (rule out contraindications)

3. **Topical**

Prednisolone or dexamethasone q.i.d (if AC reaction)

Timolol (if there is no contraindication).

4. Analgesia and emetics as required.

33

- **B. Subsequent medical treatment**

**Pilocarpine** 2% q.i.d. to the affected eye and 1% q.i.d. to the fellow eye.

Topical steroids (prednisolone 1% or dexamethasone 0.1%) q.i.d. if the eye is acutely inflamed.

**Timolol** 0.5% b.d.,

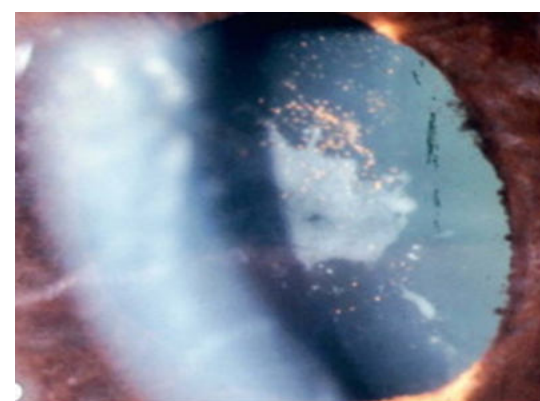
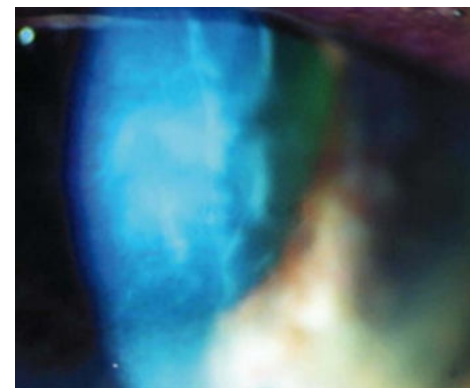
and oral acetazolamide 250 mg q.i.d. may be required.

- If the above measures fail:

- Laser iridotomy or iridoplasty after clearing corneal oedema with glycerol.

- Surgery in resistant cases.

- Findings suggestive of **previous episodes** of acute angle closure glaucoma
  - Fine **pigment** granules on corneal endothelium
  - Peripheral anterior **synechiae**
  - Posterior synechiae
  - **Glaucomflecken**
  - Sectoral/generalized **iris atrophy**
  - Fixed and semi **dilated pupil**



35

## Findings suggestive of **previous episodes** of acute angle closure glaucoma

- Optic nerve cupping &/or pallor
- Gonioscopy shows narrow angle or PAS
- Visual field loss

# Chronic angle closure glaucoma

- Visual Acuity is normal unless damage is advanced.
- Anterior chamber is shallower in pupillary block than non-pupillary block.
- Optic nerve signs depend on severity of damage.
- IOP elevation may be only intermittent.
- **Gonioscopic abnormalities-**  
Peripheral Anterior Synechiae, narrow angle, pigmentation of Schwalbe's line.

37

## Treatment of chronic angle closure

- Medical treatment is similar to that of POAG
- **Prostaglandin/Prostamides**  
Latanoprost, Bimatoprost, Travoprost
- **Beta blockers**  
Timolol maleate, Betaxolol
- **Carbonic anhydrase inhibitors**  
Dorzolamide, Brinzolamide

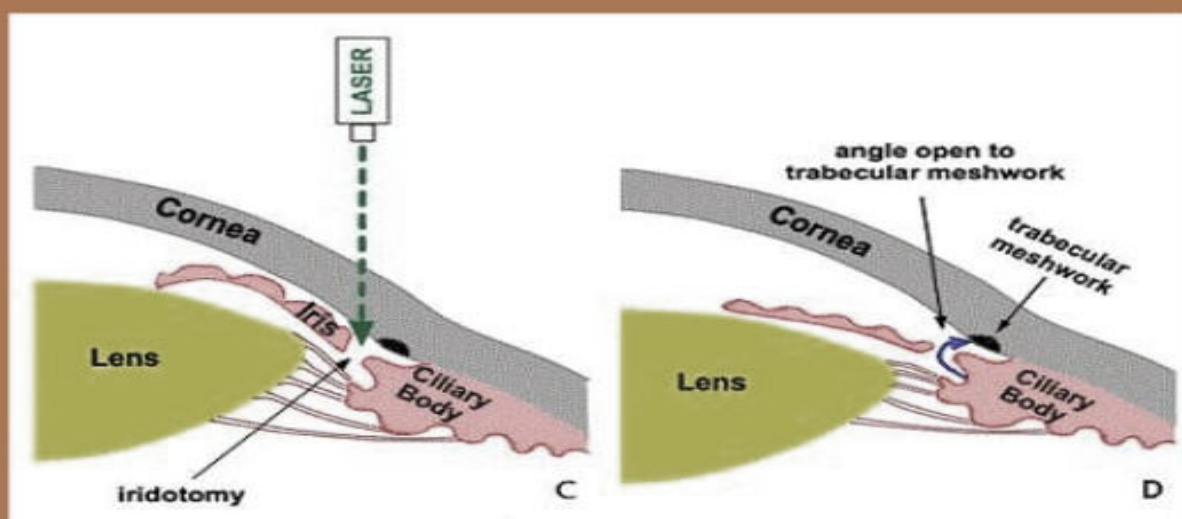
# Treatment of chronic angle closure

- Sympathomimetics  
Brimonidine, Apraclonidine
- Parasympathomimetics  
Pilocarpine
- Oral carbonic anhydrase inhibitors  
Acetazolamide, Methazolamide

39

# Treatment of chronic angle closure

- Laser Peripheral Iridotomy (PI) in affected eye along with Prophylactic PI in fellow eye



40



# Laser Peripheral Iridotomy

- Complications of laser therapy

1. Bleeding
2. IOP elevation
3. Iritis
4. Corneal burns
5. Lens opacities
6. Glare and diplopia

41

- Surgical treatment

**Trabeculectomy** (filtering surgery) is the surgical procedure of choice

- Success:- 87- 100 % with multiple operations

- Complications:-

- Flat AC, hypotony
- Bleb related infections
- Cyclodialysis

- PATIENTS REQUIRE REGULAR AND LIFE LONG FOLLOW UP

# Absolute glaucoma

- Is the **final/last stage of PACG**
- Clinical features:
  - Painful blind eye
  - Perilimbal reddish blue zone, due to dilated anterior ciliary veins
  - Cornea gradually becomes hazy, insensitive with bullous keratopathy
  - Anterior chamber is very shallow/flat

43

## Clinical features of absolute glaucoma

- Iris is usually atrophic
- Pupil is fixed and dilated
- Glaucomatous optic atrophy of the optic disc
- High IOP

# Management of absolute glaucoma

- **Cycloablation**/destruction of the secretory ciliary epithelium
  - Cyclophotocoagulation
  - Cyclocryotherapy
  - Cyclodiathermy
- Rarely
- Retrobulbar alcohol injection
- Enucleation of eyeball

45

## Complications

- Corneal ulceration
- Staphyloma formation (Ciliary/Equatorial)
- Atrophic bulbi (Shrunken eye)

# Conclusion

- Primary angle closure glaucoma is a **potentially sight threatening** condition, characterized by occludable anterior chamber angles.
- **Obstruction of aqueous outflow** results in rise of intra ocular pressure, optic nerve damage and visual field defects.
- Management may include medical, laser and/or surgical modalities.

47

# Question

- Primary angle closure glaucoma occurs most commonly in patients with shallow anterior chambers. Among the following, which does NOT contribute to a shallow anterior chamber?
  - A) Mature lens
  - B) Hyperopia
  - C) Ocular hypertension
  - D) Iris bombé

# Question

- **With respect to angle-closure glaucoma, which of the following is true?**
- **a.** Men are at increased risk.
- **b.** The anterior chamber depth increases with age, predisposing to pupillary-block- induced angle-closure glaucoma.
- **c.** Primary angle-closure glaucoma may occur in eyes with any type of refractive error.
- **d.** Family history, while important in open-angle glaucoma, does not play a role in angle-closure glaucoma.