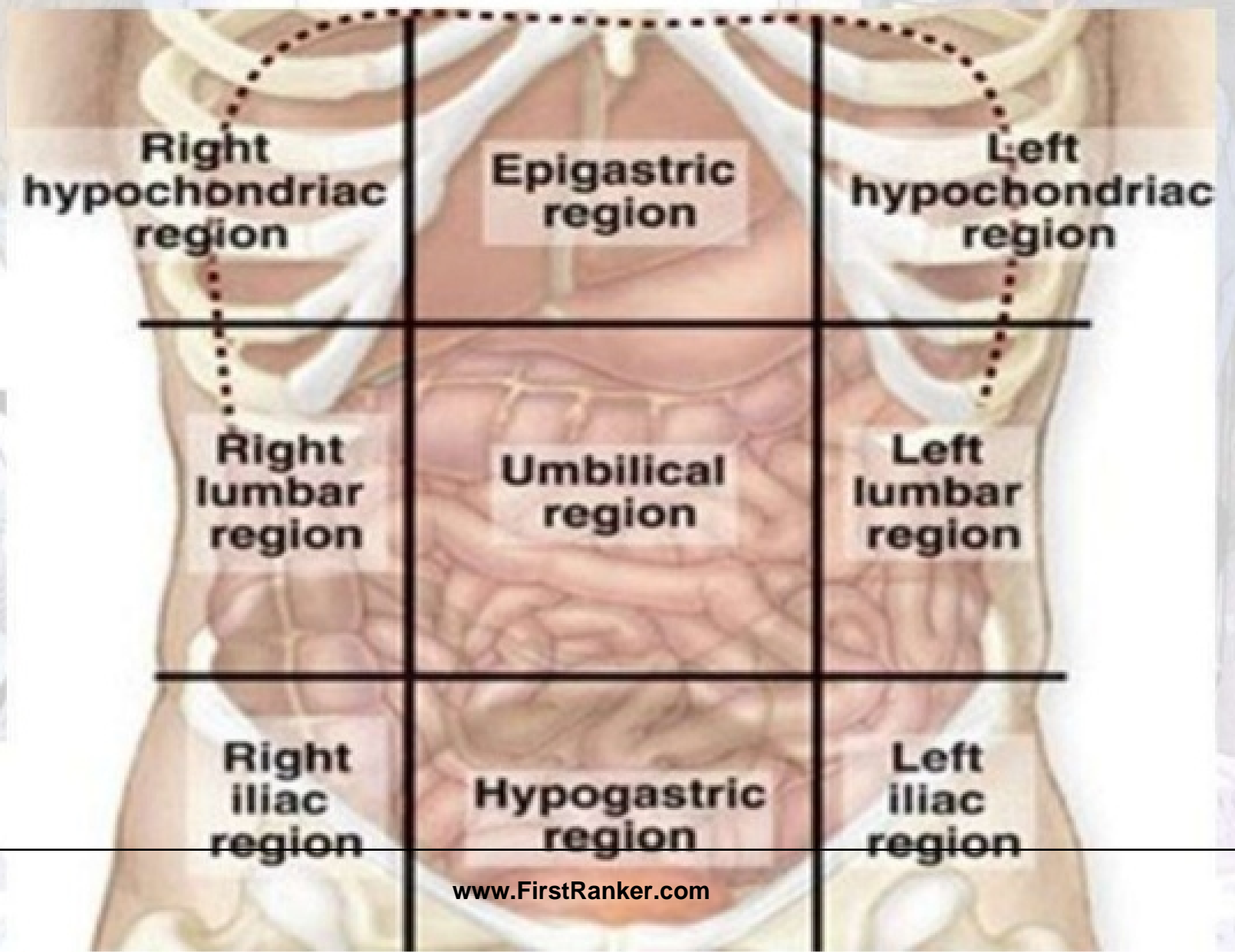


APPROACH TO A PT OF RT HYPOCHONDRIAL LUMP

Regions of Abdomen



-
- HISTORY
 - PHYSICAL EXAMINATION
 - INVESTIGATIONS
 - PROCEDURE LIKE EXPLORATION
 - HISTOPATHOLOGY

HISTORY

- AGE
 - SEX
 - PAIN
 - VOMITINGS
 - MOTIONS
 - URINATION
 - FEVER
-

PHYSICAL EXAMINATION

- GENERAL
- SYSTEMIC
- LOCAL

GENERAL PHYSICAL EXAM

- APPEARANCE
 - EMACIATED
 - ANAEMIC
 - JAUNDICED
 - LYMPH NODES
-

ABDOMINAL EXAMINATION

- INSPECTION
- PALPATION
- PERCUSSION
- AUSCULTATION

INSPECTION

- ABDOMINAL DISTENTION
- VISIBLE PERISTALSIS
- OVERLYING SKIN
- POSITION, SIZE, SURFACE OF SWELLING
- MOBILITY WITH RESPIRATION
- HERNIA SITES
- SCROTUM

PALPATION

- SOFT OR RIGID
- TENDERNESS

PALPATION OF LUMP

- LOCAL TEMPERATURE
- TENDERNESS
- CONFIRMING FINDINGS OF INSPECTION
- MARGINS
- CONSISTENCY
- MOBILITY
- PARIETAL, INTRA OR RETROPERITONEAL

PERCUSSION

- DULL OR RESONANT
- FLUID THRILL

AUSCULTATION

- FOR RUB{ PERSPLENITIS OR PERIHEPATITIS}

INVESTIGATIONS

- LABORATORY STUDIES-
ROUTINE,SPECIAL
- IMAGING STUDIES
- TISSUE DIAGNOSIS-CYTOLOGY,HPE

IMAGING STUDIES

- X-RAY
- USG
- CT
- MRI
- ERCP
- NUCLEAR SCAN
- PET

OTHER STUDIES

- ENDOSCOPY
- ENDOSONOGRAPHY(EUS)

DIFFERENTIAL DIAGNOSIS

- SWELLINGS IN ABDOMINAL WALL
 - SEBACEOUS CYST
 - LIPOMA
 - PARIETAL WALL ABSCESS

INTRAABDOMINAL LUMP

- HEPATIC
- GALL BLADDER
- SUBPHRENIC ABSCESS
- STOMACH AND DUODENUM
- HEPATIC FLEXURE OF COLON
- RT KIDNEY
- RT SUPRARENAL

HEPATIC

- IT MOVES WITH RESPIRATION, NOT SIDEWAYS
- CONTINUOUS WITH LIVER DULLNESS WITHOUT A BAND OF COLONIC RESONANCE

HEPATIC

- ALA
- PYOGENIC ABSCESS
- RIEDEL'S LOBE
- HYDATID CYST
- HEPATOMA
- SECONDRIES
- CIRRHOSIS

SUBPHRENIC ABSCESS

- PAIN RHC REFFERED TO SHOULDER
- TENDERNESS RHC
- SIGNS OF SEPTICAEMIA
- RAISED DIAPHRAGM WITH GAS ON XRAY
- CAUSATIVE CONDITIONS
 - LIVER ABSCESS
 - PERFORATED PEPTIC ULCER

GB LUMP

- OVAL, SMOOTH SWELLING, SIZE OF AN EGG
- MOVES WITH RESPIRATION

GB LUMP

- CA GALL BLADDER
- CA HEAD OF PANCREAS
- CHOLEDOCHAL CYST
- MUCOCOEL

STOMACH AND DUODENUM

- CA STOMACH
- CONGENITAL HYPERTROPHIC PYLORIC STENOSIS
- SUBACUTE PERFORATION OF PEPTIC ULCER

CA STOMACH

- IRREGULAR FIRM LUMP
- MOVES WITH RESPIRATION
- ELDERLY, ANOREXIA AND WT LOSS
- BARIUM MEAL—FILLING DEFECT
- UPPER GI ENDOSCOPY

SUBACUTE PERFORATION OF ULCER

- LOCALIZED TENDERNESS
- INFLAMMATORY MASS
- HISTORY OF PEPTIC ULCER
- BARIUM MEAL

HEPATIC FLEXURE

- PT ABOVE 40 YEARS
- CHANGES IN BOWEL HABITS
- OCCULT BLOOD
- ANAEMIA
- LUMP-IRREGULAR, MOVES POORLY
WITH RESPIRATION
- COLONOSCOPY

INTUSSUSCEPTION

- ABDOMINAL PAIN, VOMITINGS
- PASSAGE OF BLOOD AND MUCUS PER ANUM (RED CURRANT JELLY)
- CURVED, SAUSAGE SHAPED LUMP
- BARIUM ENEMA—PINCER ENDING OF RADIOGRAPHIC MATERIAL

KIDNEY SWELLING

- BALLOTABLE
- RENAL ANGLE IS FULL
- SLIGHT MOVEMENT WITH RESPIRATION
- PERCUSSION-RESONANT

KIDNEY SWELLING

- HYDRONEPHROSIS/PYONEPHROSIS
- CARCINOMA
- NEPHROBLASTOMA/WILMS TOMOUR

SUPRARENAL SWELLING

- LIKE KIDNEY SWELLING
- CORTEX/ MEDULLA

ADRENAL CORTEX

- HYPERPLASIA
- BENIGN ADENOMA
- CARCINOMA

ADRENAL MEDULLA

- PHEOCHROMOCYTOMA
- NEUROMA
- NEUROBLASTOMA