

GRANULOMAS OF UNSUSPECTED AETIOLOGY

WEGENER'S GRANULAMATOSIS

AETIOLOGY

- Systemic d/o of unknown etiology
- Involves URT, Lungs, kidney, skin

CLINICAL FEATURES

- Clear or blood stained nasal d/c
- Later become purulent

Nasal findings: crusting

- Granulations

- Septal perforations
- Saddle nose
- General symptoms : anaemia, fatigue, night sweats, migratory arthralgia
- Lung involvement
- Renal failure
- Biopsy done for diagnosis

TREATMENT

Systemic steroids, cytotoxic drugs

Cyclophosphamide and azathioprine

T CELL LYMPHOMA

- Destructive lesion ,starting on one side
- Involves upper lip, oral cavity ,maxilla,orbit
- Polymorphic lymphoid tissue with angiocentric & angioinvasive features
- No vasculitis
- Rapidly destructive, no systemic involvement
- Diagnosis by biopsy
- **TREATMENT : radio and chemo therapy**

SARCOIDOSIS

- Unknown aetiology
- Systemic d/o ;involvement of lungs, lymph nodes ,eyes, skin
- Present with submucosal nodulesinvolving septum or inf. Turbinate with nasal obstrn, pain & epistaxis
- X ray show diffuse pulmo. Infiltrate with hilar adenopathy

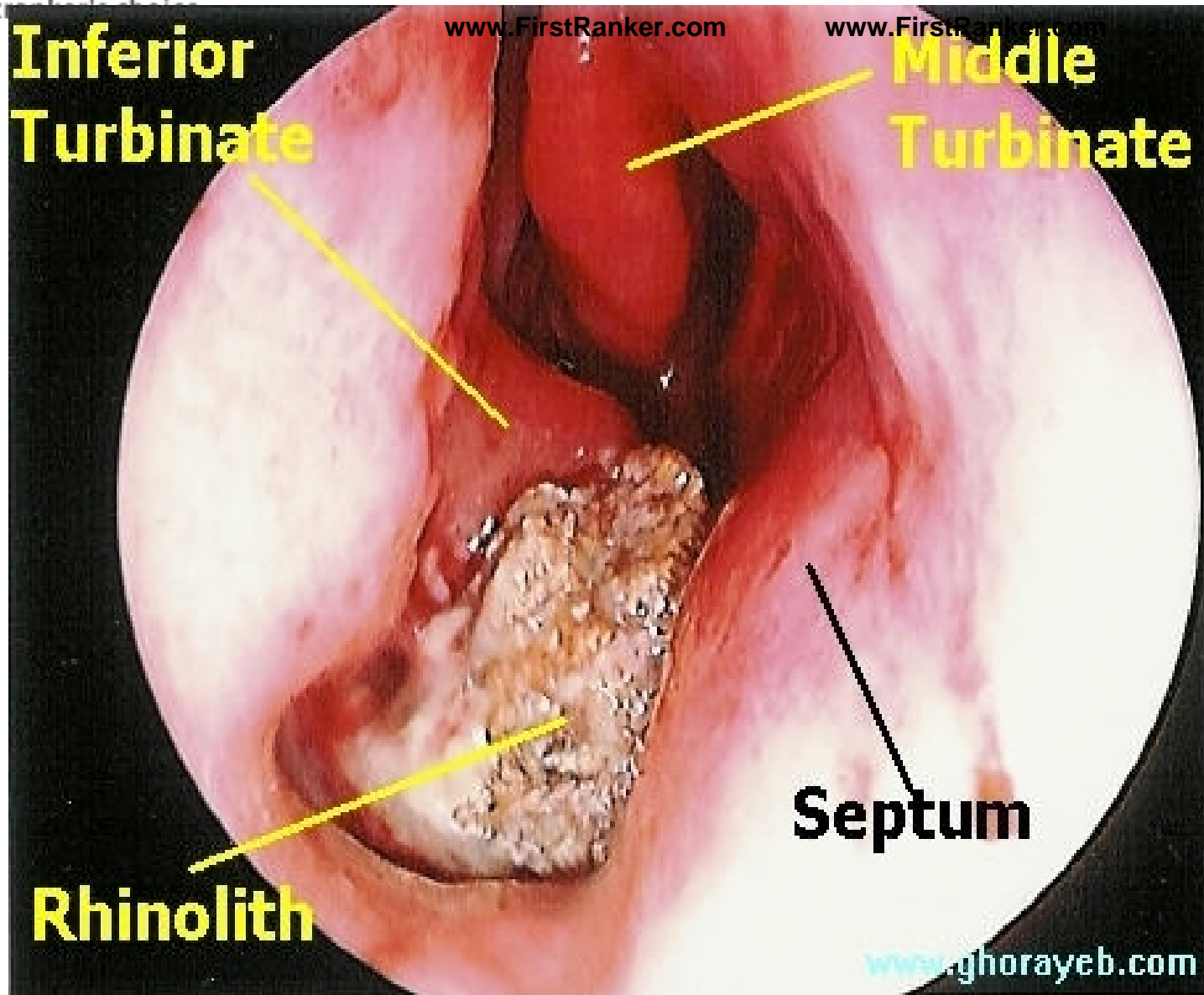
- Serum & urinary Ca elevated
- Diagnosis with biopsy

TREATMENT

- Systemic steroids
- Steroids in form of nasal spray

RHINOLITH

- Stone formation of nasal cavity
- Usually around nucleus of small exogenous foreign body, blood clot, inspissated depositions of Ca & Mg salts
- Grows into large , irregular mass
- Cause pressure necrosis of septum & lateral wall
- TREATMENT: removed under GA
- Most of them removed via ante. Nares
- Hard, irregular ones need late. rhinotomy



NASAL MYIASIS(Maggots in nose)

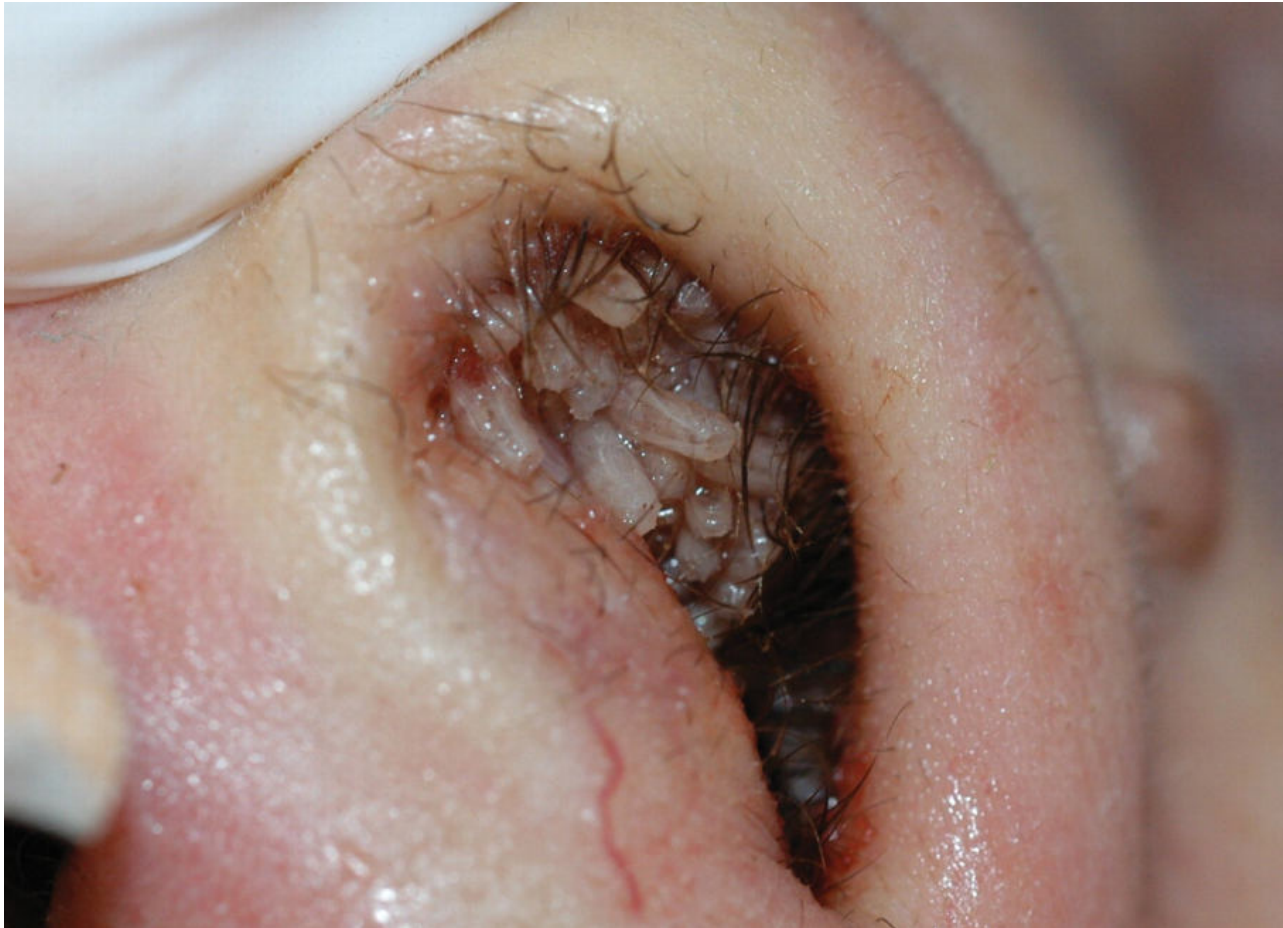- Maggots seen to infest nose ,
nasopharynx, paranasal sinuses
- Flies(genus: chrysomyia) attracted to foul
smelling d/c emanating from atrophic
rhinitis, syphilis, leprosy infected wounds

CLINICAL FEATURES

- First 3-4 days maggots cause irritation, sneezing, lacrimation & headache
- Thin bloodstained d/c
- Eyelids & lips become puffy
- 3rd or 4th day maggots crawl out of nose
- Foul smell around the patient
- Cause destrn. Of nose, sinuses, soft tissue of face, palate, eyeball
- Fistula in palate or around nose
- Death occur from meningitis

TREATMENT

- All visible maggots should be picked up with forceps
- Instillation of chloroform water& oil kills them
- Nasal douche with warm saline to remove slough, crusts, dead maggots
- Patient isolated with mosquito net



THANK YOU