

MASS LESION

Pulmonary, pleural or mediastinal lesions on the chest radiograph as an opacity greater than 3 cm in diameter.

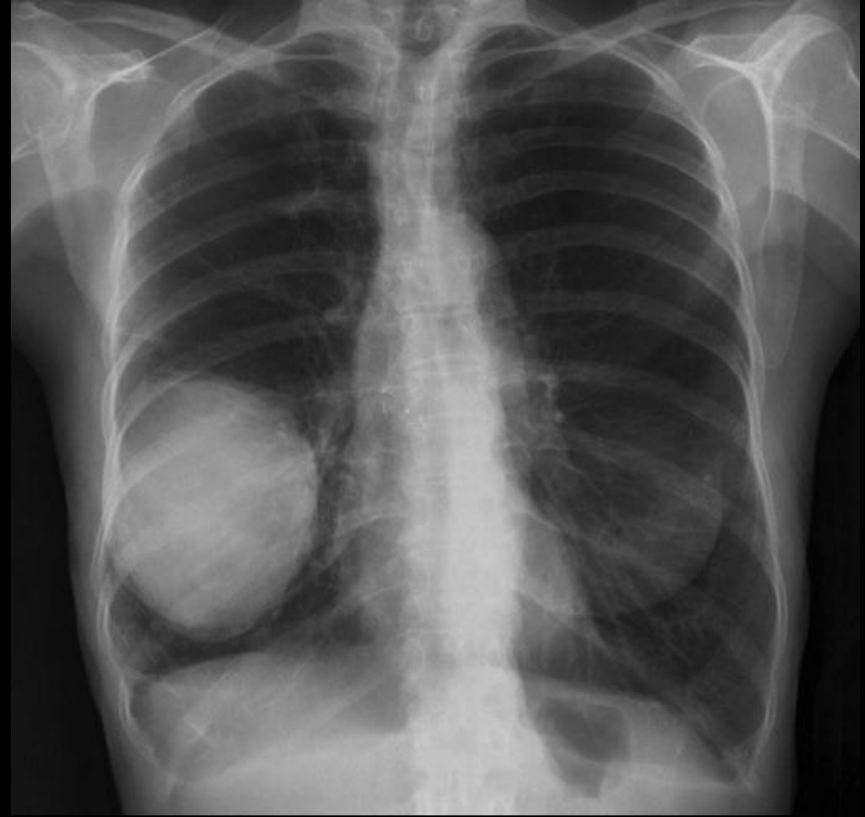Symptoms and Signs

- *Local - Cough, chest pain, dyspnea, hemoptysis*
- *Bronchial obstruction - bronchopneumonia, lung abscess, bronchiectasis*
- *Due to metastasis - SVC syndrome, painful bony lesion ???????*
- *Paraneoplastic syndrome (Small cell ca) -*
 - *Ectopic hormone production*
 - *Others - neuromuscular, skeletal*
 - *Cutaneous*
 - *Hematological*

CHRONIC CARCINOMA

www.FirstR

- Age - higher, sex - males, smokers
- Clubbing
- Cervical lymphadenopathy
- Emaciation (weight loss)
- Usually no mediastinal shifting unless complicated by pleural effusion
- Localized crepitation over mass



www.FirstR

Cavity lesion

www.FirstRanker.com

www.FirstRanker.com

Gas filled space within the lung that may or may not contain fluid level and is surrounded by a wall of varies thickness

Signs

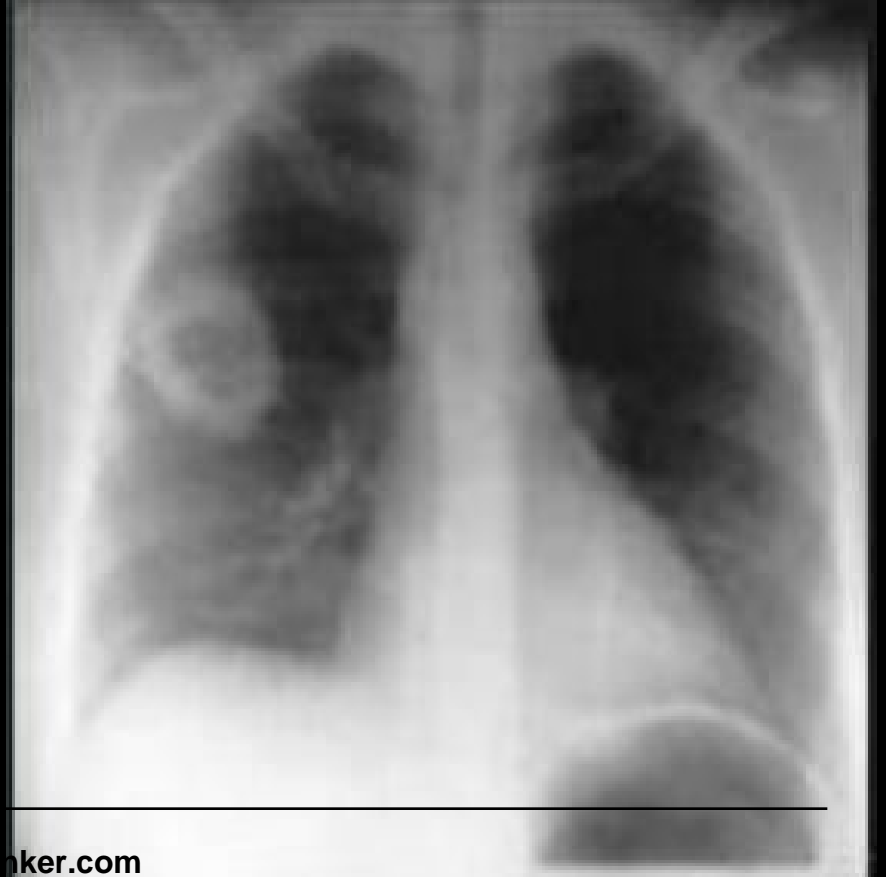
Post tussive crepitation

Post tussive suction (high pitched sucking sound audible during phases of long inspiration following a bout of cough) - Hallmark sign of a **thin walled superficial, compressible cavity connected with patent bronchus**.

Cracked pot sound by percussion over empty communicating cavity

Radiology

- Wall thickness
- Characteristics of inner contour
- Internal content
- Number and locations



Differential Diagnosis

- Neoplasm
- Infection - bacterial, fungal, parasitic
- Pulmonary infarct
- Septic emboli
- Auto immune (wegner's granulomatosis, rheumatoid arthritis)
- Traumatic
- Congenital

Lung abscess

Localized area of suppurative necrosis within pulmonary parenchyma resulting in formation of one or more lung cavities

Causative organisms (Staphylococcus n Streptococcus) is introduced to the lung by

- Aspiration
- Complications of necrotizing bacterial infection
- Distal to bronchial obstruction
- Septic embolism
- Hematogenous spread

It is commonly seen in the right lung (upper part of lower lobe and lower part of upper lobe)

Symptoms and signs

Cough with copious amount of foul smelling purulent sputum

Clubbing

Fever, malaise

Loss of weight

Radiology

Irregularly shaped cavity with
an air-fluid level

