

COLLES' FRACTURE

FIRST DESCRIBED BY

ABRAHAM COLLES IN 1814

DEFINITION

www.FirstRanker.com

www.FirstRanker.com

FRACTURE AT THE DISTAL END OF RADIUS

AT ITS CORTICO-CANCELLOUS JUNCTION

ABOUT 2 CM FROM THE DISTAL ARTICULAR

SURFACE OCCURRING IN OSTEOPOROTIC BONE.

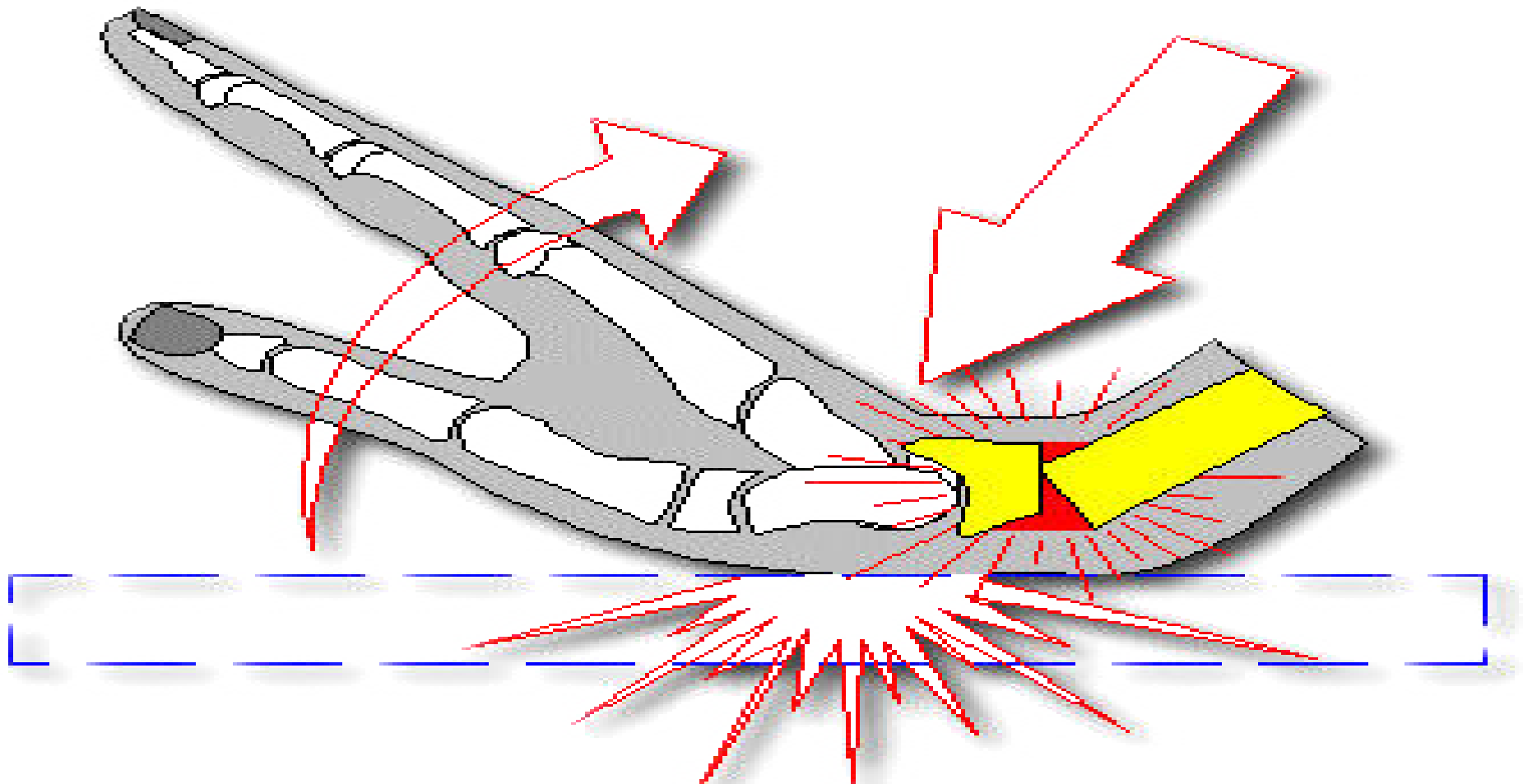
MECHANISM OF INJURY

FALL ON AN OUTSTRETCHED HAND WITH

www.FirstRanker.com

www.FirstRanker.com

DORSIFLEXION RANGING FROM 40° TO 90°



PATHOANATOMY

DISPLACEMENTS

- ◆ **IMPACTION OF FRAGMENTS**
- ◆ **DORSAL DISPLACEMENT**
- ◆ **DORSAL TILT**
- ◆ **LATERAL DISPLACEMENT**
- ◆ **LATERAL TILT**
- ◆ **SUPINATION**

- **FRACTURE OF STYLOID PROCESS OF ULNA**
- **RUPTURE OF ULNAR COLLATERAL LIGAMENT**
- **RUPTURE OF TRIANGULAR CARTILAGE OF ULNA**
- **RUPTURE OF INTEROSSEOUS RADIOULNAR LIGAMENT PRODUCING RADIOULNAR DISLOCATION**

SYMPTOMS

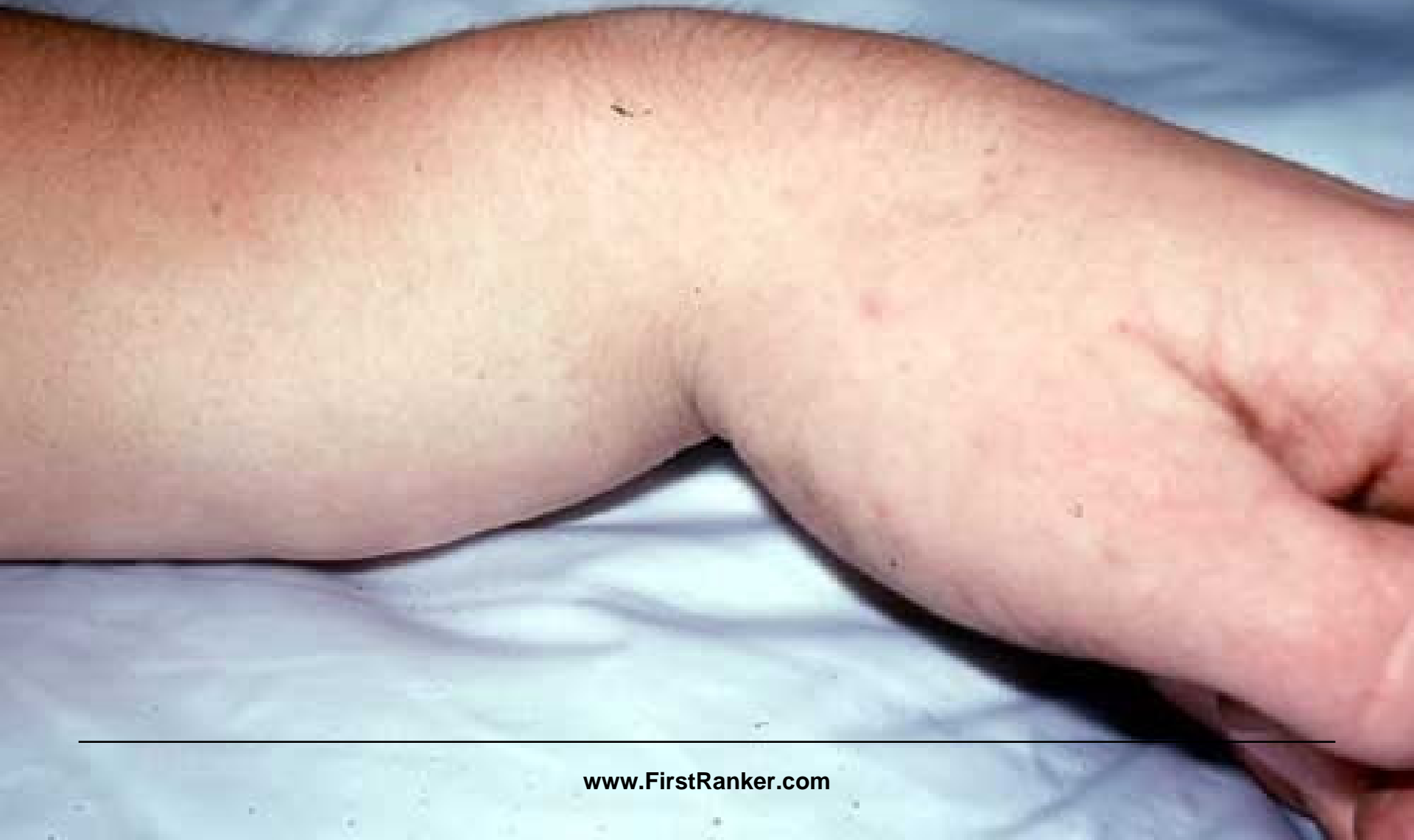★ PAIN

★ SWELLING

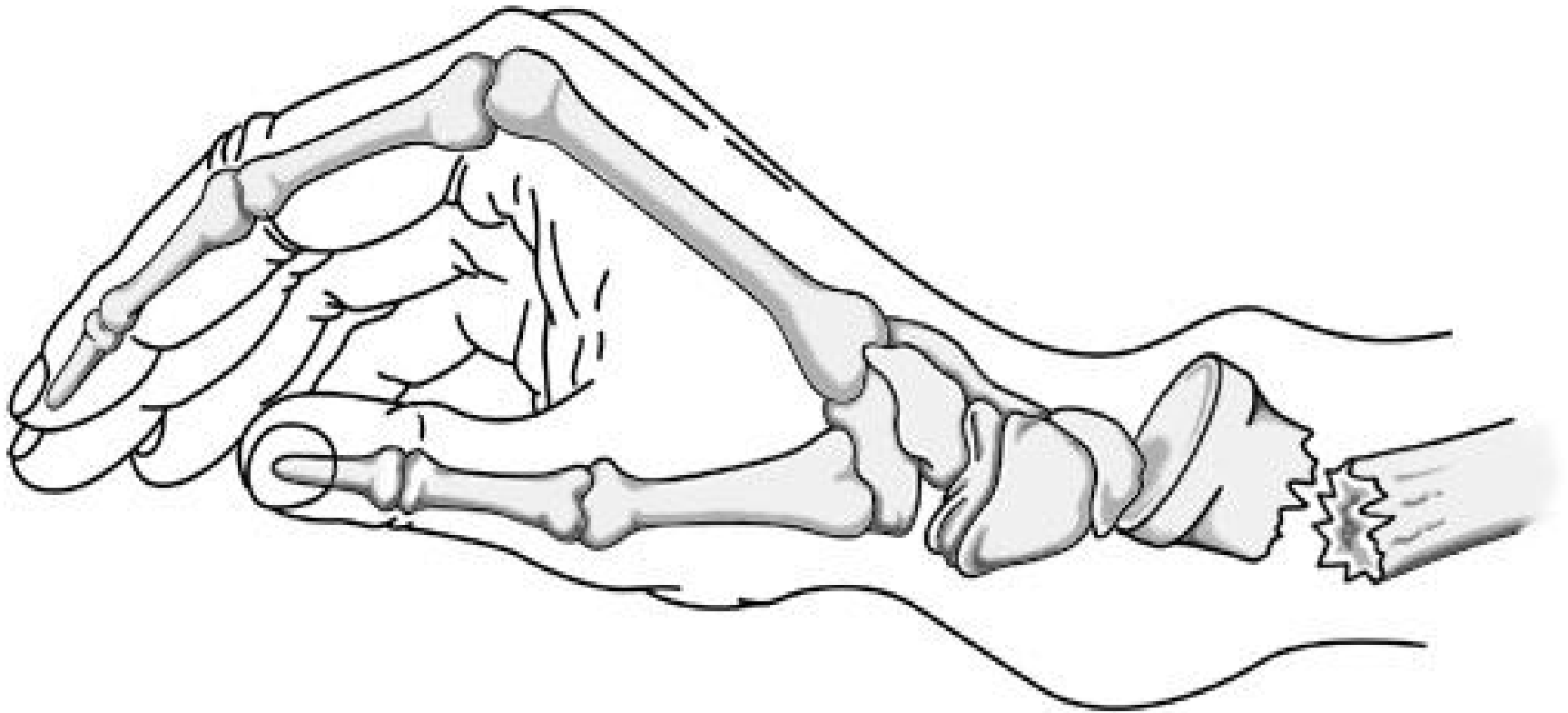★ DEFORMITY

- **TENDERNESS**
- **IRREGULARITY OF LOWER END OF RADIUS**
- **DINNER FORK DEFORMITY**
- **ULNAR & RADIAL STYLOID AT THE SAME LEVEL**

DINNER FORK DEFORMITY



DINNER FORK DEFORMITY

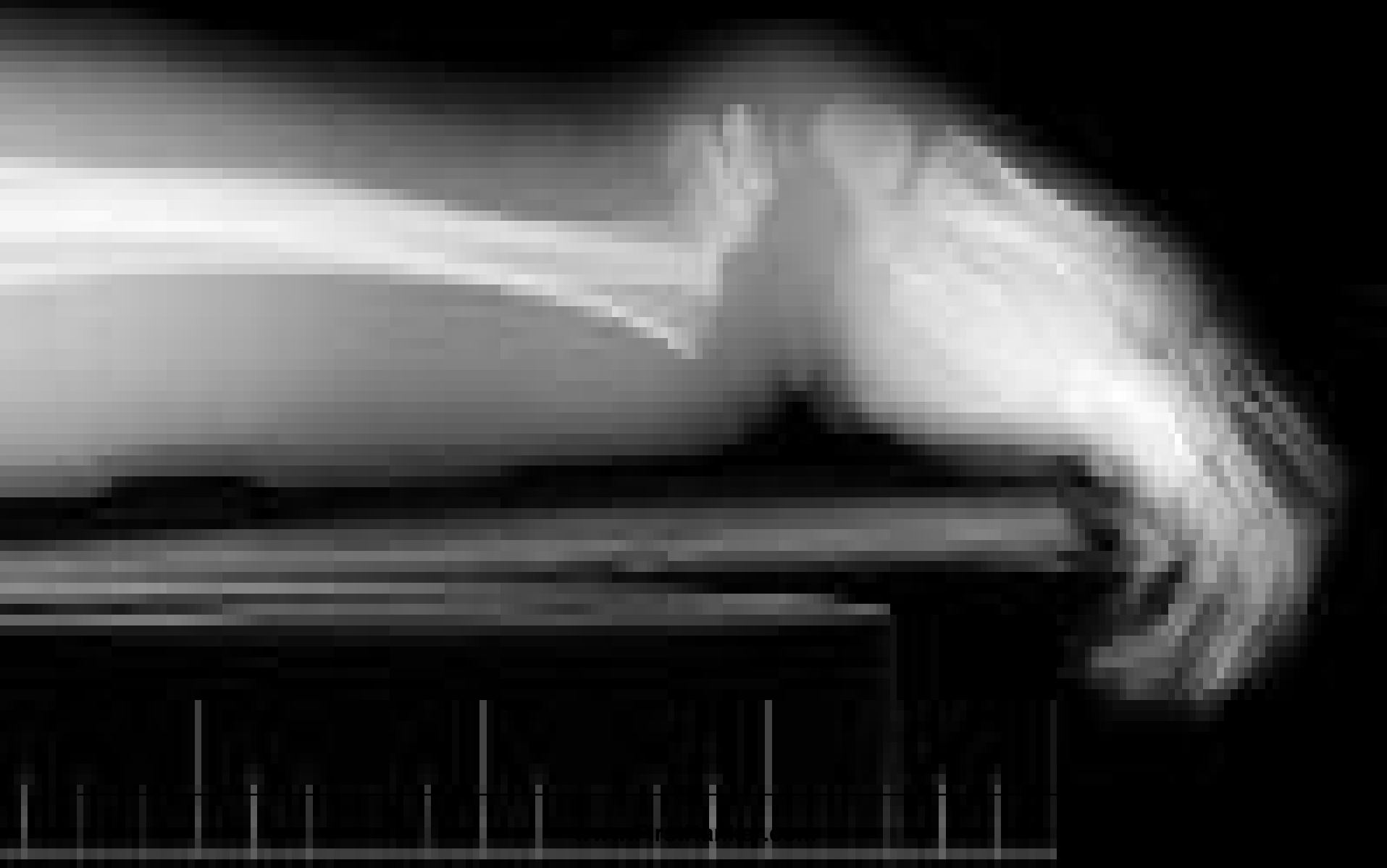

RADIOLOGICAL FEATURES

✴ **LATERAL VIEW:- DORSAL TILT**

✴ **AP VIEW:- LATERAL TILT**

LATERAL VIEW



**AP
VIEW**

TREATMENT

**- IMMOBILISATION IN BELOW ELBOW
PLASTER CAST FOR 6 WEEKS**

✓ **DISPLACED**

**- MANIPULATIVE REDUCTION &
IMMOBILISATION IN COLLES CAST**

✓ **COMMUNITED FRACTURE**

**- SHORT EXTERNAL FIXATOR
OR
JESS FIXATOR**

COLLES CAST



COMPLICATIONS

B. STIFFNESS OF JOINTS

C. SUBLUXATION OF INFERIOR RADIOULNAR JOINT

D. CARPAL TUNNEL SYNDROME

E. SUDECK'S OSTEODYSTROPHY

F. RUPTURE OF EXTENSOR POLLICIS TENDON

THANK YOU