1. Weber ferguson approach is used for?

a) Mastoidectomy

b) Maxillectomy

c) Myringoplasty

d) Mandibulectomy

Correct Answer - B

Ans. B. Maxillectomy

WEBER FERGUSON APPROACH:

- This approach involves an extension of the lateral rhinotomy incision that includes the splitting of upperlip.
- Indications: Exenteration of maxilla for total or subtotal maxillectomy (splitting the upper lip releases the facial flap for adequate lateral retraction and adds transoral exposure of palate and teeth)

2. A patient with ear complaints showed positive Hennebert sign. Which of the following condition shows positive Hennebert sign?

a) Meniere's disease

b) Acoustic neuroma

c) Neuronitis

d) Glossopharyngeal neuralgia

Correct Answer - A

The presence of a fistula is suspected if nystagmus occurs or if the patient perceives movement of a visual target that is fixed after applying positive pressure to the outer ear canal.

A positive test result (ie, **Hennebert sign**) suggests either a **perilymph fistula** or **Meniere's disease.**

3. **The maxillary sinus opens into middle meatus at the level of:**

a) Hiatus semilunaris

b) Bulla ethmoidalis

c) Infundibulum

d) None of the above

Correct Answer - A

The **maxillary sinus** is the largest of the paranasal sinuses and is located in the maxilla, lateral to the nasal cavity and inferior to the orbit.

The maxillary sinus opens into the posterior aspect of the hiatus semilunaris in the middle meatus.

The **infraorbital nerve (CN V-2)** primarily innervates the maxillary sinus.

4. Gradenigo's syndrome involves all of the following cranial nerves, EXCEPT:

a) IV

b) V

c) VI

d) VII

Correct Answer - A

Ans. A. IV

Gradenigo's syndrome is characterized by facial pain, particularly in the first division of the trigeminal nerve and diplopia due to sixth cranial nerve palsy. It is associated with disease at the apex of the petrous temporal bone where the abducens nerve is closely related to the trigeminal nerve. Facial nerve palsy and deafness (VIII nerve palsy) is also considered to be a part of this syndrome.

Causes includes:

- Inflammation (petrositis, possibly spreading from a local infection such as otitis or mastoiditis)
- Tumors (cholesteatoma, chordoma, meningioma, nasopharyngeal carcinoma, metastatic disease)
- Skull base fracture

5. Ceruminous glands present in the ear are:

a) Modified eccrine glands

b) Modified apocrine glands

c) Mucous gland

d) Modified holocrine glands

Correct Answer - B
Ans. is. B. Modified apocrine glands

6. Mac Ewan's triangle is the landmark for:

a) Maxillary sinus

b) Mastoid antrum

c) Frontal sinus

d) None

Correct Answer - B
Ans. is. B. Mastoid antrum

7. External auditory canal is formed by:

a) 1St branchial groove

b) 1st visceral pouch

c) 2nd branchial groove

d) 2nd visceral pouch

Correct Answer - A
Ans. is. A. 1st branchial groove

8. Hyperacusis is defined as:

a) Hearing of only loud sound

b) Normal sounds heard as loud and painful

c) Completely deaf

d) Ability to hear in noisy surroundings

Correct Answer - B

Sensation of discomfort or pain on exposure to normal sounds. Seen in injury to nerve to stapedius and in case of congenital syphilis (Hennebert sign)

9. In electrocochleography:

a) It measures middle ear latency

b) Outer hair cells are mainly responsible for cochlear microphonics and summation potential

c) Summation potential is a compound of synchronus auditory nerve potential

d) Total AP represents endocochlear receptor potential to an external auditory stimulus

Correct Answer - B
Ans. is. B. Outer hair cells are mainly responsible for cochlear microphonics and summation potential

10. True statement about malignant otitis externa is:

a) Not painful

b) Common in diabetics and old age

c) Caused by streptococcus

d) All of the above

Correct Answer - B
Ans. is. B. Common in diabetics and old age

11. Ossicle M/C involved in CSOM:

a) Stapes

b) Long process of incus

c) Head of malleus

d) Handle of malleus

Correct Answer - B
Ans. is. B. Long process of incus

12. Most common nerve to be damaged in CSOM is

a) III

b) VII

c) IV

d) VI

Correct Answer - B

Facial nerve is the M/C nerve to be damaged in CSOM.

13. Simple mastoidectomy is done in:

a) Acute mastoiditis

b) Cholesteatoma

c) Coalescent mastoiditis

d) Localized chronic otitis media

Correct Answer - C
Ans. is. C. Coalescent mastoiditis

14. Radical mastoidectomy is done for:

a) ASOM

b) CSOM

c) Atticoantral cholesteotoma

d) Acute mastoiditis

Correct Answer - C
Ans. is. C. Atticoantral cholesteotoma

15. Light house sign in seen in ASOM in which stage?

a) Stage of suppuration

b) Stage of hyperaemia

c) Stage of resolution

d) Stage of pre-suppuration

Correct Answer - A

In the stage of supperation of ASOM, pus formation occurs, hence in this stage pulsatile otorrhea or light house sign in seen.

16. In otosclerosis, the tympanogram is:

a) Low compliance

b) High compliance

c) Normal compliance

d) None of the above

Correct Answer - A

In otosclerosis - As type curve is seen which is a low compliance curve.

17. Which fracture of the petrous bone will cause facial nerve palsy:

a) Longitudinal fractures

b) Transverse fractures

c) Mastoid

d) Facial nerve injury is always complete

Correct Answer - B
Ans. is. B. Transverse fractures

18. FISCH classification is used for:

a) Juvenile nasopharyngeal angiofibroma

b) Nasopharyngeal ca

c) Vestibular schwannoma

d) Glomus tumour

Correct Answer - D
A classification system (A-D) describing glomus tumors based on anatomic location and size, with larger lettering representing more extensive tumors.

19. True about rhinophyma:

a) Premalignant

b) Common in alcoholics

c) Acne rosacea

d) Fungal etiology

Correct Answer - C

- Rhinophyma is a slow-growing benign tumor which occurs due to hypertrophy of the sebaceous glands° of the tip of the nose.
- Seen in long standing cases of acne rosacea.
- Mostly affects men past middle age.
- Presents as a pink, lobulated mass over the nose.

Treatment

- Paring down the bulk of the tumor with a sharp knife, or carbon dioxide laser or scalpel (dermabraions), and the area is allowed to re-epithelize.
- Sometimes tumor is completely excised and the raw area is covered with skin graft.

20. What is a Rhinolith:

a) Foreign body in nose

b) Stone in nose

c) Deposition of calcium around foreign body in nose

d) Misnomer

Correct Answer - C
Rhinoliths are calcareous masses which result due to deposition of salts-like calcium and magnesium carbonates and phosphates around the nucleus of a foreign body.

21. Posterior epistaxis occurs from:

a) Woodruffs plexus

b) Kiesselbach's plexus

c) Atherosclerosis

d) Littles area

Correct Answer - A

22. Caldwell view is done for

a) Sphenoid sinus

b) Maxillary sinus

c) Ethmoid sinus

d) Frontal sinus

Correct Answer - D

Caldwell view is the occipito frontal view. The frontal sinuses are seen clearly in this view.

23. Regarding ranula all are true except:

a) Retention cyst

b) Arises from submandibular gland

c) Translucent

d) Plunging may be a feature

Correct Answer - B

24. Regarding adenoids true is/are:

a) There is failure to thrive

b) Mouth breathing is seen

c) CT scan should be done to assess size

d) a and b

Correct Answer - D
High arched palate and mouth breathing are features of hypertrophied adenoids which leads to adenoid facies
In adenoids as a consequence of recurrent nasal obstruction and URTI, child develops failure to thrive
Size of adenoids may well be assessed using lateral radiograph of nasopharynx, and CT scan is not necessary
Adenoids, also known as nasopharyngeal tonsils, are subepithelial collection of lymphoid tissue at the junction of roof and posterior wall of nasopharynx.

25. Trismus in parapharyngeal abscess is due to spasm of:

a) Masseter muscle

b) Medial pterygoid

c) Lateral pterygoid

d) Temporalis

Correct Answer - B
Styloid process divides the pharynx into anterior and posterior compartment.
Trismus occurs in infection of anterior compartment whereas torticollis (due to spasm of paravertebral muscles) occurs in the infection of posterior compartment.

26. Inlet of larynx is formed by:

a) Ventricular fold

b) Aryepiglottic fold

c) Glossoepiglottic fold

d) Vocal cord

Correct Answer - B
The laryngeal inlet (laryngeal aditus, laryngeal aperture) is the opening that connects the pharynx and the larynx. Its borders are formed by: the free curved edge of the epiglottis, anteriorly.
the **arytenoid cartilages**, the corniculate cartilages, and the interarytenoid fold, posteriorly.

27. All the following are true about Laryngeal carcinoma except:

a) More common in females

b) Common in patients over 40 years of age

c) After laryngectomy, esophageal voice can be used

d) b and c

Correct Answer - A

Cancer Larynx

- Most common histological type of laryngeal Ca - Squamous cell carcinoma (seen in 90% cases)
- It is more common in males.
- Male: Female ratio is 4: 1
- Most common age = 60-70 years.

28. Select correct statements about Ca larynx:

a) Glottic Ca is the most common

b) Supraglottic ca has best prognosis

c) Lymphatic spread is the most common in subglottic Ca

d) All

Correct Answer - A
Ans. is. A. Glottic Ca is the most common

29. The commonest site of aspiration of a foreign body in the supine position is into the:

a) Right upper lobe apical

b) Right lower lobe apical

c) Left basal

d) Right medial

- Correct Answer - B
  In supine position and with the patient on back superior segment of **RLL** is the most dependent segment.

30. Cauliflower ear seen in:

a) Hematoma of the auricle

b) Carcinoma of the auricle

c) Fungal infection of the auricle

d) Congenital deformity

Correct Answer - A
Cauliflower ear (boxer's ear, wrestler's ear) is an acquired deformity of the outer ear.
In this injury, the ear can shrivel up and fold in on itself and appear pale, giving it a cauliflower-like appearance, hence the term cauliflower ear.
Wrestlers, boxers and martial artists in particular are susceptible to this type of injury. When the ear is struck and a blood clot develops under the skin, or the skin is sheared from the cartilage, the connection of the skin to the cartilage is disrupted.

31. All of the following arteries contributes to Little's area EXCEPT:

a) Anterior Ethmoidal artery

b) Posterior Ethmoidal artery

c) Sphenopalatine artery

d) Greater palatine artery

Correct Answer - B

Kiesselbach's plexus

- It lies in Kiesselbach's area/ Kiesselbach's triangle/ Little's area
- It is a region in the anteroinferior part of the nasal septum where four arteries anastomose to form a vascular plexus of that name. The arteries are:
  - Anterior Ethmoidal artery (from the Ophthalmic artery)
  - Sphenopalatine artery (terminal branch of the Maxillary artery)
  - Greater palatine artery (from the Maxillary artery)
  Septal branch of the superior labial artery (from the Facial artery)
- Although the Posterior Ethmoidal artery also supplies the septum of the nose, it does not contribute to the plexus.

32. Multiple perforation of tympanic membrane characteristic of ?

a) Tubercular Otitis Media

b) Syphilitic Otitis Media

c) Pseudomonas infection

d) Fungal Otitis Media

Correct Answer - A

Ans. is 'a' i.e., Tubercular otitis media

Tubercular otitis media

- Tuberculosis of middle ear is a comparatively rare entity usually seen in association with or secondary to pulmonarytuberculosis, *infection reaches the middle ear through eustachian tube.*
- The rare modes of infection are through hematogenous spread from tubercular focus in lung, tonsils, cervical lymph nodes; or due to ingestion of infected cow's milk.
- It usually affects *children and young adults.*

Clinical features

- Generally, tuberculosis of middle ear is unilateral.
- *It is characterized by painless otorrhoea* which fails to respond to the usual antimicrobial treatment. There is painless watery otorrhea.
- *Single or multiple perforation of tympanic membrane.* There may be multiple perforations in the early stages, but they coalesce into a large tympanic membrane perforation accompanied by a *pale granulation tissue.*
- Periauricular fistulae, lymphadenopathy and facial palsy are infrequent findings.
- Late complications include facial paralysis, labyrinthitis, postauricular fistulae, subperiosteal abscess, petrous apicitis and intracranial

extension of infection.

33. Another name for oral thrush is ?

a) Candidiasis

b) Herpangina

c) Vincent's infection

d) Hand foot and mouth disease

Correct Answer - A

Ans. is 'a' i.e., Candidiasis

Oral thrush

- Also called: **oral candidiasis**
- It is the fungal infection of the oral cavity. It is caused by candida albicans.
- It manifests as greyish white patches on the oral mucosa and tongue.\When wiped off it leaves an erythematous mucosa.
- This is more common in infants and children. Adults suffering fro diabetes, malignancy, taking broad spectrum oral antibiotics, radiation, cytotoxic drugs or steroids can also be affected.
- It is treated by topical application of nystatin or clotrimazole.
- Chronic Hypertrophic Candidiasis (Candidial Leukoplakia)
- Appears as a white patch in the oral cavity which cannot be wiped off.
- It mostly affects the anterior buccal mucosa just behind the angle of mouth.
- It is treated by excision of the lesion.

34. Which of the following is not true about inverted papilloma ?

a) It is always unilateral

b) It is more common in males

c) 10-15 % of the cases may be associated with squamous cell carcinoma

d) It is also called Ringertz tumor

Correct Answer - D

Ans. is 'd' i.e., It is also called Ringertz tumor

Inverted Papilloma (Transitional cell papilloma / Schneiderion papilloma)

- Inverted papilloma is a benign neoplasm occurs mostly between *40-70 years* with *male* preponderance (5 : 1). o It arises from the *lateral wall of nose* and is *always unilateral.* Rarely, it may arise from nasal septum. o *Features of inverted papilloma are :-*
- It shows finger like epithelial invasions into the underlying stroma of the epithelium rather than on surface so called inverted papilloma.
- It is usually unilateral and is a locally aggressive tumour.
- Patients complain of nasal obstruction, rhinorrhea & unilateral epistaxis.
- In 10-15% cases there may be associated squamous cell carcinoma.
- Treatment is adequate local excision. If it arises in maxillary sinus, then a radical antrostomy is carried out.If it arises in the ethmoidal sinus, an external ethmoidectomy is done. If it arises from nose, treatment is wide surgical excision by lateral rhinotomy.
- Has a tendency to recur even after removal.

35. Positive head impulse test is suggestive of ?

a) Injury to vestibular nuclei

b) Injury to peripheral vestibular nerve

c) Lesion in the brain stem

d) Injury to Occulomotor nerve

Correct Answer - B

Ans. is `b' i.e., Injury to peripheral vestibular nerve

Head Impulse Test

- It is also called head thrust test.
- It is test for the diagnosis of injury to vestibular nerve which forms the peripheral vestibular pathway.
- Clinician asks the patient to fix his gaze on a target and then perform passive horizontal and vertical head impulses and observes the patient's eyes.
- Observation of a refixation saccade after the head impulse indicates decreased decreasedvestibulo ocular reflex secondary to peripheral vestibular lesions (vestibular nerve involvement).

36. Conducting hearing loss with intact tympanic membrane ?

a) Presbycausis

b) Meniere's disease

c) Glue ear

d) Acoustic neuroma

Correct Answer - C
Ans. is 'c' i.e., Glue ear
Among the given options, only glue ear (serous otitis media) is a cause of conductive deafness.

37. Not a cause of objective tinnitus ?

a) Palatal myoclonus

b) Glomus tumor

c) Carotid artery aneurysm

d) Presbyacusis

Correct Answer - D
Ans. is 'd' i.e., Presbyacusis
Tinnitus

- Tinnitus is ringing sound or noise in the ear.
- The characteristic feature is that the origin of this sound is within the patient.

38. Length of external auditory meatus is ?

a) 12mm

b) 16mm

c) 20mm

d) 24mm

Correct Answer - D

Ans. is 'd' i.e., 24 mm

External auditory canal (External acoustic meatus)

External auditory canal is a *'S' shaped* canal with length of *24-25 mm* and it is divided into two parts :?

1) Cartilagenous part

- It forms *outer/lateral 1/3 (8mm)* of the external auditory canal. It has two fissures / deficiencies in the anterior part called *fissure of santorini* through which parotid or superficial mastoid infection can appear in the canal and vice versa. Skin covering it is thick and has *ceruminous glands (modified apocrine sweat glands),* pilosebaceous glands and hair. Since hair is confined to cartilaginous part, *furuncles are seen only in the outer third of the canal.*

2) Bony part

- It forms *inner/medial 2/3 (16 mm)* of external auditory canal. Skin lining the bony part is thin and is *devoid of hair and ceruminous glands. Isthmus* is the narrowest portion of bony canal and is 5 mm lateral to tympanic membrane. Foreign bodies get lodged in isthmus are difficult to remove as it is the narrowest part. `*Foramen of Huschke'* is a deficiency present in *antero-inferior* part of bony canal in *children upto 4 years of age,* permitting infection to and from parotid.

39. Which of the following is false regarding frontal sinusitis ?

a) Pain shows periodicity

b) Most common sinus involved in infants and children

c) Pain is referred to as office headache

d) Tenderness is present just above the medial canthus of eye

Correct Answer - B
Ans. is 'b' i.e., Most common sinus involved in infants and children
Most common sinus involved in infant and children is Ethmoid sinus.
Clinical features of acute sinusitis
Most common presenting patient's compliant is persistent nasal discharge which can be of any quality (thin, thick, clear, or purulent). Nasal discharge from a sinus infection *can be blood - tinged* from excessive nose blowing and irritation. The clinical symptoms of acute sinusitis have been classified into major and minor.

40. Mini tracheostomy is performed through ?

a) Cricothyroid membrane

b) 2nd and 3rd tracheal rings

c) Any of the above

d) None of the above

Correct Answer - A

Ans. is 'a' i.e., Cricothyroid membrane

Cricothyrotomy or Laryngtomy or Minitracheostomy

- It is the procedure to open the airway through the cricothyroid membrane.
- Patient's head and neck are extended, lower border of throid cartilage and cricoid ring is identified. Skin in this area is incised vertically and then cricothyroid membrane is opened with a transverse incision.
- It is an emergency procedure to buy time for the patient to be shifted to the operation theatre.

41. Which of the following is included in the Levenson criteria for congenital cholesteatoma ?

a) White mass medial to normal tympanic membrane

b) Atticoantral perforation of the tympanic membrane

c) Definite history of otorrhoea

d) History of prior otologic procedures

Correct Answer - A

Ans. is 'a' i.e., White mass medial to normal tympanic membrane

Levenson criteria for congenital cholesteatoma

1. *White mass medial to normal TM.*
2. *Normal pars flaccida and tensa.*
3. *No history of otorrhea or perforations.*
4. *No prior otologic procedures.*
5. *Prior bouts of otitis media no ground for exclusions.*

42. Which of the following is false regarding Frey's syndrome?

a) It is also called gustatory sweating

b) It is caused by injury to auriculotemporal nerve

c) It occurs immediately after the parotid surgery

d) It is caused by aberrant regeneration of post

Correct Answer - C

Ans. is 'c' i.e., It occurs immediately after the parotid surgery

Frey's syndrome (gustatory sweating)

- Gustatory sweating or Frey's syndrome involves post-parotidectomy *facial sweating and skin flushing while eating.*
- The symptoms usually occur several months or even years after *parotid surgery.*
- The likely pathophysiology is aberrant regeneration of postganglionic secretomotor parasympathetic nerve fibres (originating from the otic ganglion) misdirected through several axonal sheaths of post-ganglionic sympathetic fibres feeding the sweat glands. These sympathetic fibres are to the sweat glands of the skin in the dissected field.
- The frey's syndrome is likely due to *injury to auriculotemporal nerve* with faulty regeneration, therefore Frey's syndrome is also known as Auriculotemporal syndrome.
- *A variant of Frey's syndrome* in which there is gustatory facial flushing but not sweating, occurs following facial paralysis due to faulty regeneration following *injury to the facial* nerve. So, Frey's syndrome is not limited to parotid surgery with injury to auriculotemporal nerve.

43. Most common cause of trigeminal neuralgia ?

a) Infection

b) Trauma

c) Vascular compression

d) Iatrogenic

Correct Answer - C
Ans. is 'c' i.e., Vascular compression

- Trigeminal neuralgia (tic douloureux) is characterized by intermittent, shooting pain in the face.
- It is due to involvement of trigeminal nerve.
- 95% of causes of trigeminal neuralgia are due to pressure on trigeminal nerve close to where it enters the brain stem, past the Gasserian ganglion. *In most cases, this pressure seems to be caused by an artery or vein compressing trigeminal nerve.*
- Other causes are tumor, cysts, AV malformation and multiple sclerosis.
- Most commonly used drugs for treatment of trigeminal neuralgia are *carbamazepine, gabapentin and valproate.*

44. Patient with thin painless otorrhoea, multiple perforations of the tympanic membrane and failure to respond to antimicrobial treatment. What is the most probable causative organism ?

a) Mycobacterium tuberculosis

b) Staphylococcus aureus

c) Candida albicans

d) Aspegillusfumigatus

Correct Answer - A
Ans. is 'a' i.e., Mycobacterium tuberculosis
Thin painless otorrhoea, multiple perforations of the tympanic membrane and failure to respond to antimicrobial treatment are the features of tubercular otitis media and it is caused by Mycobacterium tuberculosis.

45. Synkinesis is a sequel of ?

a) Facial nerve paralysis

b) Trigeminal nerve paralysis

c) Superficial temporal nerve paralysis

d) Greater Petrosal nerve paralysis

Correct Answer - A

Ans. is 'a' i.e., Facial nerve paralysis

Clinical features of Bell's palsy

- *Acute onset, ipsilateral facial paralysis.*
- Facial paralysis is usually preceded by pain behind the ear.
- Patient is unable to close his eyes.
- Bells phenomenon, i.e. on attempting to close the eye, eyeball turns up and out.
- Face becomes asymmetrical and saliva dribbles from angle of mouth.
- Ipsilateral loss of taste sensation, salivation and lacrimation.
- Intolerance to high pitched or loud sound *(hyperacusis).*
- Most patients (80%) recover within few weeks to months.
- Synkinesis and crocodile tear are sequelae of Bell's palsy :-
- *Synkinesis or facial synkinesis* is a *common sequelae to Bell's palsy.* This is due to cross innervation of nerve fibres during recovery. When the patient wishes to close the eye, corner of mouth also twiches and vice versa.
- *Crocodile tear (gustatory lacrimation)* is due to faulty regeneration of parasympathetic fibres which now supply lacrimal gland instead of the salivary glands.

46. Sago grain appearance is seen in ?

a) Healed myringitis bullosa

b) Otomycosis

c) Malignant otitis externa

d) Keratosis obturans

Correct Answer - A

Ans. is 'a' i.e., Healed myringitis bullosa

Otitis externa haemorrhagica

- This condition is also known as *Bullous myringitis or myringitis bullosa.*
- This condition is extremely painful and has sudden onset.
- It is thought to be due to *mycoplasma pneumoniae* or *viral infection, usually influenza'.*
- There may be a mild conductive deafness and a mildly discharging car.
- *The appearance of haemorrhagic bullae on the tympanic membrane and in the deep meatus is characteristic.* The bullae are filled with serosanguinous fluid and blood.
- On healing, bullae look like Sago-grain.
- Therefore *"Sago-grain" appearance* of tympanic membrane is seen in healed myringitis bullosa.

47. Following is the preferred treatment of Serous Otitis Media -

a) Grommet surgery

b) Oral Amoxicillin for 5 - 10 days

c) Modified radical mastoidectomy

d) Bed rest, antipyretics and adequate fluid intake

Correct Answer - A

Ans. is 'a' i.e., Grommet surgery

Treatment of otitis media

Following two treatments have been described : ?

1) Watchful waiting

- Watchful waiting is the active monitoring of the condition and hearing in anticipation of spontaneous resolution. Guidlines aimed at both primary care and specialist otolaryngologist broadly agree that a *watchful waiting period for about three months* is the initial management of children with serous otitis media. Therefore, *unless there are also signs of an infection, most health care providers will not treat SOM at first Instead, they will recheck the problem in 2-3 months.* This should be coupled with *reassurance* that doing nothing is as likely as doing something to result in resolution of the SOM and the associated symptoms.

2) Surgery

- Surgical intervention is recommended when watchful waiting and monitoring of hearing has confirmed failure of resolution of SOM. Following surgical intervention are used commonly : -

i. *Myringotomy and aspiration offluid :* -An incision is made in tympanic membrane and fluid aspirated with suction.

i. *Grommet (ventilation tube) surgery :* - If myringotomy and aspiration

combined with medical measures has not helped and fluid recurs, a grommet is inserted to provide continued aeration of middle ear. *This is the most common surgical intervention for SOM. Most prefered site of grommet insertion is antero-inferior through circumferential or radial incision.*

i. *Surgical treatment of causative factor :* - Adenoidectomy, tonsillectomy etc.

Medical measures are controversial **and involve : ?**

1. Decongestants
2. Antiallergic measures
3. Antibiotics
4. Middle ear aeration :- Valsalva maneuver, Politzerisation or eustachian tube catheterization, Chewing gum.

48. When a patient says Ah the right uvula presses the palate which of the following nerve is damaged ?

a) Rght X CN

b) Right XII CN

c) Left X CN

d) Right XII CN

Correct Answer - C

Ans. is 'c' i.e., Left X CN

Assessment of the movement of soft palate - Both IX and X CNs are tested:

The glossopharyngeal nerve (IX CN) is a mixed nerve with motor, sensory and some parasympathetic activity. It carries sensory input from the palate and pharynx and the taste from the posterior third of the tongue. It provides afferent limb of the gag reflex.

The vagus (X CN) is also a mixed nerve with motor, sensory and parasympathetic activity. It provides the motor supply to the pharynx, soft palate and larynx and provides the efferent limb to the gag reflex.

Normally on oral examination thesoft palate is symmetrical with the uvula dangling in the centre and dividing the soft palate.

When the patient is asked to say AAAh! The soft palate should elevate symmetrically and the uvula should remain centric. If there is unilateral weakness of the soft palate the uvula is pulled away from the weakened side.

Now in the question given when the patient says aaah the right uvula presses the palate i. e. the right side soft palate pulls the uvula away from the weak left side. The weakness of the left soft palate

away from the weak left side. The weakness of the left soft palate can be because of the weakness of the left IX or X cranial nerves.

49. Lumpy feeling in throat relieved on taking food is attributed to ?

a) Globus pharyngeus

b) Pharyngeal pouch

c) Diverticular disease

d) Esophageal atresia

Correct Answer - A

Ans. is 'a' i.e., Globus Pharyngeus

Globus Pharyngeus

- Symptom where in a patient describes something stuck in throat or a sensation of lump or tightness in throat which is relieved by taking food or talking.

50. Glomus jugulare commonly arises from ?

a) Hypotympanum

b) Mesotympanum

c) Epitympanum

d) Prussaks space

Correct Answer - A
Ans. is 'a' i.e., Hypotympanum
There are two types of glomus tumors:-
i) Glomus jugulare
These glomus tumors arise from the dome of the internal jugular vein in the *hypotympanum* and jugular foramen. In jugular foramen they can invade IX to XII cranial nerves.
ii) Glomus tympanicum
They arise from the promontory of the middle ear along the course of the tympanic branch of the IXth cranial nerve.

51. Gradenigo syndrome is characterized by all except ?

a) Diplopia

b) Retro-orbital pain

c) Persistent ear discharge

d) Vertigo

Correct Answer - D

Ans. is d i.e., Vertigo

Infection of mastoid and middle ear may be complicated by the spread of infection within the temporal bone into *petrous apex.* Petrositis is an extension of infection from middle ear and mastoid to the petrous part of the temporal bone.

Gradenigo's syndrome is the classical presentation and consists of a triad of : -

- *External rectus palsy (VIth nerve/abducent nerve palsy) causing diplopia.*
- *Deep seated orbital or retroorbital pain (Vth nerve involvement).*
- *Persistent ear discharge due to ipsilateral acute or chronic otitis media.*

Associated symptoms of otitis media are also present e.g., *conductive deafness.* Other symptoms are fever, headache, vomiting, and sometimes neck rigidity. Some patient may get facial paralysis and recurrent vertigo due to involvement of facial and statoacoustic nerves.

52. Attico antral disease is treated by ?

a) Modified radical mastoidectomy

b) Antibiotics

c) Grommet insertion

d) Synringing

Correct Answer - A

Ans. is 'a' i.e., Modified radical mastoidectomy

Treatment of atticoantral disease

Since cholesteatoma is going to expand and destroy bone and mucous membrane, it has to be removed. Therefore, *surgery is the mainstay of treatment.* Primary aim is removal of disease by mastoidectomy to make ear safe followed by reconstruction of hearing at a later stage. *Modified radical mastoidectomy is the surgery of choice.*

Two types of *surgical procedures (mastoidectomy)* are done to deal with cholesteatoma.

1) *Canal wall down procedures*

- These leave the mastoid cavity open into the external auditory canal so that the diseased area is fully exteriorized.
- The commonly used procedures for atticoantral disease are *atticotomy, modified radical mastoidectomy* and rarely *radical mastoidectomy.*
- *Modified radical mastoidectomy is the procedure of choice.*

2) Canal wall up procedures (cortical mastoidectomy)

- Here disease is removed by combined approach through the meatus and mastoid but retaining the posterior bony meatus wall, thereby avoiding an open mastoid cavity.
- For reconstruction of hearing mechanism *myringoplasty* or

tympanoplasty can be done at the time of primary surgery or as a second stage procedure.

53. Samters triad is seen in patients with ?

a) Asthma

b) Chronic pancreatitis

c) Crohn's disease

d) Liver cell carcinoma

Correct Answer - A

Ans. is 'a' i.e., Asthma

Samter's triad

- Samter's triad is a medical condition consisting of asthma, aspirin sensitivity, and nasal/ethmoidal polyposis. It occurs in middle age *(twenties and thirties are the most common onset times)* and may not include any allergies.
- *Most commonly, the first symptom* is rhinitis.
- The disorder typically progeses to asthma, then polyposis, with aspirin sensitivity coming last.
- The aspirin reaction can be severe, including an asthma attack, anaphylaxis, and urticaria in some cases. Patients typically react to other NSAIDS such as ibuprofen, although paracetamol is generally considered safe.
- Anosmia (lack of smell) is also typical, as the inflammation reaches the olfactory receptors in the nose.

54. Strawberry tongue is seen in ?

a) Streptococcal scarlet fever

b) Kawasaki disease

c) Both of the above

d) None of the above

Correct Answer - C
Ans. is 'c' i.e., Both of the above
Strawberry tongue

- It is also called raspberry tongue
- It basically refers to glossitis, which manifests with hyperplastic (enlarged) fungiform papillae, giving the appearance of a strawberry.
- White strawberry tongue is where there is a white coating on the tongue through which the hyperplastic fungiform papillae protrude.
- Red strawberry tongue is where the white coating is lost and a dark red, erythematous surface is revealed, interspaced with the hyperplastic fungiform papillae.
- White strawberry tongue is seen in early scarlet fever (a systemic infection of group A hemolytic streptococci).
- Red strawberry tongue occurs later, after 4-5 days.
- Other conditions in which strawberry tongue is seen are: Kawasaki disease, toxic shock syndrome, and vitamin B 12 deficiency.

55. All are true for gradenigo's syndrome except ?

a) Associated with intermittent ear discharge

b) Associated with conductive hearing loss

c) Causes diplopia

d) Leads to retro orbital pain

Correct Answer - A
Ans. is 'a' i.e., Associated with intermittent ear discharge
Gradenigo's syndrome, also called **Gradenigo-Lannois syndrome**, is a complication of otitis media and mastoiditis involving the apex of the petrous temporal bone.

Symptoms

Components of the syndrome include:

- **retroorbital pain** due to pain in the area supplied by the ophthalmic branch of the trigeminal nerve (fifth cranial nerve),
- abducens nerve palsy (sixth cranial nerve)
- otitis media

Other symptoms can include photophobia,
excessive lacrimation, fever, and reduced corneal sensitivity. The syndrome is classically caused by the spread of an infection into the petrous apex of the temporal bone.

56. Treatment of middle ear papilloma is ?

a) Myringotomy and simple excision

b) Myringectomy and simple excision

c) Tympanomastoidectomy

d) Local infiltration with podophyllin

Correct Answer - C
Ans. is 'c' i.e., Tympanomastoidectomy
Middle ear pappilomas
The middle ear papillomas are rare presentations and medical literature is mainly limited to case reports or case series.
These include aggressive pappilary tumors, schneiderian type of pappilomas and inverted pappilomas.
They are associated with hearing difficulty and vertigo and may be associated with Von Hippel Lindau syndrome.
They tend to be slowly growing, locally aggressive non metastasizing neoplasms
The approach for treatment of such pathology is usually radical and tympanomastoidectomy is considered the treatment of choice. This gives the best chance of cure.

57. Best time for hearing assessment in an infant ?

a) 1st month of life

b) 3-6 months

c) 6-9 months

d) 9-12 months

Correct Answer - A
Ans. is 'a' i.e., 1st month of life
The American Academy of Pediatrics (AAP), Joint Committee on Infant hearing (2007), has recommended that all newborn infants be screened for hearing impairment *either as neonate or before 1 month of age* and that those infants who fail newborn screening have an audiologic examination to varify hearing loss before age of 3 months.

58. Darwin tubercle is seen in ?

a) Tragus

b) Helix

c) Antihelix

d) Lobule

Correct Answer - B

Ans. is 'b' i.e., Helix

- Darwin's tubercle (or auricular tubercle) is a congenital earcondition which often presents as a thickening on the helix at the junction of the upper and middle thirds.
- The feature is present in approximately 10·4% of the population.This acuminate nodule represents the point of the mammalian ear.

59. Trotter triad not included is ?

a) Conductive deafness

b) Temporoparietal neuralgia

c) Palatal paralysis

d) Seizures

Correct Answer - D
Ans. is 'd' i.e., Seizures
Trotter's triad
Trotter's triad occurs in nasopharyngeal carcinoma
It includes :-
i) Conductive deafness (due to Eustachian tube blockage)
ii) Temporo - parietal neuralgia (due to involvement of ipsilateral V^{th} cranial nerve)
iii) Palatal paralysis (due to involvement of Xth cranial nerve)

60. Following protein is not found in organ of corti ?

a) Myosin

b) Microtubule associated protein 2

c) Microtubule associated protein 4

d) Fodrin

Correct Answer - C

Ans. is 'c' i.e., Microtubule associated protein 4

Proteins present in cochlea

- Actin-binding and microtubule-associated proteins regulate microfilament and microtubule number, length, organization and location in cells.
- In freeze-dried preparations of the guinea pig cochlea, both actin and tubulin are found in the sensory and supporting cells of the organ of Corti.
- Fodrin (brain spectrin) co-localized with actin in the cuticular plates of both inner and outer hair cells and along the lateral wall of the outer hair cells.
- Alpha-actinin co-localized with actin in the cuticular plates of the hair cells and in the head and foot plates of the supporting cells. It was also found in the junctional regions between hair cells and supporting cells. o Profilin co-localized with actin in the cuticular plates of the sensory hair cells.
- Myosin was detected only in the cuticular plates of the outer hair cells and in the supporting cells in the region facing endolymph.
- Gelsolin was found in the region of the nerve fibers.
- Tubulin is found in microtubules in all cells of the organ of Corti.
- In supporting cells, microtubules are bundled together with actin

microfilaments and tropomyosin, as well as being present as individual microtubules arranged in networks.

- An intensely stained network of microtubules is found in both outer and inner sensory hair cells.
- The microtubules in the outer hair cells appear to course throughout the entire length of the cells, and based on their staining with antibodies to the tyrosinated form of tubulin they appear to be more dynamic structures than the microtubules in the supporting cells.
- The microtubule-associated protein MAP-2 is present only in outer hair cells within the organ of Corti and co-localizes with tubulin in these cells. No other MAPs (1,3,4,5) are present.
- Tau is found in the nerve fibers below both inner and outer hair cells and in the osseous spiral lamina.

61. Following is true about laryngomalacia except ?

a) Omega shaped epiglottis

b) Reassuarance of the patient is the treatment of choice

c) Condition is first noticed in the first few weeks of life

d) Expiratory stridor

Correct Answer - D

Ans. is 'd' i.e., Expiratory stridor

Laryngomalacia

- It is the *most common congenital abnormality of the larynx.* Laryngomalacia is the *most frequent cause of stridor or noisy breathing in infants.* It occurs as a result of a floppy portion of the larynx (in supraglottic larynx) that has not yet developed the strength to provide rigid support to the airway. *During inspiration* negative pressure is created through larynx, which results in a collapse of these structures into the airway and a narrower breathing passage. Partial obstruction is the source of the noise with breathing (stridor), and sometimes cyanosis.
- The hallmark sign includes *intermittent stridor* mostly in *inspiration.* It is usually *more prominent when the infant is lying on his/her back (supine position, crying, feeding, excited or has a cold. Stridor gets relieved on placing the patient in prone position. This is usually first noticed in the first few weeks of life.*
- It may worsen over the first few months and become louder. This is because as the baby grows, inspiratory force is greater, which causes greater collapse of the laryngeal structures into the airway. *This is usually worst at 3-6 months* and then gradually improves as the rigidity of the cartilage improves.

- *Most children are symptom free by 1 to 2 years.*
- Sometimes, *cyanosis* may occur.
- Direct laryngoscopy shows :-
- *Omega shaped epiglottis,* i.e. elongated and curled on itself.
- Floopy, tall, foreshortened and thin aryepiglottic folds.
- Prominent arytenoids.
- In most patients laryngomalacia is a self limiting condition. Treatment of laryngomalacia is reassurance to the parents and early antibiotic therapy for upper respiratory tract infections.

62. Following are the laboratory tests for the diagnosis of vestibular dysfunction except ?

a) Electronystagmography

b) Optokinetic test

c) Galvanic test

d) Gelle's test

Correct Answer - D

Ans. is 'd' i.e., Gelle's test

Vestibular system

- The vestibular system contributes to *balance* and to the sense of *spatial orientation.*
- It is a sensory system that provides the leading contribution about movement and sense of balance.
- It includes the labyrinth (semicircular canals and otolith : utricle & sacules) of the inner ear and is situated in the vestibulum in the inner ear.
- The symptoms of vestibular dysfunction are *vertigo, dizziness and Unbalance.*

63. In a patient with CSOM, labrynthine fistula most commnonly involves ?

a) Superior SCC

b) Lateral SCC

c) Posterior SCC

d) Utricle

Correct Answer - B

Ans. is 'b' i.e., Lateral SCC

- Labrynthine fistula is almost exclusively reported in association with chronic otitis media and cholesteatoma.
- *The most commonly affected canal is lateral (horizontal) semicircular canal,* but involvement of the posterior and superior canals as well as other regions of labyrinth have been reported.
- The incidence of labrynthine fistula in chronic otitis media is approximately 10%.

64. Horizontal acceleration with forward movement in the sagittal plane is detected by ?

a) Macula of Utricle

b) Macula of Saccule

c) Lateral semicircular canal

d) Posterior semicircular canal

Correct Answer - A
Ans. is 'a' i.e., Macula of utricle

65. Patient presents with mouth breathing, recurrent serous otitis media and adenoid facies. What is the best line of management ?

a) Adenoidectomy

b) Tonsillectomy

c) Antibiotics

d) Supportive therapy

Correct Answer - A
Ans. is 'a' i.e., Adenoidectomy
The triad of nasal and aural symptoms with adenoid facies points to the diagnosis of enlarged adenoids.
For the treatment of enlarged adenoids when symptoms are not marked breathing excercise, decongenstant nasal drops and antihistaminics are used and when symptoms are marked, adenoidectomy is done.
We have a patient with marked and recurrent symptoms thus adenoidectomy is the treatment of choice.

66. Which of the following organisms is known to cause Atrophic rhinitis ?

a) Klebsiella ozaena

b) Klebsiella pneumonia

c) Streptococcus pneumonia

d) Streptococcus foetidis

Correct Answer - A

Ans. is 'a' i.e., Klebsiella ozaena

Atrophic rhinitis (Ozaena)

Atrophic rhinitis is a chronic inflammation of nose characterized by atrophy of nasal mucosa, including the glands, turbinate bones and the nerve elements. Atrophic rhinitis may be primary or secondary : ?

1) Primary atrophic rhinitis

The primary pathology is inflammation and atrophy of the nose. Generally, atrophic rhinitis refers to primary atrophic rhinitis.

Causes are : -

i) Hereditary

ii) Endocrinal pathology - Starts at puberty. Stops after menopause

iii) Racial factors - Seen more in Whites and Yellow races

iv) Nutritional deficiency - Deficiency of vitamin A, D, E and iron may be responsible for it.

v) Infective - Klebsiella ozanae, Diphtheriods, P. vulgaris, E.coli, Staphylococci, Streptococci.

vi) Autoimmune process - Causing destruction of nasal, neurovascular and glandular elements may be the cause.

2) Secondary atrophic rhinitis

Specific infections, such *as syphilis, lupus, leprosy,* and

rhinoscleroma, may cause destruction of the nasal structures leading to atrophic changes. Can also results from *long standing purulent sinusitis , radiotherapy of nose, excessive surgical removal of the turbinate* and *as complication of DNS on the root side of nose.*

67. Potato tumor due to ?

a) Hypotrophy of sebaceous glands of nose

b) Hypertrophy of sebaceous glands of nose

c) Hypotrophy of sweat glands of nose

d) Hpertrophy of sweat glands of nose

Correct Answer - B

Ans. is 'b' i.e., Hypertrophy of sebaceous glands of nose

Rhinophyma (Potato tumor)

- Rhinophyma is large, bulb-shaped, red-colored (ruddy) nose. It is a slow growing benign tumor due to hypertrophy of the sebaceous glands. The cause of rhinophyma is unknown, though it is thought to be a severe form of acne roscea. Rhinophyma was once thought to be caused by heavy alcohol consumption, but this is not the case. Rhinophyma occurs equally in those who do not drink at all and those who drink large quantities of alcohol. It mostly affects men past middle age. Red/pink colour of the tumor is due to engorgment of superficial vessels.

Treatment

- Surgery to reshape the nose is the best known treatment for rhinophyma. Surgery may be done with a laser (carbon dioxide laser), scalpel (sharp knife) or a rotating brush *(dermabrasion)* and the area is allowed to re-epithelialize. Sometimes, tumour is completely excised and the raw area is skin-grafted.

68. Rhinitis most common bacterial cause ?

a) Haemophilus influenza

b) Streptococcus haemolyticus

c) Pasturellamultocida

d) Cornybacterium diphtheria

Correct Answer - A
Ans. is 'a' i.e., Haemophilus influenza
Acute bacterial rhinitis is most commonly seen among children, but adult may develop the condition after nasal trauma, viral upper respiratory tract infection, or surgery.

- The clinical presentation of acute bacterial rhinitis may be identical to that of common cold.
- Most common *causative organisms include S. pneumoniae, **H.** influenzae and Moraxella Catarrhalis.*

Note: Overall, most common cause of infective rhinitis is viral infection (viral rhinitis).

69. Surgical markings for finding the facial nerve is are?

a) Tympano - mastoid suture

b) Tragal pointer

c) Posterior belly of digastric

d) All the above

Correct Answer - A

Ans. is 'a' i.e., Tympano-mastoid suture

Surgical landmarks to identify main trunk of the facial nerve are as follows:

i. Tympanomastoid suture line - it is located between the mastoid and the tympanic bones. The main facial trunk lies 6 -8 mm distal to the end of the suture.

i. Tragal pointer - the main nerve trunk lies 1·0 to 1·5 cm deep and slightly anterior and inferior to the tip of the external ear canal cartilage.

i. Posterior belly of digastric -the main nerve trunk lies 1 cm deep to the medial attachment of the posterior belly of digastric muscle to the digastric groove (mastoid notch) of the mastoid bone.

v. Mastoid bone - main nerve trunk is identified inside the mastoid bone by mastoidectomy.

70.

Central part of cholesteatoma contains ?

a) Keratin debris

b) Keratinized squamous epithelium

c) Coulmnar epithelium

d) Fibroblasts

Correct Answer - A
Ans. is 'a' i.e., Keratin debris
Cholesteatoma
Destructive or expanding growth in the middle ear or mastoid process
The term cholesteatoma *is* a misnomer, because it neither contains cholesterol crystals nor is it a tumor to merit the suffix `oma'. Cholesteatoma has the property to destroy bone. It may cause destruction of ear ossicles, erosion of bony labyrinth, canal of facial nerve, sinus plate or tegmen tympani and thus cause several complications. Bone destruction by cholesteatoma has been attributed to various proteolytic enzymes liberated by osteoclasts and mononuclear inflammatory cells, seen in association with cholesteatoma.
Cholesteatoma consists of two parts : *?*
i) Matrix : - Made up of keratinizing squamous epithelium.
ii) Keratin debris (central white mass) : - Produced by the matrix.
Therefore, cholesteatoma also referred to as *epidermosisor keratoma.*

71. Which of the following is not a cause of oropharyngeal carcinoma?

a) Occupational exposue to hydrochloric acid

b) Smoking

c) Human Papilloma Virus infection

d) Occupational exposure to isopropyl oil

Correct Answer - A

Ans. is 'a' i.e., Occupational exposure to hydrochloric acid

<u>Etiology of oropharyngeal carcinoma</u>

i. Tobacco in any form - cigarette smoking or chewing
i. Heavy alcohol abuse
i. Beetle nut chewing
v. Plummer vinson syndrome, cirrhosis
v. Syphilis
i. Trauma
i. Dental irritation
i. Poor oral hygiene
c. Occupational exposure to isopropyl alcohol, sulphuric acid and nickel
c. HPV infection

72. False regarding the foreign body of oropharynx is ?

a) Impacted foreign bodies most often lodge in the soft tissue at the base of tongue

b) Food particles are the most common oropharyngeal foreign bodies in children

c) Clinical hypopharyngeal foreign bodies are amenable to clinical examination

d) Endoscopy and MDCT are used in the diagnosis

Correct Answer - B

Ans. is 'b' i.e., Food particles are the most common oropharyngeal foreign bodies in children

Oropharyngeal foreign bodies

- Most ingested foreign bodies do not impact in the oropharynx
- Sharp foreign bodies like fish and chicken bones most commonly impact in the soft tissues at the base of the tongue.
- Hypopharyngeal foreign bodies can be detected by good physical examination.
- Endoscopy and MDCT are used in the diagnosis of foreign bodies of cervical esophagus.
- Coins are the most common impacted oropharyngeal foreign bodies encountered in children followed by food particles.

73. Not a test for Eustachian tube patency ?

a) Tympanometry

b) Toynbee

c) Valsalva

d) Frenzel maneuver

Correct Answer - A

Ans. is 'a' i.e., Tympanometry

Tests for Eustachian tubepatency

- Valsalva test
- Methylene blue test
- Sonotubometry
- Politzer test
- Toynbee test
- Frenzel maneuver
- Catheterization
- Inflation - Deflation test

74. Tympanoplasty deals with reconstruction of -

a) Tympanic membrane

b) Ossicular chain

c) Both a and b

d) None of the above

Correct Answer - C
Ans. is 'c' i.e., Both a and b

- *Tympanoplasty* is the surgical operation performed for *reconstruction of tympanic membrane and/or middle ear ossicles.*
- *Myringoplasty* is the *reconstruction of tympanic membrane.*
- *Ossiculoplasty* is the *reconstruction of ossicular chain.*
- Tympanoplasty = Myringoplasty ± ossiculoplasty

75. Most common organism cultured in CSOM is ?

a) Staphylococcus aureus

b) Staphylococcus epidermidis

c) Streptococcus pneumonia

d) Pseudomonas aeruginosa

Correct Answer - D

Ans. is 'd' i.e., Pseudomonas aeruginosa

Microbiology of CSOM

- Pus culture in both types of aerobic and anaerobic CSOM may show multiple organisms.
- Most commonly isolated organisms are gram negative bacilli, i.e., Pseudomonas, proteus, E.coli.
- These organisms are not commonly found in the respiratory tract, while commonly found in the skin of external ear.

76. Fowl smelling nasal discharge is seen in all except?

a) Nasal Myiasis

b) Choanal atresia

c) Foreign body in nose

d) Rhinolith

Correct Answer - B
Ans. is `b' i.e., Choanal atresia
Diseases with fowl smelling nasal discharge are:
Nasal myiasis
Foreign body in nose
Rhinolith
In choanal atresia there is presence of nasal discharge without air bubbles.

77. Rhinoscleroma occurs due to ?

a) Autoimmune cause

b) Inflammatory cause

c) Klebsiella rhinoscleromatis infection

d) Mycotic infection

Correct Answer - C

Ans. is 'c' i.e., Klebsiellarhinoscleromatis infection

Rhinoscleroma

- The causative organism is *Klebsiellarhinosclerontatisor Frisch bacillus,* which can be cultured from the biopsy material.
- The disease is endemic in several parts of world.
- In India, it is seen more often in northern than in the southern parts.
- Biopsy shows infiltration of submucosa with plasma cells, lymphocytes, *eosinophils, Mikulicz cells & Russell bodies.*
- The latter two are *diagnostic features* of the disease.
- The disease starts in the nose & extends to nasopharynx, oropharynx, larynx, trachea & bronchi.
- Mode of infection is unknown.
- *Both sexes of any age may* be affected.

78. Cauliflower ear is due to ?

a) Hematoma

b) Carcinoma

c) Fungal infection

d) Herpes

Correct Answer - A

Ans. is 'a' i.e., Hematoma

Hematoma of the auricle

- It is the collection of blood between the auricular cartilage and its perichondrium.
- It usually occurs due to blunt trauma and often seen in boxers, wrestlers and rugby players, therefore it is also called Boxer's ear.
- Extravasated blood may clot and then organise, resulting in typical deformity called, Cauliflower ear. If haematoma gets infected, *severe perichondritis* may set in.

79. Fowl smelling ear discharge with presence of pale granulation tissue in ear in an adolescent boy is suggestive of ?

a) Cholesteatoma

b) Exostosis

c) Otomycosis

d) Malignant otitis externa

Correct Answer - A
Ans. is 'a' i.e., Cholesteatoma
Fowl smelling ear discharge with presence of granulation tissue in earin adolescent boy is suggestive chronic suppurativeotits media of the unsafe type (atticoantral disease). Such patients have underlying cholesteatoma along with evidence of bone destruction.
Clinical features of cholesteatoma/atticoantral CSOM

- *Otorrhoea :-* Scanty, foul smelling discharge due to bone destruction.
- *Hearing loss :-* Initially conductive due to destruction of ossicles. Later sensorineural element may be added, which results in mixed hearing loss.
- *Bleeding :-* May occur from granulation or the polyp when cleaning the ear.
- Tympanic membrane show posterior marginal or attic perforation. Also granulation tissue and polyps may be present in ear.

80. Complication of trauma to danger area of face ?

a) Cavernous sinus infection

b) Meningitis

c) Visual loss

d) Loss of memory

Correct Answer - A

Ans. is 'a' i,e., Cavernous sinus infection

The area of upper lip and the lower part of nose is the danger area of face. It is due to that this area is the common site of infection. This area is drained by facial vein which communicates with the cavernous sinus through the superior ophthalmic vein and pterygoid venous plexus through the emissary vein.

In case of any infection of this area it may spread to the cavernous sinus causing infection and/or thrombosis.

81. Presence of delta sign on contrast enhanced CT SCAN suggests presence of ?

a) Lateral Sinus thrombophlebitis

b) Cholesteatoma

c) Cerebellar abscess

d) Mastoiditis

Correct Answer - A

Ans. is 'a' i.e., Lateral Sinus thrombophlebitis

LATERAL SINUS THROMBOPHLEBITIS (SIGMOID SINUS THROMBOSIS)

Lateral or sigmoid sinus thrombophlebitis arises from inflammation in the adjacent mastoid. It may occur as a complication of : ?

i. Acute coalescent mastoiditis
i. CSOM and cholesteatoma

Clinical features

- Hectic Picket-Fence type of fever with rigor.
- Headache, Progressive anemia and emaciation.
- *Griesinger's sign :* - odema over the posterior part of mastoid due to thrombosis of mastoid emissary veins.
- Papilloedema
- Tobey-Ayer test :- Compression of vein on the thrombosed side produces no effect while compression of vein on healthy side produces rapid rise in CSF pressure which will be equal to bilateral compression of jugular veins.
- *Crowe-Beck test :-* Pressure on jugular vein of healthy side produces engorgement of retinal veins. Pressure on affected side does not

produce such change.

- Tenderness along jugular vein
- Imaging studies
- Contrast-enhanced CT scan can show sinus thrombosis by typical *delta-sign.* It is a triangular area with rim enhancement, and central low density area is seen in posterior cranial fossa on axial cuts.
- Delta-sign may also be seen on contrast enhanced MRI.

82. Ostmann fat pad is related to ?

a) Ear lobule

b) Buccal mucosa

c) Eustachian tube

d) Tip of nose

Correct Answer - C
Ans. is 'c' i.e., Eustachian tube
There are small fat bodies located infermedial to Eustachian tube.
These are called Ostmann fat pads.
They are important in normal closure of eustachian tube and preventing transmission of nasopharyngeal pressure to middle ear.
These fat pads are absent in Patulous tube syndrome.

83. Which of the following structures is not at immediate risk of erosion by cholesteatoma ?

a) Long process of incus

b) Fallopian canal containing facial nerve

c) Horizontal/ lateral semicircular canal

d) Base plate of stapes

Correct Answer - D
Ans. is 'd' i.e., Base plate of stapes

- Cholesteatoma has the property to destroy the bone by virtue of the enzymes released by it.
- Structures immediately at the risk of erosion are : -

i. Long process of incus.
i. Fallopian canal containing facial nerve.
i. Horizontal / lateral semicircular canal

84. When the patient fails to understand normal speech, but can understand shouted or amplified speech the hearing loss, is termed ?

a) Mild hearing loss

b) Moderate hearing loss

c) Severe hearing loss

d) Profound hearing loss

Correct Answer - C
Ans. is 'c' i.e., Severe hearing loss

Severe hearing loss

What is severe hearing loss? On average, the most quiet sounds heard by people with their better ear are between 70 and 95 dB. People who suffer from severe hearing loss will benefit from powerful hearing aids, but often they rely heavily on lip-reading even when they are using hearing aids. Some also use sign language.

85. Most common site for carcinoma pharynx in females suffering from plummer vinson syndrome is

a) Post cricoid region

b) Posterior wall

c) Lateral wall

d) Pyriformis fossa

Correct Answer - A

Ans. is 'a' i.e., Post cricoid

Plummer-Vinson syndrome

- Plummer-Vinson syndrome, also known as Brown-Kelly-Paterson syndrome or sederopenic dysphagia, seen in middle aged edentulous women.
- The plummer Vinsion Paterson Brown Kelly Syndrome is characterized by : -
- *Dysphagia*
- *Chronic iron deficiency anemia*
- *Atrophic oral mucosa and glossitis*
- *Brittle, spoon-shaped fingernails (Koilonychia)*
- The cause of dysphagia is usually a *cervical esophageal web,* but abnormal pharyngeal and esophageal motility may play a role.
- The syndrome characterstically occurs in *middle aged edentulous* (without teeth) women.
- It is *a premalignant lesion.* Approximately 10% of patient develop *squamous cell Ca* of esophagus, oral cavity or the hypopharynx.
- As iron-deficiency anemia is a common finding, it is also known as *sideropenic dysphagia.*

- *Carcinoma develops in post-cricoid region.*

86. Pyriform fossa is situated in ?

a) Oropharynx

b) Hypopharynx

c) Nasopharynx

d) None of the above

Correct Answer - B
Ans. is 'b' i.e., Hypopharynx
Pyriform fossa is a part of laryngopharynx (hypopharynx)

87. Incisura terminalis is between ?

a) Tragus and crux of helix

b) Ear lobule and antihelix

c) Antihelix and external auditory meatus

d) Tragus and ear lobule

Correct Answer - A
Ans. is 'a' i.e., Tragus and crux of helix
Incisura ternzinalis is the area between the tragus and crus of helix

88. Graft for myringoplasty

a) Temporalis fascia

b) Iliacus fascia

c) Coles fascia

d) I hotibial band

Correct Answer - A
Ans. is 'a' i.e., Temporalis fascia
Graft material used for myringoplasty are :
i. *Temporalis fascia (most common)*
i. Tragal cartilage
i. *Perichondrium from the tragus*
v. Vein

89. Which of the following is not a derivative of the middle ear cleft ?

a) Semicircular canal

b) Mastoid air cell

c) Tympanic cavity

d) Eustachian tube

Correct Answer - A
Ans. is 'a' i.e., Semicircular canal
The middle - ear cleft in the temporal bone includes :?
i. Eustachian tube
i. The middle ear (tympanic cavity)
i. Aditus which leads posteriorly to the mastoid antrum and air cells.

90.

Exostosis due to repetitive exposure to cold water is common in which part of the temporal bone?

a) Squamous part

b) Tympanic part

c) Ptreous part

d) Mastoid part

Correct Answer - B
Ans. is 'b' i.e., Tympanic part
Surfer's ear

- It is the common name for an exostosis or abnormal bone growth within the external auditory canal.
- Surfer's ear is not the same as swimmer's ear, although infection can result as a side effect.
- Irritation from cold wind and water exposure causes the bone surrounding the ear canal to develop lumps of new bony growth which constrict the ear canal. The condition is so named due to its prevalence among cold water surfers. Cold water surfers experience surfer's ear at about six times the rate of warm water surfers.
- Common site for surfer's ear is external auditory canal. Tympanic part of the temporal bone is a U shaped curved bony plate that forms most of the part of the external auditory canal. Thus exostosis is common in the tympanic part of the temporal bone.
- Note: Parts of temporal bone are: squamous, tympanic, styloid, petrous, and mastoid.

91. Ohgren's line passes from ?

a) Medial canthus to angle of mandible

b) Lateral canthus to angle of mandible

c) Medial canthus to mastoid process

d) Lateral canthus to mastoid process

Correct Answer - A
Ans. is 'a' i.e., Medial canthus to angle of mandible

92. Passavant ridge ?

a) Superior constrictor and palatopharyngeus

b) Inferior constrictor and palatopharyngeus

c) Superior constrictor and palatoglossus

d) Inferior constrictor and palatoglossus

Correct Answer - A

Passavant ridge

- Near the superior margin of pharynx, a few fibres of superior constrictor blend with a band of muscle fibres belonging to the palatopharyngeus muscle.
- These fused fibres form a band or ring around the posterior wall and sidewalls of the nasopharyngeal isthumus.
- When the soft palate is elevated this muscle band appears as a ridge is known as passavant's ridge.

93. Rhinolith can cause

a) Nasal obstruction

b) Epistaxis

c) Epiphora

d) All of the above

Correct Answer - D

- A rhinolith is a calculus present in the nasal cavity.
- The word is derived from the roots rhino- and -lith, literally meaning "nose stone".
- A rhinolith usually forms around the nucleus of a small exogenous foreign body, blood clot or secretion by slow deposition of calcium and magnesium salts.
- Over a period of time, they grow into large irregular masses that fill the nasal cavity.
- **They may cause pressure necrosis of the nasal septum or lateral wall of nose leading to nasal obstruction, epistaxis, headache, sinusitis and epiphora.**

94. All of the following are true about malignant otitis externa except:

a) ESR is used for follow up after treatment

b) Granulation tissues are seen on superior wall of the external auditory canal

c) Severe hearing loss is the chief presenting complaint

d) Pseudomonas is the most common cause

Correct Answer - C
Ans. c. Severe hearing loss is the chief presenting complaint
Severe hearing loss is not the chief presenting complaint malignant otitis externa.
Malignant Otitis Externa:
Characterized by granulation tissue in external auditory canal at the junction of bone and cartilage.
MC organismz Pseudomonas aeruginosa
ESR is raised, used for follow up of treatment

95. All are true about Rhinoscleroma, except ?

a) Mikulicz cells

b) Caused by fungus

c) More common in Northern area

d) Woody nose

Correct Answer - B
Ans. is 'b' i.e., Caused by fungus

- Rhinoscleroma is caused by a bacterium.

Rhinoscleroma

- The causative organism is Klebsiella rhinoscleromatis or Frisch bacillus, which can be cultured from the biopsy material.
- The disease is endemic in several parts of world.
- In India, it is seen more often in northern than in the southern parts.
- Biopsy shows infiltration of submucosa with plasma cells, lymphocytes, eosinophils, Mikulicz cells & Russell bodies.
- The latter two are diagnostic features of the disease.
- The disease starts in the nose & extends to nasopharynx, oropharynx, larynx, trachea & bronchi.

Mode of infection is unknown.

- Both sexes of any age may be affected.
- Clinical features of rhinoscleroma
- The disease runs through the following stages :?

a. Atrophic stage : It resembles atrophic rhinitis and is characterised by foul smelling purulent nasal discharge and crusting.

b. Granulomatous stage : Granulomatous nodules form in nasal mucosa. There is also subdermal infiltration of lower part of external nose and upper lip giving a 'woody' feel. Nodules are painless and

non-ulcerative.

c. Cicatricial stage : This causes stenosis of nares, distortion of upper lip, adhesions in the nose, nasopharynx and oropharynx. There may be subglottic stenosis with respiratory distress.

- Biopsy of rhinoscleroma shows infiltration of submucosa with plasma cells, lymphocytes, eosinophils, Mikulicz cells and Russell bodies. The latter two are the diagnostic features of the disease.
- Treatment
- Both streptomycin & tetracycline are given together for minimum of 4-6 wks. Steroid can be combined to reduce fibrosis. Surgical treatment may be required to establish the airway and correct nasal deformity

96. Associated with objective tinnitus?

a) Meiners disease

b) Acoustic neuroma

c) Ear wax

d) Glomus tumor

Correct Answer - D
Ans. is `d' i.e., Glomus tumor

Tinnitus

- Tinnitus is ringing sound or noise in the ear.
- The characteristic feature is that the origin of this sound is within the patient.
- Two types of tinnitus have been described : ?

a. Subjective

I. Otologic	**II . Non-otologic**
• Impacted wax	Disease of CNS
• Fluid in the middle ear	Anaemia
• Acute and chronic otitis media	Arteriosclerosis
• Abnormally patent eustachian tube	Hypertension
• Meniere's disease	Hypotension
• Otosclerosis	Hypoglycaemia

97. Which drug is to be given in a truck driver for rhinitis ?

a) Cetrezine

b) Hydroxyzine

c) Promethazine

d) Buclizine

Correct Answer - A
Ans. is 'a' i.e., Cetrezine

98. Schwartze sign seen in?

a) Glomus Jugulare

b) Otosclerosis

c) Meniere's diseases

d) Acoustic neuroma

Correct Answer - B
Ans. is 'b' i.e., Otosclerosis

Symptoms of otosclerosis

- Hearing loss :- Bilateral conductive deafness which is painless and progressive with insidious onset. In cochlear otosclerosis sensorineural hearing loss also occur along with conductive deafness.
- Paracusis willissii :- An otosclerotic patient hears better in noisy than quiet surroundings.
- Tinnitus :- More common in cochlear otosclerosis.
- Speech :- Monotonous, well modulated soft speech.
- Vertigo :- is uncommon.

Signs in otosclerosis

- Tympanic membrane is quite normal and mobile.
- In 10% of cases flamingo - pink blush is seen through the tympanic membrane called as Schwartze sign.
- Various tests show conductive hearing loss.

Tuning fork tests in otosclerosis

- As otosclerotic patients have conductive deafness, the tuning fork tests results will be as follows :?

1. Rinnes :- Negative
2. Webers :- Lateralized to the ear with greater conductive loss.
3. Absolute bone conduction (ABC) :- Normal (can be decreased in

cochlear otosclerosis).

- Gelles test :- No change in the hearing through bone conduction when air pressure of ear canal is increased by Siegle's speculum.

Audiometry in otosclerosis

- Audiometry is one of the important tools in evaluation of a patient of otosclerosis.Various audiometric tests are :?

1. Pure tone audiometry

- Shows loss of air conduction, more for lower frequencies with characteristic rising pattern. Bone conduction is normal. However in some cases, there is a dip in bone conduction curve which is maximum at 2000 Hz (2 KHz) and is called the Carhart's notch.

2. Impedance audiometry

- Impedance audiometry shows :-
- Tympanometry
- Patient with early disease may show type A tympanogram (because middle ear areation is not affected) Progressive stapes fixation results in classical As type tympanogram.
- Acoustic (stapedial reflex)
- It is one of the earliest sign of otosclerosis *and preceedes the development of airbone gap. In early stage, diphasic on-off pattern is seen in which there is a brief increase in compliance at the onset and at the termination of stimulus occurs. This is* pathognomonic of otosclerosis. *In later stage* the reflex is *absent.*

99. Galle's test is used for ?

a) Otosclerosis

b) Juvenile angiofibroma

c) Nasal polyp

d) None

Correct Answer - A
Ans. is 'a' i.e., Otosclerosis

Gelle's test

- It is a bone conduction test and examines the effect of increased air pressure in ear canal on hearing.
- Increased air pressure in ear canal (by Siegle's speculum) pushes the tympanic membrane and ossicles inwards which raises the intralabyrinthine pressure and causes immobility of basilar membrane and decreased hearing.
- However, if ear ossicles are already fixed or disconnected, the pressure cannot be transfered to inner ear
- No change in hearing in this situation.
- Base of vibrating tuning fork is placed on mastoid process and air pressure in ear canal increased (by Siegle's speculum).
- Interpretation are : -
- Positive Gelle's (decreased hearing on increased pressure)→ Normal or sensorineural hearing loss. h)
- Negative Gelle's (No effect of pressure change in hearing) → Disconnected or fixed ossicular chain.

100. Macula is stimulated by ?

a) Gravity

b) Head position change

c) Linear acceleration

d) All of the above

Correct Answer - D
Ans. is 'd' i.e., All of the above

- Vestibular apparatus (Peripheral part of vestibular system)
- The vestibular apparatus *within the inner ear* detects head motion and position and transduces this information to a neural signal. The vestibular apparatus has following parts :-

101. Paranasal sinuses present at birth ?

a) Frontal and maxillary

b) Ethmoid and maxillary

c) Frontal and ethmoid

d) Sphenoid and ethmoid

Correct Answer - B
Ans. is 'b' i.e., Ethmoid and maxillary
Maxillary sinus → 4 Develop at birth; completely develop at 9 years
Ethmoidal sinus → Develop at birth; completely develop at late puberty
Frontal sinus → Develop at 2 year; completely develop at late adolescence
Spenoid sinus → Develop at 3-5 years; completely develop at 12-15 years

102. Most common bone affected by otosclerosis

a) External auditory canal

b) Bony labyrinth

c) Mastoid process

d) None

Correct Answer - B
Ans. is 'b' i.e., Bony labyrinth

- Otosclerosis is a primary disease of the bony labyrinth.
- There is abnormal bone growth that causes hearing loss.
- There is altered bone remodeling.
- Normally, the typical human otic capsule remodeling rate is extremely low.
- In otosclerosis, normal inhibition of bone remodeling is lost resulting in foci of bone remodeling.
- When remodeled bone bridges the stapediovestibular joint, it fixates the joint and impedes sound transmission manifested as conductive hearing loss.
- The most common site of disease is promontory in the region of the anterior margin of oval window, and in advanced cases the stapes become ankylosed in position by a mass of new spongy bone.
- Other sites, which may be involved, are round window area, stapedial footplate, internal auditory canal, and semicircular canal.

103. Best view for nasal bone ?

a) Lateral

b) Towne's

c) Cald-well

d) Submentovertical

Correct Answer - A
Ans. is 'a' i.e., Lateral

104. Lomard's test is used to diagnosis ?

a) Conductive hearing loss

b) Sensorineural hearing loss

c) Mixed hearing loss

d) Non-organic hearing loss

Correct Answer - D
Ans. is 'd' i.e., Non-organic hearing loss

105. True about serous otitis media are all except ?

a) Also called glue ear

b) Affect school going children

c) Type C tympanogram

d) Fluid in middle ear

Correct Answer - C
Ans. is `c' i.e., Type C tympanogram

Serous otitis media

- Serous otitis media (SOM) has many synonyms : Serous otitis media, otitis media with effusion, glue ear, non-suppurative otitis media, mucoid otitis media, silent otitis media. SOM is an insidious condition in which there is thick or sticky non-purulent fluid behind the eardrum in the middle ear, but there is no ear infection, i.e., effusion of middle ear without infection. Fluid in the middle ear is sterile. SOM occurs most commonly in school going children and SOM is the commonest cause of childhood hearing loss.
- Etiopathogenesis

1. Eustachian tube dysfunction

- Eustachian tube dysfunction, coupled with recurrent upper respiratory tract infection is the most important factor in the development of SOM. Normally eustachian tube helps to drain fluids to prevent them from building up in the ear. In Eustachian tube dysfunction, it is unable to drain the fluid. Following can cause Eustachian tube block :-

1. Respiratory tract infection :- Adenoid, rhinitis, tonsillitis, sinusitis.
2. Allergies
3. Benign and malignant tumor of nasopharynx.

2. Unresolved otitis media

- Inadequate antibiotic therapy in acute suppurative otitis media may inactivate infection but fails to resolve it completely. Low grade infection lingers on and acts as stimulus for mucosa to secrete more fluid.
- Clinical features
- Unlike children with an ear infection (ASOM), children with SOM do not act sick. o The only presenting symptom may be hearing loss with fullness in ear.
- Otoscopic finding of SOM
- Air bubbles on the surface of ear drum
- Fluid behind the eardrum.
- Dullness of the eardrum when a light is used, with loss of light reflex. o Eardrum may appear yellow, grey or bluish in colour.
- Retracted eardrum with decreased mobility
- Tympanometry shows type B tympanogram.

106. Cause of myringosclerosis ?

a) Genetic

b) Grommet insertion

c) Otosclerosis

d) None

Correct Answer - B
Ans. is 'b' i.e., Grommet insertion

Tvmpanosclerosis

- Tympanosclerosis is a condition in which there is calcification of tissue in the eardrum (tympanic membrane) and middle ear.
- Tympanosclerosis may be classified as : -
1. Myringosclerosis : - Involving only the tympanic membrane.
2. Intratympanic tympanosclerosis : - Involving other middle ear sites : ossicular chain or, rarely, the mastoid cavity.
- Exact etiology of tympanosclerosis is not known. It may be an abnormal healing process and most commonly occurs in cases of serous otitis media as a complication of ventilation tube (gourmet) insertion.
- Characteristic chalky white patches are seen on inspection of the eardrum. It is worth noting that cholesteatoma may look similar but the whiteness appears behind, rather than in/on the tympanum.
- Otherwise tympanosclerosis is asymptomatic. Conductive hearing loss may occur in some cases.

107. Delta-sign is seen in ?

a) Petrositis

b) Acute mastoiditis

c) Sigmoid sinus thrombosis

d) Glomus tumor

Correct Answer - C
Ans. is 'c' i.e., Sigmoid sinus thrombosis

- Contrast-enhanced CT scan can show sinus thrombosis by typical *delta-sign.* It is a triangular area with rim enhancement, and central low density area is seen in posterior cranial fossa on axial cuts.
- Delta-sign may also be seen on contrast enhanced M RI.

108. Trismus is seen in commonly ?

a) Ludwig angina

b) Quinsy

c) Retropharyngeal abscess

d) Parapharyngeal abscess

Correct Answer - B
Ans. is 'b' i.e., Quinsy

- Trismus is inability to open-mouth.
- Normal opening of mouth ranges between 25-50mm.
- Any value less than this is known as trismus (roughly the opening should permit a minimum of three fingers when inserted sideways).
- Causes of quinsy are :?

A. Common causes

- Infection around impacted third molor
- Quinsy (peritonsillar abscess)
- Submucous fibrosis
- TM joint dysfunction

B. Less common causes

- Ludwings angina
- Parotid gland infection and tumors
- Malignant otitis externa or furncle in external auditory canal.
- Parapharyngeal and retropharyngeal abscess
- Carcinoma mandible
- Tetanus
- Radiation therapy
- Carcinoma check
- Malignant hyperthermia
- Coming to the question

- Trismus can occur in all the given options.
- However, it is most common and most characteristic of quinsy (among the given options).

109. SNHL is seen in all except?

a) Nail patella syndrome

b) Distal RTA

c) Batter syndrome

d) Alport syndrome

e) None

Correct Answer - E
Ans. is 'e' i.e.None

- All the given options are causes of sensorineural hearing loss.

Congenital causes of SNHL

Treacher collin syndrome
Alport's syndrome
Pendred syndrome
Crouzon's disease
Bartter syndrome
Leopard syndrome
Refsum syndrome
Waardenburg syndrome
Fabry disease

Usher's syndrome
Hurler's syndrome
Klippel feil syndrome
Type 1 (distal) Renal tubular acidosis
Jervell & lange Neilson syndrome
Biotinase deficiency
Albinism
MELAS
Trisomy 13, 15, 21

Michel's aplasia
Mondini's anomaly
Schibe's and Alexander's anomalies
LThl's anomaly
Michel's aplasia
Nail - patella syndrome
Alstrom syndrome
Brachio - oto - renal (BOR) syndrome
Cockayne's syndrome

110. Red line in pure tone audiometry is for -

a) Bone conduction

b) Air conduction

c) Right ear

d) Left ear

Correct Answer - C
Ans. is 'c' i.e., Right ear

111. Transverse fracture of maxilla is ?

a) Le Fort-1

b) Le Fort-2

c) Le Fort-3

d) Cranifacial disruction

Correct Answer - A
Ans. is 'a' i.e., Le Fort-1

- It is classified into 3 types : ?

1. Le Fort I (transverse) fracture runs above and parallel to the plate. It crosses lower part of nasal septum, maxillary antra and the pterygoid plates.
2. Le Fort II (pyramidal) fracture passes through the root of nose, lacrimal bone, floor of orbit, upper part of maxillary sinus and pterygoid plates. This fracture has some features common with the zygomatic fractures.
3. Le Fort III (craniofacial dysfunction). There is complete separation of facial bones from the cranial bones. The fracture line passes through root of nose, ethmofrontal junction, superior orbital fissure, lateral wall of orbit, frontozygomatic and temporozygomatic sutures and the upper part of pterygoid plates.

112. Which of the following laryngeal cartilage is hyaline?

a) Epiglottis

b) Comiculate

c) Cricoid

d) Cuneiform

Correct Answer - C
Ans. is 'c' i.e., Cricoid

Hyaline cartilages	**Elastic cartilages (do not ossify)**
Thyroid cartilage	Epioglottis
Cricoid cartilage	Corniculate
Basal part of arytenoid cartilage	Cuneiform
Processes of arytenoid	

113. All of the following cranial nerves are involved in Acoustic neuroma, except ?

a) Vagus

b) Glossopharyngeal

c) Oculomotor

d) Facial

Correct Answer - C
Ans. is 'c' i.e., Oculomotor

Clinical features of acoustic neuroma

- The clinical features depend on the extent of tumor and involved structure :?
- When tumor is still confined to the internal auditory canal
- Cochleovestibular symptoms are the earliest symptoms of acoustic neuroma when tumour is still confined to internal auditory canal. The commonest presenting symptoms are unilateral deafness or tinnitus, or a combination of both. Hearing loss is retrocochlear sensorineural type. There is marked difficulty in understanding speech, out of proportion to the pure tone hearing loss, a characteristic feature of acoustic neuroma. Vestibular symptoms are imbalance or unsteadiness. True vertigo is very rare.
- When tumor extends beyond IAC and involves other structures
- V^hcranial nerve :- It is the earliest nerve to be involved. There is reduced corneal sensitivity and loss of corneal reflex which is the earliest sign of acoustic neuroma. Numbness or paraesthesia of face may occur. Involvement of Vth nerve indicates that tumor is roughly 2.5 cm in diameter and occupies the CP angle.
- VIP nerve :- Sensory fibres of facial nerve are involved. There is hypoesthesia of posterior meatal wall (Hitzelberg's sign), loss of

taste, and loss of lacrimation on Schirmer's test. Motor fibres are more resistant.

- IXth and A' nerves :- Dysphagia and hoarseness due to palatal, pharyngeal and laryngeal paralysis.
- Brainstem :- Ataxia, weakness, numbness of arms & legs, exaggerated tendon reflexes.
- Cerebellum :- Ataxia, Dysdiadochokinesia, Nystagmus.
- Due to raised ICT :- Headache, neusea, vomiting, diplopia due to VI' nerve involvement, and papilloedema.

114. Wave I in brain-stem response audiometry arises from?

a) Cochlear nerve

b) Superior olivary complex

c) Lateral lemniscus

d) Inferior colliculus

Correct Answer - A
Ans. is 'a' i.e., Cochlear nerve

Brain Stem Response Audiometry (BERA)

- It is a non-invasive procedure which objectively helps to find the integrity of central auditory pathway through the VIII nerve, pons and mid brain. It is accurate to within 10 or 15 dB of the psychoacoustic thereshold. It is the most reliable audiological method of differentiating between cochlear and Retrocochlear hearing losses. It is an objective test and can be done under sedation.
- It is used both as a screening test and as a definative hearing assessment test in children. Best test to detect deafness in infants (reliably recorded even from premature infants of 30 weeks gestational age) and mentally retarded or malingering subjects. It is also used for Identification of the site of lesion in Retrocochlear pathologies and to diagnose brainstem pathology e.g. multiple sclerosis or pontine tumor.

Waves of BERA

- In a normal person, 7 waves are produced in first 10 miliseconds. The first, third and fifth waves are most stable and are used in measurements. Site of origin of waves are :-

Wave I	Distal part of Eighth nerve
Wave II	Proximal, part of Eighth cranial nerve

Wave III	Cochlear nucleus
Wave IV	Superior olivary complex
Wave V	Lateral leminiscus
Wave VI & VII	Inferior colliculus

115. Site of glomus jugulare?

a) Epitympanum

b) Hypotympanum

c) Mesotympanum

d) Internal ear

Correct Answer - B
Ans. is 'b' i.e., Hypotympanum

Glomus tumor

- Glomus tumor is the most common benign tumor of middle ear.
- It arises from the glomus bodies, therefore named Glomus tumor.
- It is well recognised that glomus tumors arise from paraganglions, which are normally occuring structures usually found in close association with sympathetic ganglions along the aorta and its main branches.
- The chief cells (paraganglionic cells) of the paraganglions are of neural crest origin and are components of the diffuse neuroendocrine system (DNES).
- These paraganglionic cells are derived from embryonic neuroepithelium (neural crest).
- Glomus tumors are also referred to as chemodectomas or nonchromaffin paragangliomas.
- There are two types of glomus tumors :-
- Glomus jugulare
- These glomus tumors arise from the dome of the internal jugular vein in the hypotympanum and jugular foramen. In jugular foramen they can invade IX to XII cranial nerves.
- Glomus tympanicum
- They arise from the promontory of the middle ear along the course

of the tympanic branch of the IXth cranial nerve.

- Although rare, glomus tumors are the most common tumor of the middle ear and are second to acoustic neuroma (vestibular schwannoma) as the most common tumor of the temporal bone.
- It is more common in females with female to male ratio of 3-6 : 1.
- Glomus jugulare tumors have also been noted to be more common on the left side, especially in females. o Most tumors occur in patient 40-60 years.
- Multicentric tumors are found in 3-10% of sporadic cases and in 25-50% of familial cases.

116. Frey's syndrome is caused by ?

a) Post traumatic nerve fibres of facial nerve with parasympathetic of auriculotemporal nerve

b) Greater auricular with auriculotemporal nerve

c) Facial nerve with greater auricular nerve

d) None

Correct Answer - A
Ans. is 'a' i.e., Post traumatic nerve fibres of facial nerve with parasympathetic of auriculotemporal nerve

Frey's syndrome (gustatory sweating)

- Gustatory sweating or Frey's syndrome involves post-parotidectomy facial sweating and skin flushing while eating.
- The symptoms usually occur several months or even years after parotid surgery.
- The likely pathophysiology is aberrant regeneration of postganglionic secretomotor parasympathetic nerve fibres (originating from the otic ganglion) misdirected through several axonal sheaths of post-ganglionic sympathetic fibres feeding the sweat glands. These sympathetic fibres are to the sweat glands of the skin in the dissected field.
- The frey's syndrome is likely due to injury to auriculotemporal nerve with faulty regeneration, therefore Frey's syndrome is also known as Auriculotemporal syndrome.
- A variant of Frey's syndrome in which there is gustatory facial flushing but not sweating, occurs following facial paralysis due to faulty regeneration following injury to the facial nerve. So, Frey's syndrome is not limited to parotid surgery with injury to auriculotemporal nerve.

117. Killions incision is used for?

a) Septoplasty

b) SMR

c) Proof puncture

d) Modified radical mastoidectomy

Correct Answer - A
Ans. is 'a' i.e., Septoplasty
Technique of septoplasty
1. Infiltrate the septum with 1% lignocaine with adrenaline 1:100,000.
2. In cases of deviated septum, make a slightly curvilinear incision, 2-3 mm above the caudal end of septal cartilage on the concave side (Killian's incision). In case of caudal dislocation, a transfixion or hemitrans fixion (Freer's) incision is made.
3. Raise mucoperichondrial/mucoperiosteal flap on one side only.
4. Separate septal cartilage from the vomer and ethmoid plate and raise mucoperiosteal flap on the opposite side of septum.
5. Remove maxillary crest to realign the septal cartilage.
6. Correct the bony septum by removing the deformed parts.
Deformed septal cartilage is corrected by various methods, such as :

- Scoring on the concave side
- Cross-hatching or morselizing
- Shaving
- Wedge excision
- Further manipulations like realignment of nasal spine, separation of septal cartilage from upper lateral cartilages, implantation of cartilage strip in the columella or the dorsum of nose may be required.

7. Trans septal sutures are put to coapt mucoperichondrial flaps

7. Trans-septal sutures are put to coapt mucoperichondrial flaps.
8. Nasal pack.

118. Turban epiglottis is seen in ?

a) TB

b) Leprosy

c) Laryngeal papilloma

d) Epiglottitis

Correct Answer - A
Ans. is 'a' i.e., TB
Tubercular larvn_gitis

- Tubercular laryngitis is almost always secondary to pulmonary lesions, mostly affecting males in middle age (20-40 years). Disease affects the posterior third of larynx more commonly than anterior part.The parts affected in descending order of frequency are :- i) Interarytenoid fold, ii) Ventricular band, iii) Vocal cords, iv) Epiglottis
- Clinical features
- Weakness of voice with periods of aphonia earliest symptoms. o Hoarsness, cough, dysphagia (odynophagia)
- Referred otalgia
- Laryngeal examination in TB laryngitis
- Hyperaemia of the vocal cord in its whole extent or confined to posterior part with impairment of adduction is the first sign.
- Swelling in the interarytenoid region giving a mammilated appearance.
- Ulceration of vocal cord giving mouse-nibbled appearance.
- Superficial ragged ulceration on the arytenoids and interarytenoid region.
- Granulation tissue in interarytenoid region or vocal process of arytenoid.
- Pseudoedema of the epiglottis "turban epiglottis".

- Swelling of ventricular bands and aryepiglottic folds.
- Marked pallor of surrounding mucosa.

119.

Most common part of larynx involved in TB ?

a) Anterior

b) Posterior

c) Middle

d) Anywhere

Correct Answer - B
Ans. is 'b' i.e., Posterior

- Essential otolaryngology 2"^{d}/e p. 1139]
- Disease affects the posterior third of larynx more commonly than anterior part.
- The parts affected in descending order of frequency are :- i) Interarytenoid fold, ii) Ventricular band, iii) Vocal cords, iv) Epiglottis.

120. Most common cause of ASOM is?

a) Meningococci

b) Pneumococci

c) H influenzae

d) Moraxella

Correct Answer - B
Ans. is 'b' i.e., Pneumococci

- ASOM is an acute inflammation of middle ear cleft caused by pyogenic organism.
- It is worth noting that ASOM is the infection of middle ear cleft, i.e., middle ear (tympanic cavity), Eustachian tube, Attic, Aditus, antrum and mastoid air cells.
- ASOM is especially common in infants and children.
- Most of the time ASOM usually follows respiratory tract infections (i.e., acute tonsillitis, common cold or influenza) and the infection travel up by the eustachian tube to the middle ear.
- The most common causative organism is streptococcus pneumoniae. Other common organisms are H. influenzae and Moraxella catarrhalis. Less common causative organisms are streptococcus pyogenes, staphylococcus aureus and E.coli.

121. Defective function of which of the following causes hyperacusis ?

a) VIII nerve

b) 7th nerve

c) Stapedius muscles

d) Any of the above

Correct Answer - D
Ans. is 'd' i.e., Any of the above

Hyperacusis

- Hyperacusis is hearing normal voice as louder.
- The protective mechanisms a normal ear employs to minimize the harmful effects of loud noise are malfunctioning in hyperacusis.
- So, noise may seem too loud even with hearing protection.
- There is some speculation that the *efferent portion of the auditory nerve* is selectively damaged while the hair cells that allow us to hear pure tones in an audiometric evaluation remains intact.
- Some have said it involves *direct malfunction of facial nerve;* as a result, *the stapedius muscle* is unable to dampen sound.

122. Paranasal polyp CT view?

a) Corona!

b) Axial

c) Sagital

d) 3D

Correct Answer - A
Ans. is 'a' i.e., Coronal

- Both coronal and axial view are used, but coronal views are best to study paranasal sinus polyps.

123. Vallecula sign is seen in ?

a) TB laryngitis

b) Vocal nodule

c) Inverted papilloma

d) Acute epiglottitis

Correct Answer - D
Ans. is 'd' i.e., Acute epiglottitis
- There are two important radiological signs in *acute* epiglottitis :?
1. Thumb sign
2. Vollecula sign

124. Most common cause of otomycosis ?

a) Histoplasma

b) Rhinosporidium

c) Aspergillus

d) Actinomyces

Correct Answer - C
Ans. is 'c' i.e., Aspergillus

Otomycosis

- Otomycosis, also called acute fungal otitis externa, describes a fungal or yeast infection of the external auditory meatus.
- Saprophytic fungi potentially residing in the ear canal include Aspergillus, Candida albicans, Phycomycetes, Rhizopus, Actinomyces, and Penicillium.
- Under certain conditions of increased heat, humidity, glucose concentration (diabetes), immunosuppression, or overuse of systemic or topical antibiotics and steroids, these saprophytic fungi can become pathogenic.
- Aspergillus niger accounts for 90% of otomycosis infections.
- Other common organisms are candida albicans (2"a most common) and Aspergillus fumigatus.
- Less common organisms are Phycomycetes, Rhizopus, Actinomyces and Penicillium

125. Facial nerve palsy can be caused by ?

a) Cholesteatoma

b) Multiple sclerosis

c) Mastoidectomy

d) All of the above

Correct Answer - D
Ans. is 'd' i.e., All of the above
Causes of facial paralysis

- Central :- Brain abscess, pontine glioma, Polio, multiple sclerosis
- Intracranial part (cerebellopontine angle) :- Acoustic neuroma, meningioma, congenital cholesteatoma, metastatic carcinoma, meningitis
- Intratemporal part :-
- Idiopathic :- Bell's palsy, Melkersson's syndrome
- Infections :- ASOM, CSOM, Herpes zoster oticus, malignant otitis externa
- Trauma :- Surgical (mastoidectomy, stapedectomy), accidental (fractures of temporal bone)
- Neoplasms :- Malignancies of external and middle ear, glomus jugular, facial nerve neuroma, metastasis (from breast, lung etc).
- Extracranial part :- Malignancies or surgery or injury to parotid gland
- Systemic diseases :- Diabetes, hypothyroidism, uremia, PAN, Sarcoidosis (Heerfordt's syndrome), leprosy, leukaemia, demyelinating disease

126. Predisposing factor for Nasal myiasis ?

a) Allergic rhinitis

b) Vasomotor rhinitis

c) Atrophic rhinitis

d) Rhinitis medicomentosa

Correct Answer - C
Ans. is 'c' i.e., Atrophic rhinitis
Nasal myiasis (Maggots in nose)

- It results from the presence of ova of flies particularly chrysomia species in the nose which produce ulceration and destruction of nasal structure. Mostly seen in atrophic rhinitis when the mucosa becomes insensitive to flies laying eggs inside.
- Clinical features
- Initial symptoms (3-4 days maggots) :- Intense irritation, sneezing, headache, blood stained disharge, lacrimation. o Later :- Maggots may crawl out of nose and there is foul smell.
- Complications
- Destruction of nose, sinuses, soft tissues of face, palate and eyeball.
- Fistulae in nose and palate.
- Death occurs due to meningitis.
- Treatment
- Chloroform water or vapor must be instilled in order to anaesthetize or kill the maggots and so release their grip from the skin.

127.

Glomus tumor invading the vertical part of carotid canal. It is ?

a) Type B

b) Type CI

c) Type C2

d) Type C3

Correct Answer - C
Ans. **is** `c' i.e., Type **C2**

128. Unilateral sensorineural hearing loss may occur in?

a) Coronavirus

b) Mumps

c) Pertussis

d) Rotavirus

Correct Answer - B

Ans. is 'b' i.e., **Mumps**

Infections of labyrinth	**Acquired causes of SNHL**	**Systemic disorders**
Trauma to labyrinth or VIII nerve (Head injury, surgery etc)	Presbycusis	(DM, Hypothyroidism, Renal disorders)
Noise induced hearing loss	Meniere's disease	Multiple sclerosis
Ototoxic drugs	Acoustic neuroma	Smoking & Alcoholism
	Sudden hearing loss	

129. Fracture of which of the following bone causes leakage of cerebrospinal fluid through ear ?

a) Mastoid process

b) Petrous temporal

c) Ethmoid plate

d) Cribriform plate

Correct Answer - B
Ans. is `b' i.e., Petrous temporal

CSF otorrhea

- CSF otorrhea, i.e., *leakage of cerebrospinal fluid through ear structure,* is a rare but potentially life threatening situation that requires rapid intervention.
- The underlying etiology of spinal fluid leak *through temporal bone* is a violation of the bony and meningeal barriers that separate the subarachoid space from the middle ear and mastoid.
- This means that a defect must exist not only in the bone, but also in the dura matter.
- Causes of CSF otorrhea are : ?
  1. Congenital:- Defect in otic capsule.
  2. Acquired:- *More common* than congenital and cause are : -

1. Surgery:- Post-operative leakage is the most common cause of CSF otorrhea. Surgical causes are acoustic neuroma removal, skull base surgeries and sometimes mastoid surgery.
2. Trauma:- Fracture of petrous part of temporal can lead to CSF otorrhea.
3. Infection

3. Spontaneous:- It is without an obvious antecedent pathology. There may be some defect in the temporal bone.

130. Which of the following is a pneumatic bone ?

a) Parietal bone

b) Occipital bone

c) Mastoid process

d) None

Correct Answer - C
Ans. is 'c' i.e., Mastoid process

- Pneumatic bones are one which contain large air spaces lined by epithelium. Examples: maxilla, sphenoid, ethmoid, etc. They make the skull light in weight, help in resonance of voice, and act as air conditioning chambers for the inspired air.
- A bone that is hollow or contains many air cells called as penumatic bone.
- Examples are mastoid process of temporal bone, maxilla, ethmoid, sphlenoid and frontal bone. Very simple to remember last 4 as all four paransal sinuses are pneumatic bones.

131. Mulberry nasal mucosa is seen in ?

a) Lupus vulgaris

b) Vasomotor rhinitis

c) Atrophic rhinitis

d) None

Correct Answer - B
Ans. is 'b' i.e., Vasomotor rhinitis

- Vasomotor is a *nonallergic condition* that involves a constant runny nose, sneezing and nasal congestion, i.e., *the nose is stuffy or runny for reasons other than allergies and infections.* The exact etiology is unknown, but triggers include emotions, odors, poor air quality, spicy foods, and medication side effects. *Pathogenesis* include : -
- Parasympathetic overactivity
- Hyperactive nasal mucosa to several non-specific stimuli especially in women of 20-40 years.
- *Symptoms* of vasomotor rhinitis include excessive clear rhinorrhoea, nasal obstruction/congestion, irritation, paroxysmal sneezing and post-nasal drip. Nasal mucosa is hypertrophied & congested; and mucosa of turbinates may give *mulberry like appearance* and is pale to dusky red in colour.
- *Complications* of vasomotor rhinitis include hypertrophic rhinitis & sinusitis, and nasal polyp.
- *Mulberry nasal mucosa is also seen in chronic hypertrophic rhinitis*

132. All are seen in Samters triad except?

a) Asthma

b) Nasal polyp

c) Bacterial infection

d) Aspirin sensitivity

Correct Answer - C
Ans. is 'c' i.e., Bacterial infection
Samter's triad

- Samter's triad is a medical condition consisting of asthma, aspirin sensitivity, and nasaL'ethmoidal polyposis. It occurs in middle age (twenties and thirties are the most common onset times) and may not include any allergies. o Most commonly, the first symptom is rhinitis.
- The disorder typically progeses to asthma, then polyposis, with aspirin sensitivity coming last.
- The aspirin reaction can be severe, including an asthma attack, anaphylaxis, and urticaria in some cases. Patients typically react to other NSAIDS such as ibuprofen, although paracetamol is generally considered safe.
- Anosmia (lack of smell) is also typical, as the inflammation reaches the olfactory receptors in the nose.

133. Objective test in adenoids

a) Posterior rhinoscopy

b) Anterior rhinoscopy

c) Manual palpation

d) All of the above

Correct Answer - A
Ans. is 'a' i.e., Posterior rhinoscopy

134. Most common sinus to be involved in acute sinusitis?

a) Ethmoid

b) Maxillary

c) Sphenoid

d) Frontal

Correct Answer - B
Ans. is 'b' i.e., Maxillary

Most common sinus affected by sinusitis overall	Maxillary
Most common sinus affected in adult	Maxillary
Most common sinus affected in children	Ethmoid
Least common sinus affected	Sphenoid
Sinuses involved in order of frequency	Maxillary > Frontal > Ethmoid > Sphenoid

135. Queckensted test is done for ?

a) Glomus tumor

b) CSF rhinorrhea

c) Otosclerosis

d) Acoustic neuroma

Correct Answer - B
Ans. is 'b' i.e., CSF rhinorrhea

Detection of CSF Leak

1. Biochemical tests

- Concentrations of Glucose are higher in CSF than in nasal discharge. Glucose value > 30-40 mg% and protein value < 100 mg % (max 200 mg %) support a diagnosis of CSF leak.
- Presence of I3,transferrin is the most definitive test for detection of CSF and $I3_2$transferrin assay is the test of choice when a confirmatory test is needed, because of high sensitivity as well as specificity.
- I3-trace protein (prostaglandin D synthase) is also used, however it is nonspecific as it is also present in human testes, heart and seroma.

2. Basic clinical tests

- Tissue test (Handker chief test) : - Unlike nasal mucous, CSF does not cause a tissue to stiffen.
- Filter paper test : - Sample of nasal discharge on a filter paper exhibits a light CSF border and a dark central area of blood, i.e., double ring sign or halo sign.
- Queckensted test : - Compression of the jugular vein leas to increased CSF leak due to increase in ICP.
- Rhinoscopy : - Visualization of CSF leak from paranasal sinus.

3. CSF tracers

- Intrathecal fluorescein dye adminstration, radionuclide cisternography, CT cisternography.

136. Bilateral recurrent laryngeal nerve palsy is seen in all except ?

a) Thyroid carcinoma

b) Lymphadenopathy

c) Thyroid surgery

d) Aortic aneurysm

Correct Answer - D
Ans. is 'd' i.e., Aortic aneurysm

137. Most common cause of singer's nodule is ?

a) Infection

b) Allergy

c) Vocal abuse

d) None

Correct Answer - C
Ans. is 'c' i.e., Vocal abuse
Vocal nodule (singer's or screamer's nodule)

- Vocal nodule are benign noneoplastic growth on free edge of both the vocal cords at the junction of anterior 1/ 3 with posterior 2/3.
- This area is particularly vulnerable to trauma as this is the area of maximum vibration of the cord.
- The major cause is voice abuse, therefore it is most commonly seen in singers, actors, teachers, and howkers.
- Hoarseness is the most common symptom. Vocal fatigue and pain in neck on prolonged phonation are other symptoms.

Treatment

- Early cases of vocal nodules can be treated conservatively by educating the patient in proper use of voice. Many nodules especially in children, disappear with this treatment.
- Surgery is required for large nodules or long standing nodules in adults. *Microscopic (micorlaryngoscopic) excision* is the treatment of choice.

138. Mucoperichondrial flap in septoplasty is made on?

a) Alar cartilage

b) Septal cartilage

c) Maxillary spine

d) Sphenoid spine

Correct Answer - B
Ans. is 'b' i.e., Septal cartilage

Steps in septoplasty

- A unilateral incision is made in the mucoperichodrial flap at the lower border of septal cartilage on the left side in right handed persons.
- The mucoperichondrial flap is elevated on one side making an anterior tunnel.
- Another incision is made in the mucoperiosteum over the nasal spine on the same side, elevating the mucoperiosteum from nasal spine on both sides thus making two more tunnels called inferior tunnels. Two tunnels are joined by sharp dissection.
- Septal cartilage is then separated from vomero-ethmoid bones posteriorly and nasal spine inferiorly.
- Maxillary crest is removed to realign septal cartilage.
- Bony septal deformity is corrected by removing deformed part. Deformed septal cartilage is corrected.
- Trans-septal sutures are put to coapt mucoperichondrial flaps.
- Nasal pack is put.
- Thus (coming to question)
- Mucoperichondrial flap (and tunnel) are made on septal cartilage.
- Mucoperiosteal flap (and tunnels) are made on nasal spine.

139. All are major symptoms of sinusitis except ?

a) Nasal bluckage

b) Facial congertion

c) Nasal congestion

d) Halitosis

Correct Answer - D
Ans. is 'd' i.e., Halitosis

- The clinical symptoms of acute sinusitis have been classified into major and minor

Major	Minor
Facial pain or pressure	Headache
Purulent nasal discharge	Cough
Fever	Fatigue
Nasal congestion	Halitosis
Nasal obstruction	Dental pain
Hyposmia or Anosmia	Ear pain or pressure
Facial congestion or fullness	

140. Laryngitis sicca is associated with ?

a) Rhinosporidium

b) M. leprae

c) Klebsiella azaenae

d) Klebsiella rhinoscleromatosis

Correct Answer - C
Ans. is 'c' i.e., Klebsiella azaenae
Laryngitis sicca (Atrophic laryngitis or laryngitis atrophica)

- It is a rare entity characterized by atrophic changes in the respiratory mucosa with loss of the mucus - producing glands.
- It is usually associated with atrophic rhinitis and pharyngitis caused by klebsiella ozaenae.
- The most common sites involved in larynx are the false cords (vestibular folds), the posterior region and the subglottic region.
- More common in women.

Clinical features

- Irritable cough and hoarseness
- Excessive crusts formation which are sometimes bloodstained (hemorrhagic) with foul odour. Crusts are the most important diagnostic feature.

Treatment

- Elimination of causative factors and humidification.
- Laryngeal sprays with glucose in glycerine or oil of pine helps in crust removal. Expectorants containing ammonium chloride or iodides also help to loosen the crust.
- Microlaryngoscopic removal of crust in laryngitis sicca is the new modality of treatment.

141. Ossicles of middle ear are responsible for which of the following ?

a) Amplification of sound intensity

b) Reduction of sound intensity

c) Protecting the inner ear

d) Reduction of impedance to sound transmission

Correct Answer - D
Ans. is 'd' i.e., Reduction of impedance to sound transmission

- The ear canal (auditory canal) acts as a resonator, i.e. it resonates (amplifies frequencies) between 2000 and 5000 (average 3000) cycles per second and therefore most energy will be transmitted to the cochlea in these frequencies.
- However, if this sound energy hits the inner ear fluid directly most of the energy would be reflected, resulting in hearing loss (as all the sound wave is reflected and nothing is a transmitted as electrical impulse).
- Therefore, there is a need for a transformer mechanism, a need that is fullfilled by middle ear → middle ear converts sound of greater amplitude but lesser force to that of lesser amplitude but greater force.
- This function of the middle ear is called impedence matching mechanism or the transformer action.

142. Which structure prevents spread of infection form middle ear to brain ?

a) Tegmen tympani

b) Cribriform plate

c) Fundus tympani

d) Petrous apex

Correct Answer - A
Ans. is 'a' i.e., Tegmen tympani

- Tegmen tympani (forming the roof of middle ear cavity) separates the tympanic cavity from middle cranial fossa.

143. In otosclerosis, which is most affected?

a) Oval window

b) Round window

c) Foot plate of stapes

d) Utricle

Correct Answer - A
Ans. is 'a' i.e., Oval window

- The most common site of disease is promontory in the region of the anterior margin of oval window, and in advanced cases the stapes become ankylosed in position by a mass of new spongy bone.
- Why is it so ?
- This area is involved most commonly because in this area is located the **fissula ante fenestram,** a vestigial structure which frequently contains cartilaginous remnants and which is particularly prone to otosclerotic changes.

Most common type of otosclerosis → Stapedial otosclerosis
Most common site of otosclerosis → Fissula ante fenestram (i.e, just in front of oval window)
Most common site for Stapedial otosclerosis → Fissula ante fenestram (i.e, just in front of oval window)
Most common site for cochlear otosclerosis → Round window

144. True regarding laryngeal TB is?

a) Commonly involves anterior 2/3 rd of vocal cord

b) Mouse-nibbled vocal cord

c) More common in males

d) None of the above

Correct Answer - B
Ans. is 'b' i.e., Mouse-nibbled vocal cord

145. Most common cause of acute tonsilitis ?

a) Streptococcus pneumoniae

b) H. Influenza

c) 13- hemolytic streptococci

d) Staphylococcus aureus

Correct Answer - C
Ans. is 'c' i.e., 13- hemolytic streptococci

- Tonsils frequently serve as the site of acute infection, which causes acute tonsillitis.
- Tonsillitis is particularly common in children, especially in school going age group. However, it can occur in adult also.
- Virus initiates an acute tonsillitis attack and predisposes to bacterial infection.
- 8-hemolytic streptococcus is the most common organism causing acute tonsillitis.
- Other bacteria causing acute tonsillitis are staphylococcus, hemophilus and pneumococcus.

146. Treatment of choice for nasopharyngeal carcinoma is ?

a) Surgery

b) Radiotherapy

c) Surgery & radiotherapy

d) Chemotherapy

Correct Answer - B
Ans. is 'b' i.e., Radiotherapy
Treatment of nasopharyngeal carcinoma

- Irradiation is treatment of choice (external radiotherapy).
- Radical neck dissection is required for persistent nodes when primary has been controlled and in post radiation cervical metastasis.
- Systemic chemotherapy is used as palliation for distant metastases or radiation failure.
- For advanced stages (stage III & IV), the cure rate can be doubled when chemotherapy is combined with radiotherapy.

147. Cone of light focuses on which quadrant of tympanic membrane?

a) Anteroinferior

b) Posteroinferior

c) Anterosuperior

d) Posterosuperior

Correct Answer - A
Ans. is 'a' i.e., Anteroinferior

Cone of light

- Seen in anteroinferior quadrant of the tympanic membrane is actually the reflection of the light projected into the ear canal to examine it.
- This part reflects it because it is the only part of tympanic membrane that is approximately at right angles to the meatus.
- This difference in different part of the tympanic membrane is due to the handle of malleus which pulls the tympanic membrane and causes it to tent inside.
- Thus, the handle of malleus causes tenting and because of tenting the antero-inferior quardrant is at right angles to the meatus and thus reflects the light (leading to cone light).

148. Hearing loss of 65dB, what is the grade of deafness?

a) Mild

b) Moderate

c) Severe

d) Moderately severe

Correct Answer - D
Ans. is 'd' i.e., Moderately severe

149. Vestibular function is assessed by ?

a) Fistula test

b) Hallpike manaeuver

c) Caloric test

d) All of the above

Correct Answer - D
Ans. is 'd' i.e., All of the above

150. Blue ear drum is seen in ?

a) Serous otitis media

b) CSOM

c) Perforation

d) None

Correct Answer - A
Ans. is 'a' i.e., Serous otitis media

- Any accumulation of fluid behind tympanic membrane causes structural changes in tympanic membrane causing it to appear blue, be it pus, blood or serous fluid.
- The most common cause of fluid accumulation in middle ear is **serous otitis media** or glue ear (most common cause) and haemotympanum.
- Other causes of blue tympanic membrane are glomus tumor, hemangioma of middle ear, and cholesterol granuloma.

151. Peritonsillar abscess is caused most commonly by ?

a) Streptococcus pneumoniae

b) Staphylococcus aureus

c) Beta hemolytic streptococcus

d) H. influenzae

Correct Answer - C
Ans. is 'c' i.e., Beta hemolytic streptococcus
Peritonsillar abscess (Quinsy)

- Quinsy consists of suppuration outside the capsule in the area around the capsule. There is collection of pus between the capsule of tonsil and the superior constrictor muscle, i.e. in the peritonsillar area.
- Peritonsillar abscess is a complication of tonsillitis and is most commonly c**aused by group A beta - hemolytic streptococcus**.

Clinical features of Quinsy

- Clinical features are divided into :?
- General : They are due to septicaemia and resemble any acute infection.

1. They include fever (up to 104°F), chills and rigors, general malaise, body aches, headache, nausea and constipation.
2. Local :
3. Severe pain in throat. Usually unilateral.
4. Odynophagia. It is so marked that the patient cannot even swallow his own saliva which dribbles from the angle of his mouth. Patient is usually dehydrated.
5. Muffled and thick speech, often called "Hot potato voice".
6. Foul breath due to sepsis in the oral cavity and poor hygiene.

7. Ipsilateral earache. This is referred pain via CN IX which supplies both the tonsil and the ear.
8. Trismus due to spasm of pterygoid muscles which are in close proximity to the superior constrictor.

Examination findings

1. The tonsil, pillars and soft palate on the involved side are congested and swollen. Tonsil itself may not appear enlarged as it gets buried in the oedematous pillars.
2. Uvula is swollen and oedematous and pushed to the opposite side.
3. Bulging of the soft palate and anterior pillar above the tonsil.
4. Mucopus may be seen covering the tonsillar region.
5. Cervical lymphadenopathy is commonly seen. This involves jugulodigastric lymph nodes.
6. Torticollis : Patient keeps the neck tilted to the side of abscess.

Treatment of peritonsillar abscess

- IV fluids
- Antibiotics : High dose penicllin. (iv benzipenicillin) is the DOC. In patients allergic to penicillin erythromycin is the DOC.
- Incision and drainage per orally, if the abscess does not resolve depite high dose of iv antibiotics
- Tonsillectomy is done 6 weeks following an attack of quinsy (interval tonsillectomy).

152. Strawberry oppearance is seen in ?

a) Lupus vulgarsis

b) Rhinoscleroma

c) Rhinosporidiosis

d) Angiofibroma

Correct Answer - C
Ans. is 'c' i.e., Rhinosporidiosis
Rhinosporidiosis

- Rhinosporidiosis is a chronic granulomatous infection of the mucous membrane that usually manifests as vascular friable polyps that arise from the nasal mucosa. The etiological agent is Rhinosporidium seeberi. Rhinosporidium seeberi is an aquatic bacterum (not a fungus). Infection usually results from a local traumatic inoculation with the organism. It is seen in India, Pakistan and Sri Lanka. In India, most of the cases are seen in Southern states. Infection of the nose and nasopharynx is observed in 70% of persons with rhinosporidiosis; infection of palpebral conjunctiva or associated structures (including lacrimal apparatus) is observed in 15% of cases. Other structures of the mouth and upper airway may be sites of disease. Disease of the skin, ear, genitals and rectum has also been described. Rhinosporidiosis is an infection that typically limited to the mucosal epithelium. The disease progress with local replication of R seeberi and associated hyperplastic growth of host tissue and a localized immune response.
- Clinical features of Rhinosporidiosis
- Rhinosporidiosis presents as soft leafy polypoidal mass (soft polyp), which is pink to purple in colour studded with white dots, i.e. **strawberry appearance**. This appearance results from sporangia,

which is visible as grey or yellow spots in the vascular polypoid masses. Because the polyps are vascular and friable, they bleed easily upon manipulation.

Treatment

- The treatment of choice is surgical excision. Complete excision of mass is done with diathermy knife and cauterization of base. Dapsone is being tried for treating rhinosporidiosis but with limited success.

153. True about central nystagmus ?

a) Changing direction

b) Not suppressed by optic fixation

c) Horizontal or vertical

d) All of the above

Correct Answer - D
Ans. is 'd' i.e., All of the above
Nystagmus
- Nystagmus is *rhythmic oscillatory movement* of eye.
- Nystagmus has following characteristics :?
1. Rapid,
2. Involuntary,
3. Repetitive
- Nystagmus may be *:?*
1. Side to side **(horizontal nystagmus)**
2. Up and down **(verticle nystagmus)**
3. Rotary
- Vestibular nystagmus has two components, i.e. a slow and a fast.
- The direction of nystagmus is indicated by the direction of fast component.
- Vestibular nystagmus may be :?
1. Peripheral :- due to lesion of labyrinth or VIII nerve.
2. Central :- due to lesion of vestibular nuclei, brainstem or cerebellum.

i. Peripheral nystagmus
- Diminshes or suppresses with gaze fixation (optic fixation)
- Enhances in darkness or by use of Frenzel glasses
- Unidirectional fast component
- Direction is typically horzonto - rotary, not purely horizontal or rotary

and not vertical

- Direction is fixed towards undermost ear
- Present in one head position

ii. Central nystagmus

- **Not suppressed by optic fixation**
- Fast component can be unidirectional or bidirectional
- Can be horizontal, vertical or rotary
- **Direction is changing**
- Present in multiple head positions

154. Potato tumor is

a) Rhinosporidiosis

b) Hypertrophied sebaceous gland

c) Nosopharyngeal angiofibroma

d) Tubercular infection

Correct Answer - B
Ans. is 'b' i.e., Hypertrophied sebaceous gland
Rhinophyma (Potato tumor)

- Rhinophyma is a benign tumor of tip of nose due to **hypertrophy of sebaceous gland.**
- It is caused by granulomatous infiltration and occurs as a complication of long standing acne rosacea.
- Alcoholism is mistakenly attributed as a cause of this disease, but heavy alcohol consumption does aggravate the condition.
- The usual presentation is due to cosmetic appearance or obstruction.
- Treatment of choice is debulking of tumor by carban dioxide laser.

155. Early tonsillectomy is not done in?

a) Thyroid storm

b) Suspected malignancy

c) Peritonsillar abscess

d) Rheumatic fever

Correct Answer - A

Ans. is 'a' i.e., Thyroid storm

- Uncotrolled systemic hypertension is a contraindication for tonsillectomy.
- In thyroid storm there is dangerously high BP.

Contraindications of tonsillectomy

1. Haemoglobin level less than 10 g%.
2. Presence of acute infection in upper respiratory tract, even acute tonsillitis. Bleeding is more in the presence of acute infection.
3. Children under 3 years of age. They are poor surgical risks.
4. Overt or submucous cleft palate.
5. Bleeding disorders, e.g. leukaemia, purpura, aplastic anaemia, haemophilia.
6. At the time of epidemic of polio.
7. Uncontrolled systemic disease, e.g. diabetes, cardiac disease, hypertension or asthma.
8. Tonsillectomy is avoided during the period of menses.

156. Most common cause of retropharyngeal abscess in adults?

a) TB

b) Tooth extraction

c) Tonsillitis

d) Lymphadenitis

Correct Answer - A
Ans. is 'a' i.e., TB

- Abscess in infants (acute retropharyngeal abscess)
- Most commonly it results from retropharyngeal lymphadenitis due to an upper respiratory tract infection.
- Treatment is incision and drainage.
- Abscess in adults (chronic retropharyngeal abscess)
- If an adult or an older child has a retropharyngeal infection it is likely to be due to a **tuberculous infection** of the cervical spine (caries of cervical spine). Sometime it may be secondary to tuberculous infection of retropharyngeal lymph nodes.
- Treatment includes incision and drainage of abscess along with full course of antitubercular treatment.

157. Otosclerosis affects which bone?

a) Stapes

b) Incus

c) Malleus

d) None

Correct Answer - A
Ans. is 'a' i.e., Stapes
Types of otosclerosis

- Following types of otosclerosis have been described :-
1. Fenesteral or stapedial otosclerosis
- It is the most common type (80-90%) The lesion starts just in front of the oval window in an area called fissula ante fenestram" and causes stapes footplate fixation and conductive hearing loss. Hearing loss is purely mechanical.
2. Cochlear otosclerosis (Retrofenestral otosclerosis)
- When present, it is almost always associated with stapedial (fenestral) otosclerosis. It involves region of round window or other areas in the otic capsule. It causes mixed or sensorineural hearing loss which is believed to be toxic due to diffusion of cytotoxic enzymes into the fluid of the membranous labyrinth (In contrast to stapedial otosclerosis, where the deafness is purely mechanical and is conductive). Tinnitus is more common in cochlear otosclerosis.
3. Histologic otosclerosis
- This type of otosclerosis remains asymptomatic and causes neither conductive nor sensorineural hearing loss.

158. Endolymphatic sac decompression is done in?

a) Menieres disease

b) Otosclerosis

c) Otitis media

d) Vestibular schwannoma

Correct Answer - A
Ans. is 'a' i.e., Menieres disease
Treatment of Meniere's disease

- Most treatments are for symptoms believed to be caused by excess endolymphatic fluid. Treatment of Meniere's disease is of two types :?

A) Medical management
B) Surgical management
Medical management:

- Treatment of Meniere's disease begins first with medical management.
- Medical treatment controls the condition in over two third of patients.
- Medical management includes :?

1. Antihistamine labyrinthine sedatives (vestibular sedatives)

- Many cases can be controlled by vestibular sedatives like prochlorperazine, promethazine, dimenhydramine, and cinnarzine.

2. Anxiolytic and tranquillizers

- Many patients are anxious, therefore they may be helped by anxiolytic and tranquillizers like diazepam.

3. Vasodilators

- Betahistine hydrochloride appears to be the most useful recent addition to the medical armamentarium and is routinely prescribed

for most patients. It increases labyrinthine blood flow by releasing histamine.

- Other vasodilators employed include nicotinic acid, thymoxamine, inhaled carbogen (5% CO2 with 95% 0_2), and histamine drip.
- Vasodilators increase vascularity of endolymphatic sac and its duct **and** thereby increases reabsorption of endolymphatic fluid.

4. Diuretics (furosemide)

- Diuretics with fluid and salt restriction can help to control recurrent attacks if not controlled by vestibular sedatives or vasodilators.

5. Other drugs

- Propantheline bromide, phenobarbitone and hyoscine are effective alternatives.
- Surgical management
- Surgical therapy for meneire's disease is reserved for medical treatment failures and is otherwise controversial. Surgical procedures can be divided into two main categories
- Destructive surgical procedures
- Nondestructive surgical procedures
- Destructive surgical procedures : rationale is to control vertigo. Endolymphatic hydrops causes fluid pressure accumulation within the inner ear, which causes temporary malfunction and misfiring of the vestibular nerve. These abnormal signals cause vertigo. Destruction of the inner ear and / or the vestibular nerve prevents these abnormal signals. The procedures performed are :
- Labyrinthectomy
- Intermittent low pressure pulse therapy (Meniett device therapy)
- Conservative surgical procedures : are used in cases where vertigo is disabling but hearing is still useful & needs to be preserved. They are :
- **Decompression of endolymphatic sac**
- Endolymphatic shunt operation
- Sacculotomy (Fick's operation & Cody's tack procedure)
- Vestibular neuronectomy
- Ultrasonic destruction of vestibular labyrinth to preserve cochlear function.
- Stellate ganglion block or cervical sympathectomy
- I ntratympanic gentamycin

- Vestibular nerve section

159. In type-4 thyroplasty, vocal cord is ?

a) Medially displaced

b) Laterally displaced

c) Lengthened

d) Shortened

Correct Answer - C
Ans. is 'c' i.e., Lengthened

Thyroplasty

- Isshiki divided thyroplasty procedures into 4 categories to produce functional alteration of vocal cords : -

1. Type I : Medial displacement of vocal cord (done by injection of gel foam/Teflon paste)
2. Type 2 : Lateral displacement of cord (done to improve the airway).
3. Type 3 : Shortening (relax) the cord, to lower the pitch (gender transformation from female to male).
4. Type 4 : Lengthening (tightening) the cord, to elevate the pitch (gender transformation from male to female), for example as a treatment of androphonia.

160. Fenestration operation is which type of tympanoplasty?

a) Type-2

b) Type-3

c) Type-4

d) Type-5

Correct Answer - D
Ans. is 'd' i.e., Type-5
Types of tympanoplasty

- *Wullstein* classified tympanoplasty into five types :?

Type I: → Defect is perforation of tympanic membrane which is repaired with a graft. It is also called myringoplasty.
Type II: → Defect is perforation of tympanic membrane with erosion of malleus. Graft is placed on the incus or remnant of malleus.
Type III: → Malleus and incus are absent. Graft is placed directly on the stapes head. It is also called *myringostapediopexy or columella tympanoplasty.*
Type IV: → Only the footplate of stapes is present. It is exposed to the external ear, and graft is placed between the oval and round windows. A narrow middle ear (cavum minor) is thus created, to have an air pocket around the round window. A mucosa-lined space extends from the eustachian tube to the round window. Sound waves in this case act directly on the footplate while the round window has been shielded.
Type V: → Stapes footplate is fixed but round window is functioning. In such cases, another window is created on horizontal semicircular canal and covered with a graft. Also called **fenestration**

operation.

161. Bullous myringitis is caused by?

a) Pseudomonas

b) Mycoplasma

c) Pneumococcus

d) Candida

Correct Answer - B
Ans. is 'b' i.e., Mycoplasma
Otitis externa haemorrhagica

- This condition is also known as Bullous myringitis or myringitis bullosa.
- This condition is extremely painful and has sudden onset.
- It is thought to be due to **mycoplasma pneumoniae** or viral infection, usually influenza
- There may be a mild conductive deafness and a mildly discharging ear.
- The appearance of haemorrhagic bullae on the tympanic membrane and in the deep meatus is characteristic.
- The bullae are filled with serosanguinous fluid and blood.
- On healing, bullae look like Sago-grain.
- Therefore "Sago-grain" appearance of tympanic membrane is seen in healed myringitis bullosa.

162. All are absolute indications of tonsillectomy except

a) Suspicious malignancy

b) Peritonsillar abscess

c) Chronic tonsillits

d) Tonsils causing obstructive sleep apnea

Correct Answer - C
Ans. is 'c' i.e., Chronic tonsillits

Tonsillectomy

- Tonsillectomy, as the name suggests, is the surgical procedure to remove the tonsils.
- Often, tonsillectomy is done at the same time as adenoidectomy.
- Indications
- Indications are divided into :?

A. Absolute

1. Recurrent infections of throat. This is the most common indication.Recurrent infections are further defined as :

- Seven or more episodes in one year, or
- Five episodes per year for 2 years, or
- Three episodes per year for 3 years, or
- Two weeks or more of lost school or work in one year.

2. Peritonsillar abscess.

- In children. tonsillectomy is done 4-6 weeks after abscess has been treated. In adults, second attack of peritonsillar abscess forms the absolute indication.

3. Tonsillitis causing febrile seizures.
4. Hypertrophy of tonsils causing

- Airway obstruction (sleep apnoea)

- Difficulty in deglutition
- Interference with speech.

5. Suspicion of malignancy.

- A unilaterally enlarged tonsil may be a lymphoma in children and an epidermoid carcinoma in adults. An excisional biopsy is done.

B. Relative

1. Diphtheria carriers, who do not respond to antibiotics
2. Streptococcal carriers, who may be the source of infection to others.
3. Chronic tonsillitis with bad taste or halitosis which is unresponsive to medical treatment.
4. Recurrent streptococcal tonsillitis in a patient with valvular heart disease.

C. As a part of Another Operation

1. Palatopharyngoplaty which is done for sleep apnoea syndrome.
2. Glossopharyngeal neurectomy. Tonsil is removed first and then IX nerve is severed in the bed of tonsil.
3. Removal of styloid process.

163. Retraction of tympanic membrane touching promontory. What is sade's grade?

a) 1

b) 2

c) 3

d) 4

Correct Answer - C
Ans. is 'c' i.e., 3
Atelectic grades of pars tensa
Sade classification::
Grade 1 = slight retraction of TM over the annulus
Grade 2 = the TM touches the long process of the incus
Grade 3 = the TM touches the promontory
Grade 4 = the TM is adherent to the promontory

164. Posterosuperior retraction pocket if allowed to progress will lead to?

a) SNHL

b) Secondary cholesteatoma

c) Tympanosclerosi

d) Primary cholesteatoma

Correct Answer - D

Ans. is'd' i.e., Primary cholesteatoma

- Retraction pockets are more common in the postero-superior portion of pars-tensa of ear-drum (tympanic membrane).
- Two reasons have been attributed to this features :-

1. This area is more vascular, hence could be subjected to intense inflammatory reaction.
2. Middle fibrous layer in this area is incomplete, lackin circular fibers.

- Long term effects ofprogressive retraction may be :-

1. Fixation of atrophic sigment to bony wall of middle ear cavity.
2. Erosion of ossicles, most commonly long process of incus.
3. Formation of cholesteatoma (primary acquired cholesteatoma).
4. "A posterior superior retraction pocket, if allowed to progress, leads to primary acquired choleastoma".

<u>Acquired cholesteatoma</u>

In majority of cases cholesteatoma is acquired. Acquired cholesteatoma may be either primary acquired or secondary acquired :?

A. Primary acquired cholesteatoma

- There is no history of previous otitis media or a pre-existing perforation.
- Theories for its genesis are : -

1. Retraction pocket (wittmaack's theory) : - It is the most accepted theory. There is invagination of pars flaccida in the form of retraction pocket due to negative pressure in middle ear as a result of Eustachian tube dysfunction. There is in growth (migration) of squamous epithelium from the outer layer of tympanic membrane (outer layer of TM is lined by squamous epithelium) through this retraction pocket. Infection supervenes on the impacted squamous epithelium/keratin.
2. Basal cell hyperplasia (Ruedi's theory) : - There is proliferation of the basal layer of pars flaccida induced by subclinical childhood infections. These proliferating basal cells lay down keratinizing squamous epithelium.
3. Squamous metaplasia (Sade's theory) : - Pavement epithelium of attic undergoes metaplasia and transforms into squamous epithelium due to subclinical infections.

B. Secondary acquired cholesteatoma

- There is pre-existing perforation in pars tensa.
- Theories on its genesis include : -

1. Epithelial invasion (Habermann's theory) : - The epithelium from the meatus or outer drum surface grows into the middle ear through a pre-existing perforation especially of the marginal type where part of annulus tympanicus has already been destroyed.
2. Metaplasia : - Middle ear mucosa undergoes metaplasia due to repeated infections of middle ear through the pre-existing perforation.

165. Treatment of choice for atticoantral type of CSOM?

a) Antiboiotics

b) Tympanoplasty

c) Modified radical mastoidectomy

d) None

Correct Answer - C
Ans. is'c' i.e., Modified radical mastoidectomy

Treatment of atticoantral disease

- Since cholesteatoma is going to expand and destroy bone and mucous membrane, it has to be removed.
- Therefore, surgery is the mainstay of treatment.
- Primary aim is removal of disease by mastoidectomy to make ear safe followed by reconstruction of hearing at a later stage.
- **Modified radical mastoidectomy is the surgery of choice.**
- Two types of surgical procedures (mastoidectomy) are done to deal with cholesteatoma:-

1. Canal wall down procedures

- These leave the mastoid cavity open into the external auditory canal so that the diseased area is fully exteriorized.
- The commonly used procedures for atticoantral disease are atticotomy, modified radical mastoidectomy and rarely radical mastoidectomy.
- Modified radical mastoidectomy is the procedure of choice.

2. Canal wall up procedures (cortical mastoidectomy)

- Here disease is removed by combined approach through the meatus and mastoid but retaining the posterior bony meatus wall, thereby avoiding an open mastoid cavity.

- For reconstruction of hearing mechanism myringoplasty or tympanoplasty can be done at the time of primary surgery or as a second stage procedure.

166. Retraction of tympanic membrane touching the promontory. It is called ?

a) Mild retraction

b) Severe retraction

c) Atelectasis

d) Adhesive otitis

Correct Answer - C
Ans. is 'c' i.e., Atelectasis
Tympanic membrane retraction

- The retracted segment of eardrum is often known as a retraction pocket.
- The terms **"atelectasis"** or sometimes "adhesive otitis media" can be used to describe retraction of a large area of the pars tensa.

167. All are true about Rinne's test except ?

a) Positive in normal ear

b) Positive in sensorineural hearing loss

c) Minimum 15-20 dB air bone gap is required in conductive deafness

d) **Bone** conduction is better in sensorineural hearing loss

Correct Answer - D
Ans. is'd' i.e., Bone conduction is better in sensorineural hearing loss
Rinne's Test

- The Rinne test is a tuning fork test that compares hearing by air conduction and bone conduction. The Rinne test is based on the idea that hearing mechanism is normally more efficient by air conduction (AC) than it is by bone conduction (BC), i.e., AC > BC in normal persons. For this reason, a tuning fork will sound louder and longer by air conduction than by bone conduction. However, this air conduction advantage is lost when there is a conductive hearing loss in which case the tuning fork sounds louder by bone conduction than by air-conduction.

Method

- Administering the Rinne test involves asking the patient to indicate whether a vibrating tuning fork sounds louder when its base is held against mastoid process (bone conduction) or when its prongs are held near the pinna, facing the opening of ear canal (air conduction). After striking the fork, the clinician alternates it between these two positions so that the patient can make a judgement about which one is louder.
- Interpretation of Rinne's test
- The outcome of the Rinne test is traditionally called "positive" if the

fork is louder by air conduction and this finding implies that the ear is normal or has sensorineural hearing loss. The results are called "negative" if the bone-conduction is louder than air-conduction, which is interpreted as revealing the presence of conductive deafness i.e., lesions of either external ear, tympanic membrane, middle ear or ear ossicles..

- In conductive deafness Rinne's test will be negative if the conductive hearing loss is greater than 15-20 dB **(minimum air bone gap 15-20 dB)**. That means, at least 15-20 dB of conductive hear loss is required to show bone conduction better than air conduction, i.e., Negative Rinne's test. A negative Rinne test for 256, 512 and 1024 Hz indicates a minimum air-bone gap (ABG) of 15, 30, 45 dB respectively. Therefore, AB gap can be made if tuning forks of 256, 512 and 1024 Hz are used : -

1. A Rinne test equal or negative for 256 Hz but positive for 512 Hz indicates air-bone gap of 20-30 dB.
2. A Rinne test negative for 256 and 512 Hz but positive for 1024 Hz indicates air-bone gap of 30-45 dB.
3. A Rinne negative for all the three tuning forks of 256, 512, and 1024 Hz, indicates air-bone gap of 4560 dB.

Rationale of positive test

- Positive test (AC > BC) is seen in *:?*

1. **Normal person**

- It has already been explained that air conduction is better than bone conduction, thus Rinne test is positive in normal person.

2. **Sensori-neural hearing**

- In sensorineural hearing loss, the defect is in cochlea or VIII nerve or its central connection. There is no defect in conductive apparatus of ear (air conduction) or in mastoid bone (bone conduction). As **air conduction is better than bone conduction,** Rinne test will be positive (because both air conductive apparatus and bone conductive apparatus are normal and the pathology is distal to them).
- Negative test (BC >AC) is seen in : *?*

1. Conductive deafness

- As the conductive apparatus is defective, bone conduction becomes better than air conduction (BC > AC).

2. *Severe unilateral sensorineural hearing loss*

- Here the Rinne test is false negative (not true negative) as it is interpreted by the patient that BC > AC, but actually it is not. In reality this response is from the opposite ear because of transcranial transmission of sound during bone conduction testing. This can be prevented by masking the non-test ear with Barany's box while testing the bone conduction. Weber test will help for such situation.

168. Stimulation of horizontal semicircular canal causes nystagmus in which directions ?

a) Vertical

b) Horizontal

c) Rotary

d) Any of the three

Correct Answer - B
Ans. is **'b' i.e.,** Horizontal

- The cupulae of the semicircular canals are stimulated by movement of endolymphatic fluid and each canal causes the nystagmus in its own plane :-

1. Stimulation of horizontal SCC → 4 Horizontal nystagmus.
2. Stimulation of superior SCC → 4 Rotary nystagmus.
3. Stimulation of vertical SCC → Vertical nystagmus

169. Bilateral past-pointing is due to defect in ?

a) Brainstem

b) Cerebellum

c) Vestibular system

d) Basal ganglia

Correct Answer - C
Ans. is 'c' i.e., Vestibular system

- Past-pointing is the deviation of the extremities caused by either *cerebellar hemisphere or vestibular disease.*
- Testing is usually done with arms. The traditional method is to have the patient extend the arm and place his extended finger on the examiner's index finger; then with the eye closed raise the arm directly overhead; than bring it back down precisely onto the examiner's finger.
- If vestibular or cerebellar lesion is there, past pointing (deviation of limb) will be present.
- The two types (cerebellar and vestibular) past pointing have different patterns :-

1. With vestibular in:balance, the normal labyrinth will push the limb toward the abnormal side and the patient will miss the target. The past pointing will always be to the same side of target and will occur with either limb.
2. With a cerebellar hemispheric lesion, the ipsilateral limbs will have ataxia and incoordination; past pointing occurs only with the involved arm and may be to the side of lesion or erratically to either side of the target.

So,

- Bilateral past-pointing → Vestibular system defect.
- *Unilateral past-pointing → Cerebellar hemisphere defect.*

170. Major contribution in the formation of nasal septum is by all except ?

a) Septal cartilage

b) Vomer

c) Ethmoid

d) Nasal bone

Correct Answer - D
Ans. is **'d' i.e.,** Nasal bone

- The medial wall, or **nasal septum**, is **formed** (from anteiror to posterior) by :
(1) the **septal** cartilage (destroyed in a dried skull)
(2) the perpendicular plate of the **ethmoid bone**, and
(3) the **vomer** . It is usually deviated to one side.
- The vomer contributes to the inferior portion of the **nasal septum**; the perpendicular plate of the ethmoid bone contributes to the superior portion.

171. All are true about conductive deafness except ?

a) Rinne's test is negative

b) Absolute bone conduction is normal

c) Weber is lateralized to poorer ear

d) There is decay in threshold tone

Correct Answer - D
Ans. is 'd' i.e., There is decay in threshold tone

172. Ethmoidal polyp is ?

a) Due to infection

b) Single

c) Recurrent

d) Occurs in children

Correct Answer - C
Ans. is 'c' i.e., Recurrent

173. Most common cause of oroantral fistula ?

a) TB

b) Penetrating injury

c) Tooth extraction

d) Iatrogenic

Correct Answer - C
Ans. is 'c' i.e., Tooth extraction

Oroantral fistula

- It is communication between the antrum and oral cavity.

Etiology

- Dental extraction :- Most important cause and maxillary first molar accounts for 50% of oral-antral fistulas caused by extractions. Maxillary second and third molar extractions account for other 50%.
- Infection :- TB, syphilis, leprosy of maxillary bone.
- Malignant neoplasm :- Causes erosion of antrum.
- Fracture or penetrating injuries of maxilla.
- Midline granuloma (a form of lymphoma)
- Failure of sublabial incision to heal after Caldwell - Luc operation.
- Clinical features
- Regurgitation of food
- Discharge (often foul smelling)
- Inability to built positive or negative pressure in mouth.

174. Killian dehiscence is in ?

a) Superior constrictor

b) Inferior constrictor

c) Middle constrictor

d) None

Correct Answer - B
Ans. is 'b' i.e., Inferior constrictor
Inferior constrictor muscle has two parts :- (i) Thyropharyngeous with oblique fibres, and (ii) Cricopharyngeous with transverse fibres. Between these two parts of inferior constrictor exists a potential gap called Killan's dehiscence. It is also called the gateway to tear as perforation can occur at this site during esophagoscopy. It is also the site for herniation of pharyngeal mucosa in case of pharyngeal pouch.

175. Saddle nose is ?

a) Depressed nose

b) Crooked nose

c) Deviated nose

d) C-shaped

Correct Answer - A
Ans. is 'a' i.e., Depressed nose

Saddle nose (Depressed nose)

- Nasal dorsum is depressed (sagging of the bridge of nose).
- Depressed nasal dorsum may involve either bony, cartilaginous or both bony and cartilaginous components. Most common etiology : Nasal trauma
- Causes are *hematoma,* excessive surgical removal, trauma, *syphilis,* abscess, *Leprosy,* and tuberculosis.

Crooked or deviated nose

- *Crooked nose* is the external deviation of nose due to deviation of the dorsal border of septal cartilage, forming a `C' or 'S' shaped curve.
- In *crooked nose,* the midline dorsum is curved in 'C' or 'S' shaped manner from the frontonasal angle to the tip of nose.
- In a deviated nose, the midline is straight but deviated to one side, midline is not curved as in crooked nose.

176. Tonsillar fossa is bounded anteriorly by ?

a) Pharyngobasilar fascia

b) Palatopharyngeal fold

c) Buccopharyngeal fascia

d) Palatoglossal fold

Correct Answer - D
Ans. is 'd' i.e., Palatoglossal fold

- Palatine tonsils are masses of lymphoid tissue that can be seen on the left and right sides at the back of the throat.
- There are two palatine tonsils, and each palatine tonsil (right or left) lies in the tonsilar sinus (tonsilar fossa) on the lateral wall of oropharynx.
- Tonsillar fossa bounded by the **palatoglossal fold in front** and the palatopharyngeal fold behind.
- Tonsils are lined by non - keratinized stratified squamous epithelium.
- Medial surface of each tonsil has 15-20 crypts, the largest of which is called Intratonsillar cleft or crypta magna (which represents persistence of the ventral portion of the second pharyngeal pouch).
- Tonsillar bed is formed from within - outwards by :-
- Li Pharyngobasilar fascia
- Superior constrictor (above) and palatopharyngeus muscle
- Styloglossus (below)
- Buccopharyngeal fascia

177. Passavants ridge is formed by ?

a) Palatoglossus

b) Superior constrictor

c) Salpingopharyngeus

d) Palatopharyngeus

Correct Answer - D
Ans. is 'd' i.e., Palatopharyngeus
Pharynx has two group of muscles *:?*
* Intrinsic muscles :- Stylopharyngeous, salpingopharyngeous, palatopharyngeous.
* Extrinsic muscles :- Superior constrictor, middle constrictor, inferior constrictor.
- All muscles of pharynx are supplied by cranial accessory through branches of vagus via pharyngeal plexus except stylopharyngeus which is supplied by glossopharyngeal.
- Inferior constrictor muscle has two parts :- (i) Thyropharyngeous with oblique fibres, and (ii) Cricophatyngeous with transverse fibres.
- Between these two parts of inferior constrictor exists a potential gap called Killan's dehiscence. It is also called the gateway to tear as perforation can occur at this site during esophagoscopy. It is also the site for herniation of pharyngeal mucosa in case of pharyngeal pouch.
- Upper fibers of palatopharyngeus constitute the Passavant's muscle which on contraction raises a ridge called Passavant's ridge on posterior wall of nasopharynx.

178. Hot potato voice is characteristic of ?

a) Nasopharyngeal carcinoma

b) Glottic carcinoma

c) Subglottic carcinoma

d) Supraglottic carcinoma

Correct Answer - D
Ans. is 'd' i.e., Supraglottic carcinoma
Clinical features of supraglottic carcinoma

- Pain on swallowing is the most frequent initial symptom -- Devita 7th/e p. 698
- Mass in neck may be the first sign.
- Hoarsness is a late symptom.
- Pain may be referred to ear by vagus nerve and auricular nerve of arnold.
- Late symptoms include foul breath, dysphagia and aspiration.
- **Large tumors can cause "hot potato voice/muffled voice".**
- Hemoptysis, sore throat, shorteness of breath, stridor, otalgia and aspiration pneumonia may also occur.

179. All are early complications of tracheostomy except?

a) Hemorrhage

b) Pneumothorax

c) Injury to esophagus

d) Tracheal stenosis

Correct Answer - D
Ans. is 'd' i.e., Tracheal stenosis

Complications of tracheostomy

Immediate (at the time of operation)

- Hemorrhage
- Apnea
- Pneumothorax
- Injury to RLN
- Aspiration of blood
- Injury to esophagus

- Intermediate (first few hours or days)
- Bleeding (reactionary or secondary)
- Displacement of tube
- Blocking of tube
- Subcutaneous emphysema
- Tracheitis and tracheobronchitis
- Atelectasis and lung abscess
- Local wound infection and granulations

Late (with prolonged use of tube for weeks or months)

- Hemorrhage, due to erosion of major vessel
- Laryngeal stenosis
- Tracheal stenosis
- Tracheo-esophageal fistula
- Problem of decannulation
- Persistent tracheocutaneous fistula
- Problem of tracheostomy scar

180. Nasopharynx is lined by which epithelium ?

a) Stratified squamous nonkerationized

b) Stratified squamous keratinized

c) Ciliated columnar

d) Cuboidal

Correct Answer - C
Ans. is 'c' i.e., Ciliated columnar
The two main types of epithelia lining the nasopharynx are stratified squamous (comprising approximately 60% of **nasopharyngeal** epithelium) and pseudostratified columnar respiratory epithelium containing **ciliated** cells, goblet cells and basal cells.

181. Vidian neurectomy is done for ?

a) Allergic rhinitis

b) Atrophic rhinitis

c) Vasomotor rhinitis

d) Chronic hypertrophic rhinitis

Correct Answer - C
Ans. is 'c' i.e., Vasomotor rhinitis

Vasomotor rhinitis

- Vasomotor is a nonallergic condition that involves a constant runny nose, sneezing and nasal congestion, i.e., the nose is stuffy or runny for reasons other than allergies and infections. The exact etiology is unknown, but triggers include emotions, odors, poor air quality, spicy foods, and medication side effects. Pathogenesis include:-
- Parasympathetic overactivity
- Hyperactive nasal mucosa to several non-specific stimuli especially in women of 20-40 years.
- Symptoms of vasomotor rhinitis include excessive clear rhinorrhoea, nasal obstruction/congestion, irritation, paroxysmal sneezing and post-nasal drip. Nasal mucosa is hypertrophied & congested; and mucosa of turbinates may give mulberry like appearance and is pale to dusky red in colour.
- Complications of vasomotor rhinitis include hypertrophic rhinitis & sinusitis, and nasal polyp.

Treatment

- Treatment of vasomotor rhinitis includes : -
  1. Conservative treatment
- Avoidance of physical factors which provoke symptoms.
- Antihistaminics and oral or nasal decongestants.

- Topical or systemic steroids
  2. Surgical treatment
- Nasal obstruction can be relieved by measures which reduce the size of hypertrophied nasal turbinate : -Cryosurgery, submucosal diathermy, Linear cauterization, partial or total turbinectomy, submucosal
- resection of turbinate.
- Excessive rhinorrhoea in vasomotor Rhinitis not corrected by medical therapy and bothersome to the patient, is relieved by sectioning the parasympathetic secretomotor fibres to nose i.e., **vidian neurectomy.**

182. Lymphatic drainage of orpharynx is mainly through?

a) Superficial cervical lymph nodes

b) Submandibular nodes

c) Jugulodigastric node

d) Jugulo-omohyoid nodes

Correct Answer - C
Ans. is 'c' i.e., Jugulodigastric nodes

- Deep cervical lymph nodes are divided into two groups :- (i) jugulodigastric, and (ii) jugulo-omohyoid.
- Lymphatics from oropharynx drain into jugulodigastric nodes.

Lymphatic drainage of pharynx

- Lymphatic drainage of pharynx may be :?

1. Nasopharynx

- Nasopharynx drains into upper deep cervical nodes either directly or indirectly through retropharyngeal or parapharyngeal nodes.
- Nasopharynx also drains into spinal accessory chain of nodes in the posterior triangle of the neck.

2. Oropharynx

- Lymphatics from the oropharynx drain into upper jugular particularly the jugulodigastric (tonsillar) nodes.
- The soft palate, lateral and posterior pharyngeal walls and the base of tongue also drain into retropharyngeal and parapharyngeal nodes and from there to the jugulodigastric and posterior cervical group.

3. Hyphopharynx

- Pyriform sinus drains into upper jugular chain & then to deep cervical group of lymph nodes.
- Postcricoid region drains into parapharyngeal and paratracheal

group of lymph nodes.

- Posterior pharyngeal wall drains into parapharyngeal lymph nodes and finally to deep cervical lymph nodes.

183. All are true about otitic barotrauma except ?

a) Conductive deafness

b) Retracted tympanic membrane

c) Catheterization can be used

d) Occurs during sudden ascent in aircraft

Correct Answer - D
Ans. is 'd' i.e., Occurs during sudden ascent in aircraft
Otitic Barotrauma

- This condition is seen when the ambient pressure is rising, e.g. in scuba diving (underwater diving), **descending in an aircraft**, or compression in pressure chamber.
- It occurs due to pressure differences between the inside and outside of the eardrum.
- Clinical features
- Ear discomfort or pain, **hearing loss,** and tinnitus are common
- Vertigo is uncommon
- Otoscopy findings are :-
- **Congested and retracted tympanic membrane**
- Blood may extravasate into middle ear producing haemotympanum
- On examination there is conductive deafness.
- Pathogenesis of otitic barotrauma
- The middle ear pressure is normally maintained at a level similar to that of the atmosphere by the function of Eustachian tube which allows passage of air from middle ear to pharynx. Sudden or dramatic changes of external pressure may defeat this mechanism and cause injury to middle ear. When atmospheric pressure is higher than that of middle ear by critical level of 90 mm Hg,

eustachian tube gets locked as the soft tissues of pharyngeal end of the tube are forced into the lumen by high atmospheric pressure. This results in sudden negative pressure in the middle ear which causes retraction of tympanic membrane, hyperemia, transudation with hemorrhage and development of

- Aero-otitis media (barotrauma)
- At pressure difference >100 to 500 mm Hg, tympanic membrane can rupture → when the pressure difference is more than 100 mg Hg, tympanic membrane can rupture.

Treatment of otitic Barotrauma

- Routine self treatment of pain associated with changing pressure in air craft includes chewing gum, attempting to yawn & swallow, blowing against closed nostrils, and using decongestant nasal sprays. The aim is to restore middle ear areation.
- **Catheterization** or politzerization can also be used. If the eustachian tube will not open with other treatments, surgery may be necessory. Myringotomy and aspiration of fluid is the surgical procedure used.

184. Tear drop sign is seen in ?

a) Fracture zygomatic arch

b) Fracture maxilla

c) Fracture mandible

d) Blow out fracture

Correct Answer - D
Ans. is 'd' i.e., Blow out fracture
Fractures of the floor of the orbit

- Zygomatic fracture and Le fort II maxillary fractures are always accompanied by fractures of orbital floor.
- Isolated fractures of orbital floor, when a large blunt object strikes the globe, are called "blow out fractures".

Clinical features

- Ecchymosis of lid, conjunctiva and sclera.
- Endophthalmos with inferior displacement of the eye-ball. This becomes apparent when oedema subsides.
- Diplopia, which may be due to displacement of the eyeball or entrapment of inferior rectus and inferior oblique muscles.
- Hypoaesthesi a or anaesthesia of cheek and upper lip, if infraorbital nerve is involved.

Diagnosis

- J Water's view show a convex opacity bulging into the antrum from above, i.e., **Tear drop opacity**.
- CT scan is diagnostic.

185.

Inverted papilloma of nose arise from ?

a) Nasal septum

b) Roof of the nose

c) Tip of the nose

d) Lateral wall of the nose

Correct Answer - D
Ans. is 'd' i.e., Lateral wall of the nose
Inverted Papilloma (Transitional cell papilloma/Schneiderion papilloma)

- Inverted papilloma is a benign neoplasm occurs mostly between 40-70 years with male preponderance (5 : 1).
- It arises from the **lateral wall of nose** and is always unilateral. Rarely, it may arise from nasal septum.
- Features of inverted papilloma are : -
- It shows finger like epithelial invasions into the underlying stroma of the epithelium rather than on surface so called inverted papilloma.
- It is usually unilateral and is a locally aggressive tumour.
- Patients complain of nasal obstruction, rhinorrhea & unilateral epistaxis.
- In 10-15% cases there may be associated squamous cell carcinoma.
- Treatment is adequate local excision. If it arises in maxillary sinus, then a radical antrostomy is carried out. If it arises in the ethmoidal sinus, an external ethmoidectomy is done. If it arises from nose,

treatment is wide surgical excision by lateral rhinotomy.

- Has a tendency to recur even after removal.

186. True about external nose ?

a) Upper 2/3 is bony

b) Lower 1/3 is cartilaginous

c) Single lateral cartilage

d) Two nasal bones

Correct Answer - D
Ans. is'd' i.e., Two nasal bones

- External nose has an osteocartilaginous framework of which **upper one - third is bony** and **lower two-third is cartilaginous.**

Bony part :- Consists of **two nasal bones.**

Cartilagenous part :- Consists of two upper lateral cartilages, two lower lateral cartilages, two or more lessar alar (or sesmoid) cartilages and a septal cartilage. So, there are 3 paired and 1 unpaired cartilages.

187. Indication of BAHA (Bone-anclored hearing aid)

a) Bilateral hearing loss

b) Sensorineural hearing loss

c) Congenital canal atresia

d) All of the above

Correct Answer - C
Ans. is 'c' i.e., Congenital canal atresia
Indications for BAHA

- When air-conduction (AC) hearing aid connot be used;
- Canal atresia, congenital or acquired, not amenable to treatment.
- Chronic ear discharge, not amenable to treatment.
- Excessive feedback and discomfort from air-conduction hearing aid.
- Conductive or mixed hearing loss, e.g. otoscierosis and tympanosclerosis where surgery is contraindicated.
- Single-sided hearing loss.

188. Muller's manoeuver is used ?

a) To findout opening of mouth

b) To remove laryngeal foreign body

c) To find degree of obstruction in sleep disordered breathing

d) To remove foreign body from ear

Correct Answer - C
Ans. is 'c' i.e., To find degree of obstruction in sleep disordered breathing

Muller's manoeuvre

- **Used to find the level and degree of obstruction in sleep-disordered breathing.**
- It is performed while using flexible nasopharyngoscope.
- First the examiner sees the upper airways at rest and then during the time when patient makes maximal inspiratory effort with nose and mouth closed.
- Base of tongue, lateral pharyngeal wall and palate are examined for collapsibility and then rated form 0 (minimal collapse) to 4+ (complete collapse).

189. Rosen's incision is used for ?

a) Septoplasty

b) SMR

c) Stapedectomy

d) Tonsillectomy

Correct Answer - C
Ans. is 'c' i.e., Stapedectomy

- Rosen's incision is the most commonly used for **stapedectomy** through endomeatal or transcanal approach. Also know
- Lempert's incision is used for endural approach.
- Wilde's incision is used for postaural approach.

190. Submandibular nodes are classified as ?

a) Level IA neck nodes

b) Level IB neck nodes

c) Level II neck nodes

d) Level III neck nodes

Correct Answer - B
Ans. is 'b' i.e., Level 1B neck nodes

- Division of neck nodes according to levels

Level I Submental (IA) **Submandibular (IB)**
Level II Upper jugular
Level III Mid jugular
Level IV Lower jugular
Level V Posterior triangle group (Spinal accessory and transverse cervical chains)
Level VI Prelaryngeal Pretracheal Paratracheal
Level VII Nodes of upper mediastinum

191. Hyponasal voice is seen in all except ?

a) Adenoids

b) Nasal polyp

c) Cleft palate

d) Habitual

Correct Answer - C
Ans. is 'c' i.e., Cleft palate

- Cause of hyponasality and hypernasality

Hyponasality	Hypernasality
Common cold	Velopharyngeal insufficiency
Nasal allergy	Congenitally short soft palate
Nasal polyp	Submucous palate
Nasal growth	Large nasopharynx
Adenoids	Cleft of soft palate
Nasopharyngeal mass	Paralysis of soft palate
Familial speech pattern	Post-adenoidectomy
Habitual	Oronasal fistula Familial speech pattern
Habitual speech pattern	

192. Schatzki's Ring is present at ?

a) Upper end of trachea

b) Lower end of trachea

c) Upper end of esophagus

d) Lower end of esophagus

Correct Answer - D
Ans. is 'd' i.e., Lower end of esophagus
Schatzki's ring

- It occurs at the junction of squamous and columnar epithelium at the lower end of oesophagus and has also been called **lower oesophageal ring.**
- Usually seen in patients above 50 years of age.
- Cause is unknown.
- Symptomatic patients complain of intermittent dysphagia and some may even present with bolus obstruction.
- It may be associated with hiatus hernia.
- Treatment is oesophageal dilatation.

193. "Rising sun" appearance is seen in -

a) ASOM

b) CSOM

c) Glomus tumor

d) Acoustic neuroma

Correct Answer - C
Ans. is 'c' i.e., Glomus tumor

Clinical features of glomus tumor

- The earliest symptoms of glomus tumour is pulsatile tinnitus (earliest) and hearing loss. Hearing loss is conductive and slowly progressive. These are followed by blood stained otorrhoea and earache.
- Before the tympanic membrane (eardrum) is perforated a red swelling is seen to arise from the floor of middle ear, i.e. **"Rising sun" appearance.** This results in a red reflex through the intact tympanic membrane.
- Sometimes, eardrum may be bluish and bulging. o Pulsation sign (Brown sign) is positive, i.e. when ear canal pressure is raised with Siegle's speculum, tumor pulsates vigorously and then blanches; reverse happens with release of pressure.
- Aquino sign is positive, i.e. blanching of mass with manual compression of ipsilateral carotid artery.
- When the tumour perforates the eardrum a polypus will be seen in the meatus and this will bleed profusely if touched.
- Cranial nerve palsies is a late feature appearing several years after aural symptoms. IXth to XIV' cranial nerves may be paralysed. This can cause dysphagia and hoarseness, and weakness of trapezius and sternocleidomastoid muscles, unilateral paralysis of soft palate,

pharynx and vocal cord.

- Ausculation with stethoscope over the mastoid may reveal audible systolic bruit.
- Some glomus tumours secrete catecholamines and produce symptoms like tachycardia, arrhythmias, sweating, flushing and headache etc.
- Facial palsy may be caused by glomus tympanicum type of glomus tumor.
- Audiometry shows conductive deafness, However if inner ear is invaded, mixed conductive and sensorineural hearing loss is seen.

194. Cart-wheel appearance of tympanic membrane in ASOM is due to ?

a) Perforation of tymparic membrane

b) Edema of tympanic membrane

c) Congested blood vessels along malleus

d) Granulation tissue on tympanic membrane

Correct Answer - C
Ans. is 'c' i.e., Congested blood vessels along malleus

Stages of ASOM

- ASOM runs through the following stages and therefore presentation depends upon the stage :
  1. Stage of tubal occlusion (Eustachian tube obstruction)
- Edema and hyperaemia of nasopharyngeal end of Eustachion tube blocks the tube, leading to absorption of air and negative intratympanic pressure.
- There is feeling of discomfort and mild hearing loss (conductive) with pink retracted tympanic membrane.
  2. Stage of presuppuration (Early infection)
- There is collection of inflammatory exudate behind the tympanic membrane.
- There is *marked Throbbing earache, hearing loss, tinnitus* and fever.
- **Tympanic membrane is congested. Leash of blood vessels appear along the handle of malleus and at the periphery of tympanic membrane imparting it a Cart-wheel appearance.**
  3. Stage of suppuration (suppurative stage)
- There is collection of frank pus in the middle ear.
- Patient has excruciating earache, hearing loss, and constitutional symptoms like high grade fever.

- Tympanic membrane is red and bulging with loss of landmarks.
  4. Stage of resolution (Resolution stage)
- The tympanic membrane ruptures with release of pus and subsidence of symptoms.
- Earache is relieved, fever comes down and child feels better.

195. In noice induced hearing loss, audiogram shows a typical notch at

a) 1000 Hz

b) 2000 Hz

c) 3000 Hz

d) 4000 Hz

Correct Answer - D
Ans. is 'd' i.e., 4000 Hz
Noise induced hearing loss

- Exposure to loud noise can lead to permanent hearing threshold shifts.
- This may happen immediately with extreme exposure (nearby explosion or gunfire), but more commonly occurs slowly over time with repeated exposure to industrial or environmental noise.
- Patients will often have a typical 4-KHz (4000 Hz) **notch (dip at 4000 Hz**) in their audiogram called acoustic dip.
- Auditory effects of noice are :?

1. Auditory fatigue :- at 90 d B and 4000 Hz.
2. Hearing loss
3. Temporary :- At 4000 - 6000 Hz
4. Permanent :- Repeated prolonged exposure to 100 d B or single exposure to 160 d B.

196. In sensorineural hearing loss, weber's test is lateralized to

a) Normal ear

b) Defective ear

c) Not lateralized

d) May alternate

Correct Answer - A
Ans. A. Weber test is lateralized to the unaffected or normal ear.
PURPOSE: Determination of a conductive vs.
a sensorineural hearing loss.

- Strike tuning fork and **place base in the center of the forehead or the top of the head**
- Ask if the tone is louder in the left ear, the right ear or equally loud in both ears due to the sound localization process,
- In a patient with a unilateral **conductive hearing loss**, the sound will be **louder in the affected ear** (airborne sounds mask bone conduction in the normal ear; conductive loss prevents masking in affected ear sound is perceived to be louder in affected ear)
- In a patient with unilateral **sensorineural hearing loss**, the sound is **louder in the normal ear** (no signal is transduced by the cochlea on the affected side, therefore the sound is louder on the normal side and is perceived to be coming from that side
- In a normal person or a person with symmetrical hearing loss, **it is equally loud in both ears.**
- In **other words, a normal patient, the Weber tuning fork sound is heard equally loudly in both ears, with no one ear hearing the sound louder than the other (lateralization). In a patient with hearing loss, the Weber tuning fork sound is heard louder in**

one ear (lateralization) than the other.

197. Which of the following is responsible for localization of sound ?

a) Cochlear nerve

b) Cochlea

c) Superior olivary nucleus

d) Cochlear nuclei

Correct Answer - C
Ans. is 'c' i.e., Superior olivary nucleus

Localization of sound in space

- A human can distinguish sounds originating from sources separated by as little as 1 degree. Binaural receptive fields (which is a feature of most auditory neurons above the level of cochlear nuclei) contribute to sound localization. In other words, relay nuclei in the brain stem (especially the **superior olivary nuclei complex**) mediate localization of sound. The auditory system uses following clues to judge the origin of sound :?
- Time lag between the entry of sound in two ears :- For example, if the sound originates from the right side of a person, it reaches the right ear earlier than the left ear. This time lag is more important for relatively low -frequency sounds (below 3000 Hz).
- Difference in intensities between the sound in the two ears :- It is important for sounds of higher frequencies (>3000 Hz).
- Sounds coming from directly in front of the individual and the back of the individual cannot be differentiated by the above two mechanisms. Here shape of pinna plays a role, it changes the quality of the sound depending on the direction from which sound comes.

198. Endolymph resembles ?

a) CSF

b) ICF

c) ECF

d) Plasma

Correct Answer - B
Ans. is 'b' i.e., ICF
Endolymph → Resembles intracellular fluid, rich in I^+ ions.
Perilymph (ectolymph) → Resembles ECF, rich in Na' ions.

- Perilymph communicates with CSF through cochlear acqueduct therefore has characteristics similar to CSF.

<u>Fluid in the inner ear</u>

- There are two main fluids in the inner ear : ?

1. Perilymph
2. Endolymph

Perilymph

- It resembles ECF and is rich in Na^+ ions. It fills the space between bony and the membranous labyrinth, i.e., Scala vestibuli and scala tympani.
- It communicates with CSF through the aqueduct of Cochlea which opens into the scala tympani near the round window. Therefore It closely resembles CSF.
- It is formed by : -

1. It is a fi iterate of blood serum and is formed by capillaries of the spiral ligament.
2. It is a direct continuation of CSF and reaches the labyrinth via aqueduct of cochlea.

Endolymph

- It fills the entire membranous labyrinth including scala media (cochlear duct).
- It resembles **intracellular fluid**, being rich in K" ions.
- It is secreted by the *secretory cells of the stria vascularis* of the cochlea and by the *dark cells* (present in the utricle and near the ampullated ends of semicircular ducts).

199. All are intracranial complications of otitis media except?

a) Lateral sinus thrombophlebitis

b) Facial nerve palsy

c) Brain abscess

d) Hydrocephalus

Correct Answer - B
Ans. is 'b' i.e., Facial nerve palsy

Intracranial Complications from Otitis Media

- Intracranial complications occur after the infectious (or inflammatory) process proceeds beyond the temporal bone "requiring immediate and precise therapeutic intervention."
- Most common intracranial complications include meningitis, followed by **brain abscess** and **lateral sinus thrombosis**, subdural empyema, epidural abscess, and **otic hydrocephalus.**

200. Most commonly used tuning fork in ear examination?

a) 128 Hz

b) 256 Hz

c) 512 Hz

d) 1024 Hz

Correct Answer - C
Ans. is 'c' i.e., 512 Hz

- Commonly used tuning fork has a frequency of **512 Hz.**
- Forks of other frequencies, e.g. 256 and 1024 Hz should also be available.

201.

Modified radical neck dissection includes which level of cervical lymph nodes?

a) I-Ill

b) I-IV

c) **I-V**

d) I-Vil

Correct Answer - C
Ans. is 'c' i.e., I-V

Radical neck dissection

- During radical neck dissection, following are removed.

a. Lymph nodes of submental, submandibular, upper, middle and lower jugular, and lateral (posterior) triangle regions, i.e. **Level I to V** along with its fibrofatty tissue.
b. Sternomastoid muscle.
c. Internal jugular vein.
d. Spinal accessory nerve.
e. Submandibular salivary gland.
f. Tail of the parotid.
g. Omohyoid muscle.

- Following structures are saved -
- Carotid artery
- Brachial plexus, phrenic nerve, vagus nerve, cervical sympathetic chain, marginal mandibular branch of facial, lingual and hypoglosal nerve.

Modified neck dissection

- It is similar to radical neck dissection but with preservation of one or more following structures -

a. Spinal accessory nerve

2. Internal jugular vein
3. Sternocleidomastoid muscle

- Thus, both radical neck dissection and modified radical neck dissection remove level Ito V neck nodes.
- Different levels of neck nodes heve been explained in previous sessions.

202. All are seen in treacher collin syndrome except

a) Conductive deafness

b) Cleft palate

c) Mandibular hypoplasia

d) Choanal atresia

Correct Answer - D
Ans. is 'd' i.e., Choanal atresia
Treacher collins syndrome

- It is rare condition that presents several craniofacial deformities of different levels.
- This is a congenital malformation involving the first and second branchial arches.
- The disorder is characterized by abnormalities of the auricular pinna, hypoplasia of facial bones, antimongoloid slanting palpebral fissures with coloboma of the lower eyelids and cleft palate.
- Important clinical findings are :-

1. Antimongoloid palpebral fissures
2. Malformed malleus and incus (normal stapes)
3. Coloboma of lower lid
4. **Conductive deafness**
5. **Hypoplasia of mandible** (micrognathia) and molar bones
6. **Cleft palate**
7. **Malformed pinna and meatal atresia**

- It is the most common benign neoplasm of nasopharynx.
- It is a highly vascular tumor and blood supply of the tumor most commonly arises from the internal maxillary artery.
- Juvenile nasopharyngeal angiofibroma (JNA) occurs almost

exclusively in males.

- Female with Juvenile nasopharyngeal angiofibroma (JNA) should undergo genetic testing.
- Onset is most commonly in the second decades, the range is 7-19 years.
- The exact cause is unknown. As the tumour is predominantly seen in adolescent males in the second decade of life, it is thought to be testosterone dependent.
- The most common site is posterior part of nasal cavity close to the margin of sphenopalatine foramen.
- The tumor starts adjacent to the sphenopalatine foramen.
- Large tumors are frequently bilobed or dumbbel shaped, with one portion of tumor filling the nasopharynx and the other portion extending to the pterygopalatine fossa.

Clinical features

- Symptoms depend on spread of tumour to nasal cavity, paranasal sinuses, pterygomaxillary fossa, infratemporal fossa, cheek, orbits (through inferior orbital fissure), cranial cavity (most common site is middle cranial fossa).
- Nasal obstruction (80-90%) is the most common symptom, especially in the initial stages. This results in denasal speech, hyposmia, broadening of nasal bridge.
- pontaneous profuse & recurrent epistaxis is the second most common symptom
- Otalgia, conductive hearing loss, serous otitis media, due to eustachian tube obstruction.
- Pink or purplish mass obstructing one or both chonae in nasopharynx.
- Tumour in the orbit causes : proptosis; and *frog-face deformity;* diplopia and diminshed vision.
- Tumour in infratemporal fossa can cause trismus and bulge of parotid.
- II, III, IV, V, VI cranial nerve can be involved.
- Splaying of nasal bones.
- Swelling of cheek and fullness of face.

Diagnosis and treatment

- Contrast CT is the investigation of choice.

- Biopsy should be avoided as it can cause severe bleeding.
- Surgical excision is the treatment of choice.

203. True about penderd's syndrome ?

a) Blindness

b) Conductive deafness

c) Sensorineural deafness

d) All of the above

Correct Answer - C
Ans. is 'c' i.e., Sensorineural deafness
Important features of Pendered syndrome:

- Congenital disorder
- Mutation in gene SLC 26 A4. Which codes for a protein called pendrin (helps in transport of ions across membrane).
- Impaired activity of Pendrin is seen in inner ear and thyroid gland.
- **Bilateral sensorineural hearing loss.**
- Goiter.
- Sometimes hypothyroidism.
- Occasionally vestibular dysfunction.
- No specific treatment.

204. Endoscopic sinus surgery prerequisite?

a) MRI of paranasal sinus

b) CT of PNS

c) Mucocilliary clearing testing

d) Acoustic tests

Correct Answer - B
Ans. is 'b' i.e., CT of PNS

- Endoscopic surgery of inflammatory diseases of **paranasal sinuses** (sinusitis or polyp) requires a very detailed preoperative knowledge of the individual anatomical conditions and pathological changes.
- CT scan are used best to visualize sinus areas.
- **CT scan provides excellent definition of paranasal sinuses and is a prerequisite for endoscopic surgery.**
- "CT scan limited study coronal cuts in bone window is prerequisite for endscopic sinus surgery"----Mohan Bansal

205. X-ray findings in chronic otitis media ?

a) Honeycombing of mastoid

b) Sclerosis with cavity in mastoid

c) Clear-cut distinct bony partition between cells

d) None of the above

Correct Answer - B
Ans. is 'b' i.e., Sclerosis with cavity in mastoid

206. What is not true about use of intranasal steroids in nasal polyposis?

a) Reduce recurrence

b) Reduce obstruction

c) Effective in eosinophilically predominant polyp only

d) May cause epistaxis

Correct Answer - C
Ans. is 'c' i.e., Effective in eosinophilically predominant polyp only

- Intranasal steroids have been used extensively as first-line management of nasal polyposis with few side effects
- Usually, patients with small polyps and limited involvement on CT scan are good candidates for topical therapy alone.
- Intranasal steroids reduce **nasal obstruction, polyp size, drainage and polyp recurrence.**
- The effect of steroids seems to be nonspecific, improving symptoms in both **eosinophilically and noneosinophilically dominated polyps.**
- **Nasal bleeding is the most common adverse event** and can usually be minimized by directing the medication away from nasal septum.

207. Referred ear pain may travel through all except?

a) Trigeminal nerve

b) Glossopharyngeal nerve

c) Abducens nerve

d) Vagus nerve

Correct Answer - C

Ans. is 'c' i.e., Abducens nerve

Referred otalgia

- As ear receives nerve supply from Vth (auriculotemporal branch), IXth (tympanic branch) and Xth (auricular branch) cranial nerves; and from C_2 (lesser occipital) and C_2 and C_3 (greater auricular), pain may be referred from these remote areas:

1. Via Vth cranial nerve

1. Dental : - Caries tooth, apical abscess, impacted molar, malocclusion.
2. Oral cavity : - Benign or malignant ulcerative lesions of oral cavity or tongue.
3. Temporomandibular joint disorders : - Bruxism, osteoarthritis, recurrent dislocation, ill-fitting denture.
4. Sphenopalatine neuralgia

- Vi intensity will hear it. Therefore, if identical vibrating tuning forks are held at equal distances from both ears they are heard in both ears. However, if one tuning fork is moved closer to one ear the person hears only that fork although the other fork is still vibrating sufficiently for him to hear. In stenger test, two vibrating tuning forks are held equidistant from either ear. If the patient is claiming

deafness in his left ear he will clain to hear only the fork on his right side. The fork on the left side is moved closer. If the patient is feigning deafness he will perceive only the tuning fork on the left side and will claim not to hear anything. If the patient has a genuine hearing loss on the left he will still hear the tuning fork on the right side.

2. Teal test

- This can be used when the patient admits to hearing bone conduction in his 'deaf' ear. The examiner stands behind the patient and applies a tuning fork to the mastoid process of his 'deaf' ear. The patient admits to
- a IXth cranial nerve

1. Oropharynx : - Acute tonsillitis, peritonsillar abscess, tonsillectomy. Benign or malignant ulcers of soft palate, tonsil and its pillars.
2. Base of tongue : - Tuberculosis or malignancy
3. Elongated styloid process.

3.Via Xth cranial cerve :

- Malignancy or ulcerative lesion of vallecula, epiglottis, larynx or laryngopharynx, oesophagus.

4. Via C_2 and C_3 spinal nerves :

- Cervical spondylosis, injuries of cervical spine, caries spine.

208. Acute retropharyngeal abscess, not true ?

a) Due to lymphadenitis

b) Common in adults

c) Swelling on one side of midline

d) Incision & drainage

Correct Answer - B
Ans. is 'b' i.e., Common in adults
Retropharyngeal abscess

- Retropharyngeal space lies behind the pharynx, i.e. between buccopharyngeal fascia covering pharyngeal constrictor muscles (anteriorly) and prevertebral fascia covering the prevertebral muscles (posteriorly).
- So, retropharyngeal space lies behind the pharyngeal constrictor muscles and anterior to prevertebral fascia covering the prevertebral muscles.
- Abscess in this space may present differently depending upon the age :?
- Abscess in infants (acute Retropharyngeal abscess)
- It is **commonly seen in infants and children below 3 years of age**. Most commonly it results from **retropharyngeal lymphadenitis** due to an upper respiratory tract infection. The presention is acute, i.e. child has high temperature and sore throat. There is smooth **swelling** (bulge) in posterior pharyngeal wall on **one side of the midline**. There is dysphagia, difficulty in breathing, stridor, croupy cough and torticollis. Swelling can be palpable per orally on the posterior pharyngeal wall. Treatment is incision and drainage.

- Abscess in adults (chronic retropharyngeal abscess)
- If an adult or an older child has a retropharyngeal infection it is likely to be due to a tuberculous infection of the cervical spine (caries of cervical spine). Sometime it may be secondary to tuberculous infection of retropharyngeal lymph nodes. It is of slow onset and gives rise to pharyngeal discomfort, rather than pain. There is fluctuant swelling in posterior pharyngeal wall, centrally in the midline (if it is secondary to caries of cervical spine) or on one side of midline (if it is secondary to tuberculosis of retropharyngeal nodes). Treatment includes **incision and drainage** of abscess along with full course of antitubercular treatment.

209. Proof puncture is done through ?

a) Superior meatus

b) Middle meatus

c) Inferior meatus

d) Sphenoethmoidal recess

Correct Answer - C
Ans. is 'c' i.e., Inferior meatus
Proof functure (Antral puncture)

- This procedure involves puncturing the medial wall of maxillary sinus in the region of **inferior meatus** and irrigating the sinus.
- Indications
  1. Chronic and subacute maxillary sinusitis with dual purpose of :
- Confirming the diagnosis and
- Washing out the pus
  2. To collect the specimen of the antral contents for culture and sensitivity, or cytological examination to exclude early malignancy.
- Contraindications
- Children less than 12 years of age.
- Acute maxillary sinusitis as it may lead to osteomyelitis
- Fracture of maxilla as fluid may pass through fracture line.
- Diabetes hearing it. The examiner then says that he is going to repeat the test, but puts a non-vibrating fork on the mastoid while at the same time bringing a vibrating fork close to the auricle. If the patient is malingering, he will hear the tuning fork through air conduction, but think that it is being heard through the bone. If he is really deaf he will not hear the fork.
  3. Lomard's test
- This depends upon the fact that to the normal man the sound of his

own voice is necessary for the proper regulation of its tone and loudness. The Barany noise apparatus is adjusted to the patient's sound ear and its machinery started in order to accustom him to its grating noise. He is given a book, and told to read aloud in his normal voice and not to stop reading when the instrument is set in action. As soon as the noise begins, a man whose opposite ear is profoundly deaf will at once raise his voice and, if his deafness is absolute, may literally shout. The malingerer, on the other hand, claiming a one-sided deafness which is not real will continue to read in an even tone or in a tone only slightly elevated.

4. Acoustic reflex (stapedial reflex threshold)

- If stapedial reflex is present, it rules out NOHL because stapedial reflex is not in voluntary control.

5. Electric response audiometry (ERA) or cortical evoked response audiometry

- It is very useful in NOHL and can establish hearing acuity of the person to within 5-10 dB of actual thresholds.

6. Other tests

- Gault test, Erhard's test, delayed speech feedback.

210. Inspiratory stridor is found in what kind of lesions:

a) Supraglottic

b) Subglottic

c) Tracheal

d) Bronchus

Correct Answer - A
Answer A. Supraglottic

- Generally, an inspiratory stridor suggests airway obstruction above the glottis.
- While an expiratory stridor is indicative of obstruction in the lower trachea.
- A biphasic stridor suggests a glottic or subglottic lesion.

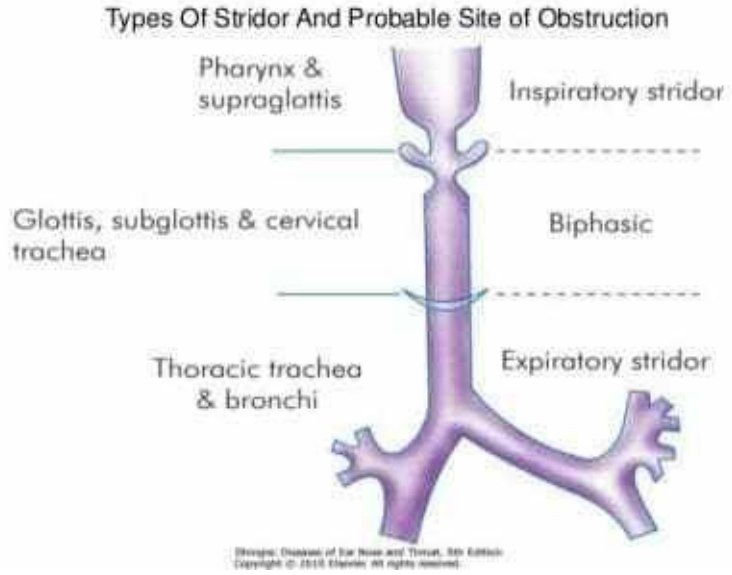

211. The most common site of the branchial cyst is:

a) Posterior border of sternocleidomastoid

b) Anterior border of sternocleidomastoid

c) Digastric muscle

d) Omohyoid muscle

Correct Answer - B
Answer. B. Anterior border of sternocleidomastoid

- A branchial cleft cyst (BCC) commonly presents as a solitary, painless mass in the neck of a child or young adult.
- They are most commonly located along the anterior border and the upper third of the sternocleidomastoid muscle in the anterior triangle of the neck.

Figure 1 Branchial cleft cyst in the neck

212. Lower limit of retropharyngeal space is at ?

a) C 7

b) Bifurcation of trachea

c) 4th esophageal constriction

d) None

Correct Answer - B

Ans. is'b'i.e., Bifurcation of trachea

Retropharyngeal space is divided into two lateral spaces (space of gillette) by a fibrous band.

Retropharyngeal space is limited above by the base of skull and below where the alar fascia fuses with buccopharyngeal fascia at the level of T4 and carina (bifurcation of trachea).

213. Retroauricular incision is also known as?

a) Rosen's incision

b) Lempert's -I incision

c) Lempert's-II incision

d) Wilde's incision

Correct Answer - D
Ans. is'd'i.e., Wilde's incision
[Ref: Dhingra Sth/e p. 410]

- Wilde's incision is used for postaural (retroauricular) approach.
- Lempert's incision is used for endaural approach.
- Rosen's incision is used for stapedectomy through endomeatal or transcanal approach,

214. Electrode of cochlear implant is placed at ?

a) Horizontal semicircular canal

b) Scala media

c) Scala tympani

d) Scala vestibuli

Correct Answer - C
Ans. is 'c' i.e., Scala tympani
[Ref Essentials otolaryngology 2d/e p. 82]
Cochlear implants

- Internal component : -
- It contains receiver/stimulator which is implanted under the skin and electrode which is implanted in the scala tympani of the cochlea a cochleostomy opening in the basal turn of cochlea.
- It may also be placed at other locations like promontory or round window but these sites has poorer performance.

215. Threshold of hearing in a young normal adult is ?

a) 0 dB

b) 10 dB

c) 20 dB

d) 30 dB

Correct Answer - A
Ans. is'a'i.e.,0 dB
[Rd Dhingra 4n/e p. 21]
Audiometric zero

- **Threshold of hearing, i.e. The faintest intensity which a normal healthy person can hear will vary from person to person.**
- The International Standards Organisation (ISO) adopted a standard for this, which is represented as the zero level on the audiometer (0 dB).
- According to ISO, audiometric zero is the mean value of minimal audible intensity in a group of normally hearing healthy young adults.

216. Nasopharyngeal carcinoma seen in which occupation?

a) Asbestos industry

b) Cement industry

c) Wood workers

d) Chimney workers

Correct Answer - C
Ans. is 'c' i.e., Wood workers
Ref Dhingra 4h/e p. 235; Nasopharyngeal carcinoma By Andrew Van Hasselt,

- Alan G. Gibb 2d/e p. 4
- Wood dusts exposure is a risk factor of nasopharyngeal carcinoma and
- Adenocarcinoma of PNS.
- Formaldehyde exposure is a risk factor of Nasopharyngeal carcinoma.

217. Investigation of choice for nasopharyngeal angiofibroma?

a) X-ray

b) MRI

c) Plane-CT

d) CT- contrast

Correct Answer - D
Ans. is'd'i.e., CT contrast
Ref: Dhingra Sth/e p. 262

- CT scan of head with contrast enhancement is the investigation of choice for JNA.

218. True about tubercular otitis media are all except?

a) Spreads through eustachian tube

b) Causes painless ear discharge

c) May cause multiple perforations

d) Usually affects both ears

e) None

Correct Answer - D

Answer- D. Usually affects both ears

- Tuberculosis of middle ear is a comparatively rare entity usually seen in association with or secondary to pulmonary tuberculosis, infection reaches the middle ear through eustachian tube.

Clinical features

- Generally, tuberculosis of middle ear is unilateral.
- It is characterized by painless otorrhoea which fails to respond to the usual antimicrobial treatment. There is painless watery otorrhea.
- Single or multiple perforation of tympanic membrane.

219. Feature of Granulomatosis with polyangiitis:

a) Nasal polyp

b) Perforated Nasal septum

c) Persistant sinus

d) Crusting of nasal mucosa

e) Collapse of nasal bridge

Correct Answer - B:C:D

Answer- (B) Perforated Nasal septum (C) Persistant sinus (D) Crusting of nasal mucosa

Granulomatosis with polyangiitis (Wegener) is a distinct clinicopathologic entity characterized by granulomatous vasculitis of the upper and lower respiratory tracts together with glomerulonephritis.

Disseminated vasculitis involving both small arteries and veins may occur.

Nasal findings include crusting granulations, septal perforation & a saddle nose

Destruction of the septum with a characteristic implosion of the nasal bridge.

220. Tensor tympani is attached at ?

a) Malleus

b) Incus

c) Stapes

d) Tympanic membrane

Correct Answer - A
Ans. is 'a' i.e., Malleus [Ref Gray's Anatomy 38th le p. 485]
Tympanic cavity has two muscles :

221. Vesicles on external ear are seen in

a) Otitis externa

b) Malignant otitis externa

c) Herpes zoster

d) Clear cell carcinoma

Correct Answer - C

Ans. is 'c' i.e., Herpes zoster [Ref Head and Neck Surgical Pathology p. 53]

Ramsay Hunt syndrome

It is lower motor neuron type of facial palsy due to Varicella (herpes) zoster. Pain is often a prominent feature and vesicles are seen in the ipsilateral ear, on the hard palate and/or on anterior two third of tongue. It may involve other cranial nerves-V, VIII, IX and X and cervical branches (C_2, C_3 & C_4) that have anastomotic communications with facial nerve. This results in features like :

- Anaesthesia of face
- Giddiness
- Hearing impairment along with VII nerve palsy.

222. First line treatment for mild retraction pocket in the ear is

a) Observation

b) Antibiotics

c) Tympanostomy tube

d) Surgical excision

Correct Answer - B

Ans. is 'b' i.e., Antibiotics [Ref Conquering Otitis media by Charles Bluestone p. 95]

Retraction pocket

- It must be treated by an otolaryngologist.

1) Antibiotics

- A mild retraction pocket that is present in a fluid - filled middle ear can first be treated with antibiotics.

2) Tympanostomy

- If antibiotics does not work, a tympanostomy tube is usually inserted, and in most cases, the eardrum will return to normal.
- If the retraction pocket is very deep, a tube should be inserted, bypassing the antibiotic treatment.

3) Surgical excision

- If the retraction pocket still does not go away, the deformed eardrum should be operated on to prevent a cholesteatoma from developing.
- Once a cholesteatoma develops, surgery is the only way to remove it.

223. Cristae are seen in?

a) Utricle

b) Saccule

c) Semicircular canal

d) Otolith membrane

Correct Answer - C

Ans. is 'c' i.e., Semicircular canal *[Ref Dhingra Sth/e* p. *16]*

Vestibular apparatus

- The vestibular apparatus *within the inner ear* detects head motion and position and transduces this information to a neural signal.

224. Function of saccule is?

a) Linear acceleration

b) Angular acceleration

c) Senses position of head

d) Rotational movement

Correct Answer - A:C
Ans. is *'a' i.e.,*Linear acceleration & 'c' i.e.,Senses position of head

225. Earliest age for doing BERA is?

a) In utero - before birth

b) At birth

c) 3 months

d) 6 months

Correct Answer - B

Ans. is 'b' i.e., At birth [Ref Logan Turner 10thle p. 254; PL Dhingra 4th/e p. 28]

"Worldwide screening is largely performed in newborn nursery with the first screening test performed from birth until 10 days of age"

226. Most common malignancy of middle ear is

a) Glomus tumor

b) Squamous cell carcinoma

c) Adenocarcinoma

d) Sarcoma

Correct Answer - B

Ans. is 'b' i.e.,Squamous cell carcinoma *[Ref Textbook of ENT by Rakesh Shrivastav 2"/e p. 67]*

- Squamous cell carcinoma is the most common malignant tumor of the middle ear.
- Other forms of malignancy like adenocarcinoma and sarcoma are rare.

227. Most common benign tumor of ear canal is

a) Osteomas

b) Sebaceous adenoma

c) Papilloma

d) Ceruminoma

Correct Answer - A

Ans. is 'a' i.e., Osteomas [Ref Dhingra 6th le p. 107; Bansal ENT p. 160; Encyclopedia of Imaging, Baert p. 1318]

Osteomas/ exostoses → most common benign tumors of the external auditory canal.

Squamous cell carcinomas → Most common malignant tumors of the external auditory canal.

228. Diplacusis is

a) Hearing sound with diminished intensity

b) Hearing sounds of two different tones

c) Hearing extremely loud sound

d) Perceiving light on production of sound

Correct Answer - B

Ans. is 'b' i.e.,Hearing sounds of two different tones *[Ref Tuli Ist/e p. 114]*

- Monaural diplacusis :- In monaural diplacusis, a listener hears two tones when a single tone is presented to a single ear, i.e. one ear hears two different tones when presented one.
- Binaural diplacusis :- In binaural diplacusis, a listener hears two different tones in right & left ear when a single tone is presented to both ears.
- Both monoaural and binaural diplacusis are caused by inhomogenities in the cochlea that also give rise to spontaneous otoacoustic emissions.

229. Which semicircular canal is most commonly involved in BPPV?

a) Horizontal

b) Posterior

c) Superior

d) All of the above

Correct Answer - B

Ans. is 'b' i.e., Posterior *[Ref Dhingra Sth/e p. 51]*

- BPPV is thought to be caused by displacement of otoconia (mineral crystals) from the vestibule of inner ear into the semicircular canals. The posterior semicircular canal is most commonly involved, though superior and horizontal canals canal can also be affected.
- Otoconia or ear rocks are small crystals of calcium carbonate derived structure in the utricle which migrate into semicircular canals and cause BPPV. While saccules also contains otoconia, they are not able to migrate into the semicircular canals.

230. Most common ossicle affected due to trauma -

a) Malleus

b) Incus

c) Stapes

d) All affected similarly

Correct Answer - B

Ans. is 'b' i.e, Incus *[Ref Hearing : Practical Guide by Tysome p. 96]*

"Significant head injury or direct trauma to the middle ear can result in subluxation of one or more of the ossicles, the incus being the most commonly affected

231. Singapore ear is

a) Hypertrophy of sweat glands

b) Hypertrophy of sebaceous glands

c) Otitis externa

d) Excoriation of external ear skin

Correct Answer - C

Ans. is 'c' i.e, Otitis externa [Ref Clinical ENT 5th/e p. 223]

Excessive moisture is an important predisposing factor for otitis externa as excessive moisture elevates the pH and removes protective cerumen. Therefore, humidity and hot climate predispose to otitis externa. Hence otitis externa is also known as :-

1. Singapore ear (where climate is hot and humid)
2. Swimmer's ear
3. Telephonist's ear (telephonists who require inserts in their ear have excessive moisture due to sweating).

232. A diabetic patient presents with foul smelling ear discharge, fever and severe pain in the ear. On examination there is thick yellow coloured discharge from the ear and granulation tissue in the canal. Which of the following is the appropriate management for this patient?

a) Surgical debridement

b) Antibiotic therapy

c) Cryotherapy

d) Laser removal of granulation tissue

Correct Answer - B

Ans. is 'b' i.e., Antibiotic therapy *[Ref Dhingra 6th/e p. 52]*

- The patient described in the question most likely has malignant otitis externa.
- So the treatment of choice is anti - pseudomonal antibiotics.
- Extensive surgical debridement once an important part of the treatment is now rarely needed

233. Topodiagnosis of facial nerve has all the tests except

a) Schirmer test

b) Bing test

c) Taste test

d) Salivary flow test

Correct Answer - B

Ans. is 'b' i.e., Bing test [Ref Dhingra 6th/e p. 98]

The following tests are useful in finding the site of lesion in paralysis of lower motor neuron.

1. Schirmer test : It compares lacrimation of the two sides. A strip of filter paper is hooked in the lower fornix of each eye and the amount of wetting of strip measured. Decreased lacrimation indicates lesion proximal to the geniculate gan- glion as the secretomotor fibres to lacrimal gland leave at the geniculate ganglion via greater superficial petrosal nerve.
2. Stapedial reflex : Stapedial reflex is lost in lesions above the nerve to stapedius. It is tested by tympanometry.
3. Taste test : It can be measured by a drop of salt or sugar solution placed on one side of the protruded tongue, or by electrogustometry. Impairment of taste indicates lesion above the chorda tympani.
4. Submandibular salivary flow test : It also measures func- tion of chorda tympani. Polythene tubes are passed into both Wharton ducts and drops of saliva counted during one minute period. Decreased salivation shows injury above the chorda.

234. Which of the following is the function of tensor tympani muscle?

a) Dampen very loud sound

b) Tenses tympanic membrane

c) Tenses pharyngotympanic tube

d) Prevent noise trauma to the inner ear

Correct Answer - B

Ans. is 'b' i.e., Tenses tympanic membrane [Ref Dhingra 6"/e p. 8]

Normal opening of the eustachian tube equalizes atmospheric pressure in the middle ear; closing of the Eustachian tube protects the middle ear from unwanted pressure fluctuations and loud sounds.

The muscles of the eustachian tube system help to open and close the tube, thus allowing it to perform its function.

The muscles are :?

1. Tensor veli palatini (tensor palatini) :- Contraction of this muscle during swallowing, yawning and sneezing opens the tube. Defective function of this muscle in cleft palate results in eustachian tube dysfunction.
2. Tensor tympani :- Tensonises the tympanic membrane.
3. Levator veli palatini :- Sometimes, it also helps to open the tube, however it is usually considered as a velopharyngeal valve muscle only.
4. Salpingopharyngeus :- Its functional significance is questionable.

235. Pink reflex through intact tympanic membrane in active otosclerosis is known as

a) Schwabach's sign

b) Schwartz sign

c) Lyre's sign

d) Chvostek's sign

Correct Answer - B

Ans. is 'b' i.e., Schwartz sign ***[Ref Dhingra 5th/e p. 98; Current otolaryngology 2nd/e p. 674]***

- **A reddish hue / Flammingo pink may be seen on the promontory and oval window niche owing to the prominent vascularity associated with an otospongiotic focus. This is k/a Schwartz sign.**
- **Schwartz sign is a pink reflex, seen through intact tympanic membrane, in the area of oval window. It indicates active otosclerosis** usually during pregnancy.
- Lyre's sign is splaying apart of internal and external carotid arteries on angiogram in cases of carotid body tumour of the neck.
- Chvostek's sign seen in hypocalcaemia as after total thyroidectomy where parathyroids have also been removed. Tapping over the distribution of facial nerve produces a twitch.

236. SADE classification classifies

a) Retraction of tympanic membrane

b) Extension of Glomus tumor

c) Mortality after heart disease during pregnancy

d) Extent of CSF rhinorrhea

Correct Answer - A

Ans. is 'a' i.e., Retraction of tympanic membrane *[Ref Basic Clinical Radiobiology 5th/e p. 942]*

Sade's classification of retraction of the pars tensa of the tympanic membrane defined two types of retraction and classified each on an ordinal scale :?

1. Atelectasis, defined as diffuse 'retraction of the tympanic membrane towards the promontorium'.
2. Retraction pocket, defined as focal 'retraction of the pars tensa towards or into the attic'.

237. A 10 year old child presents with non foul purulent smelling discharge, which is painless. Patient reports that he is able to hear better in the presence of discharge than when the ear is dry. The most probable diagnosis is

a) CSOM

b) Serous otitis media

c) Cholesteatoma

d) Mastoiditis

Correct Answer - A

Ans. is 'a' i.e., CSOM *[Ref Dhingra 6th /e* p. *68]*

- Clinical features of CSOM
- Profuse mucopurulant discharge which is not foul smelling, i.e., non foul smelling discharge .
- Hearing loss (conductive type). If sensorineural component also occurs (i.e., mixed type), it arouses the suspician of toxic deafness.
- Sometimes, patient reports a paradoxical effect, i.e., hears better in the presence of discharge than when the ear is dry. This is due to round window shielding effect produced by discharge which helps to maintain phase differential.
- There is no pain, if it occurs it is due to associated otitis externa not due to otitis media.
- Since the infected area is open at both ends, discharge does not accumulate in the middle ear cavity.
- Ossicular chain is mostly uninvolved, if involved only long process of

incus is involved.

238. Treatment of central safe perforation of tympanic membrane includes all except

a) Aural toilet

b) Ear drops

c) Avulsion of aural polyp

d) Myringoplasty

Correct Answer - C

Ans. is 'c' i.e., Avulsion of aural polyp ***[Ref Dhingra 6th le* p. *72]***

- An aural polyp should never be avulsed as it may be arising from the stapes, facial nerve or horizontal canal and thus lead to facial paralysis or labyrinthitis.

Treatment

The aim is to control infection and eliminate ear discharge and at a later stage to correct the hearing loss by surgical means.

1. Aural toilet : Remove all discharge and debris from the ear. It can be done by dry mopping with absorbent cotton buds, suction clearance under microscope or irrigation (not forceful syringing) with sterile normal saline. Ear must be dried after irrigation.
2. Ear drops : Antibiotic ear drops containing neomycin, polymyxin, chloromycetin or gentamicin are used. They are combined with steroids, which have local antiinflammatory effect.
3. Systemic antibiotics : They are useful in acute exacerbation of chronically infected ear, otherwise role of systemic antibiotics in the treatment of CSOM is limited.
4. Precautions : Patients are instructed to keep water out of the ear during bathing, swimming and hair wash. Rubber inserts can be used. Hard nose blowing can also push the infection from nasopharynx to middle ear and should be avoided.

5. Treatment of contributory causes : Attention should be paid to treat concomitantly infected tonsils, adenoids, maxillary antrum and nasal allergy.
6. Surgical treatment : Aural polyp or granulations, if present, should be removed before local treatment with antibiotics. It will facilitate ear toilet and permit ear drops to be used effectively.
7. Reconstructive surgery: Once ear is dry, myringoplasty with or without ossicular reconstruction can be done to restore hearing. Closure of perforation will also check repeated infection from the external canal.

239. Agger nasi is

a) Mucosal flap covering the nasolacrimal duct

b) Opening of the sinuses

c) Depression in front of middle turbinate

d) Elevation anterior to middle turbinate

Correct Answer - D

Ans. is 'd' i.e., Elevation anterior to middle turbinate *[Ref Dhingra 5th ie p. 150; Tuli 1"/e* p. *135]*

Atrium is a shallow depression in front of the middle turbinate. Agger nasi is an elevation just anterior to the attachement of middle turbinate.

240. Quadrungular septum is seen in which of the following?

a) Larynx

b) Nose

c) Cranium

d) Palate

Correct Answer - B

Ans. is 'b' i.e., Nose *[Ref Dhingra 5th/e p. 150]*

"Cartilage of the septum, also known as the quandragular cartilage because it is roughly quadrilateral in shape - separates the nostrils".

241. Nasal vestibule is

a) Lateral part of nasal cavity

b) Antero - inferior part of nasal cavity

c) Supero - medial part of nose

d) Posterior aperture of nose

Correct Answer - B

Ans. is 'b' i.e., Antero - inferior part of nasal cavity*[Ref Otolaryngology Basic Science & Clinical Review by Van De Water p. 462]*

Internal nose has following parts :

- Nasal cavity proper:- Internal nose is divided into right and left nasal cavities by nasal septum. Each nasal cavity communicates with the exterior through naris or nostrils and with nasopharynx through posterior nasal aperture or posterior nares or choana.
- Vestibule of nose :- Anterior and inferior part of the nasal cavity is lined by skin and is called vestibule of nose. It contains sebaceous glands, hair follicles and the hair called vibrissae.

242. Which of the following terms is used to describe the most prominent point of nasal tip?

a) Pronasale

b) Alare

c) Nasion

d) Columella apex

Correct Answer - A

Ans. is 'a' i.e., Pronasale [Ref Handbook of anthropometry: Physical measures of human form in health and diseases, by Victor R. Preedy, p. 922]

- Pronasale : Most prominent point on the nasal tip.
- Alare : The point where the nasal blade (Ala nasi) extends the farthest out.
- Columella apex : The most anterior or the highest point on the columella crest at the apex of the nostril.
- Nasion : The point in the midline of both the anatomic nose and the nasoanterioral suture

243. Epistaxis after ligating external carotid artery is due to which vessel?

a) Anterior ethmoidal artery

b) Superior labial artery

c) Sphenopalatine artery

d) Greater palatine artery

Correct Answer - A

Ans. is 'a' i.e., Anterior ethmoidal artery *[Ref Dhingra 5th ie p. 190]*

- Since external carotid artery is ligated, the bleeding comes from branches of the internal carotid artery.
- Anterior ethmoidal artery, a branch of ophthalmic artery, which is a branch of internal carotid artery, is a constituent of the blood supply of the Little's area of the nasal septum.

Blood supply of nasal septum

i) Internal carotid system

- Anterior ethmoidal artery
- Branches of ophthalmic artery
- Posterior ethmoidal artery

ii) External Carotid System

- Sphenopalatine artery (branch of maxillary artery) gives nasopalatine and posterior medial nasal branches.
- Septal branch of greater palatine artery (Br. of maxillary artery).
- Septal branch of superior labial artery (Br. of facial artery)

244. Killian's polyp is a/an

a) Antrochoanal polyp

b) Ethmoidal polyp

c) Frontal polyp

d) Maxillary polyp

Correct Answer - A

Ans. is 'a' i.e., Antrochoanal polyp *[Ref Dhingra 5th/e p. 186; Essential otolaryngology 2"1/e p.* 660]

Nasal polyps are of two types :?

- Antrochoanal :- This is usually solitary and arises from maxillary sinus and grows backward in the nose towards the choana (in contrast to ethmoidal polyps which tend to grow forward). The Antrochoanal polyp was first described by Gustain killians, therefore the name given to it was killian's polyp.
- Ethmoidal :- These are multiple, bilateral and arise from etmoidal sinuses and tend to protrude forwards.

245. Which of the following is the predisposing factor for ethmoidal carcinoma

a) Smoking

b) Alcohol

c) Chronic infection

d) All of the above

Correct Answer - A

Ans. is 'a' i.e., Smoking *[Ref Diseases of ENT by Bansal p.* 363]

Risk factors for squamous cell carcinoma of the paranasal sinuses :-

- Smoking , Mustard gas, Nickel and chromium plating industry, Isopropyl oil
- Leather industry , Wood dust exposure (adenocarcinoma of ethmoid), Polycyclic volatile hydrocarbons

246. Most common sinus predisposed to malignancy which of the following?

a) Ethmoid

b) Maxillary

c) Frontal

d) Sphenoid

Correct Answer - B

Ans. is 'b' i.e., Maxillary ***[Ref Dhingra 5thie p. 219]***

- The majority of paranasal sinus malignancies (50-80%) originate within the maxillary sinus antrum.
- Sinuses and various conditions in which sinuses are affected in descending order of frequency

247. Most common benign tumor of paranasal sinuses?

a) Papilloma

b) Osteoma

c) Warts

d) Fibroma

Correct Answer - B

Ans. is 'b' i.e., Osteoma ***[Ref Logan Turner 8`h/e p. 89]***

- Osteoma of the frontal sinus - Most common benign tumour arising in the nasal sinuses.
- The osteoma arises from the floor of the frontal sinus near the midline.

248. Treatment of nasal bone fracture includes all except

a) Hematoma drainage

b) Topical vasoconstrictor

c) Closed reduction

d) Immediate rhinoplasty

Correct Answer - D

Ans. is 'd' i.e., Immediate rhinoplasty *[Ref Scott* Brown *7th/e p. 1612]*

Treatment of nasal injuries

- After ensuring patency of airway, adequate ventilation and overall stability of patient, attention to the nasal injuries should be given.
- Standard therapy is to perform closed reduction or open reducation between 3 and 7 days, and upto 2 weeks. This is because :
- Most of the patients (-70-80%) do not require any active treatment, as many do not have a nasal fracture and those that do, the fracture is not displaced. Soft tissue swelling can produce the misleading appearance of a deformity which disapears as the swelling subsides. Such patients require only reassurance & topical vasoconstrictors to alleviate congestion and obstructive symptoms. A re-examination should be carried out after 5 days, if there is uncertainity about the need for reduction.
- A large number of patients will have a preexisting nasal deformity caused by a previous incident. Patients that fall in this category are advised to consider a formal rhinoplasty when everything has settled down some months later.
- Immediate surgical intervention in acute phase is indicated : ?
- Severe deformity:- Septal hematoma causing nasal obstruction

249. All of the following are true about parapharyngeal abscess except?

a) Mastoid process divides the space into anterior and posterior

b) Also known as pharyngomaxillary space infection

c) Tonsil is pushed medially

d) Occurs after tooth extraction

Correct Answer - A
Ans. is 'a' i.e., Mastoid process divides the space into anterior and posterior *[Ref Dhingra V/e p. 281]*
Styloid process and the muscles attached to it divide the parapharyngeal space into anterior and posterior compartments, not mastoid process.

250. Lining epithelium of vocal cord is

a) Stratified squamous epithelium

b) Non stratified squamous epithelium

c) Ciliated columnar epithelium

d) Non ciliated columnar epithelium

Correct Answer - A

Ans. is 'a' i.e., Stratified squamous epithelium [Ref Dhingra Vie p. 300]

Vocal cords along with the upper part of the vestibule is the only part of laryngeal mucous membrane which is lined by epithelium of stratified squamous type. Elsewhere in the larynx epithelium of the mucous membrane is ciliated columnar type.

251. Which of the following sites of Ca larynx has the best prognosis?

a) Glottic

b) Supraglottis

c) Subgottis

d) All have poor prognosis

Correct Answer - A

Ans. is 'a' i.e.,Glottic ***[Ref Dhingra 5th/e p. 326]***

Laryngeal carcinoma:-

Cancer	Prognosis
Glottis	Good
Supraglottis	Poor
Subglottis	Worst

252. Laser used in tracheal neoplasm is

a) Argon

b) KTP - 532

c) CO_2

d) Nd - YAG

Correct Answer - C

Ans. is 'c' i.e., CO_2 [Ref Dhingra 5th/e p. 315]

- Four types of laser are generally used in ENT surgery :
- Argon
- KTP - 532 (Potassium titanyl phosphate);
- Nd : YAG (Neodyminum - yttrium aluminium garnet);
- CO2
- The carbon dioxide (CO) laser is the most common laser used for tracheal neoplasm.

253. Most common site of distant metastasis from Ca larynx

a) Lymph nodes

b) Lung

c) Brain

d) Bone

Correct Answer - B

Ans. is 'b' i.e., Lung [Ref Clinical Otorhinolaryngology yd /el). 931]

Distant metastasis is seen much less frequently. The most commonly affected sites for distant metastases are lungs (66%); bone (22%), liver (10%), mediastinum and bone marrow.

254. A patient presents with Ca larynx involving left false cord, left arytenoid and left aryepiglottic fold with bilateral mobile true cords. The treatment of choice in this patient is which of the following?

a) Vertical hemilarygectomy

b) Horizontal partial hemilaryngectomy

c) Total laryngectomy

d) Radiotherapy followed by chemotherapy

Correct Answer - B

Ans. is 'b' i.e., Horizontal partial hemilaryngectomy *[Ref Dhingra 4th/e* p. *284]*

Involvement of unilateral false cord, aryepiglottic folds and arytenoids with mobile cord suggests supraglottic cancer in T2 stage (more than one subsites of supraglottis are involved).

255. In recurrent laryngeal nerve palsy which muscle keeps vocal cord in median position?

a) Posterior cricoarytenoid

b) Cricothyroid

c) Vocalis

d) All of the above

Correct Answer - B

Ans. is 'b' i.e., Cricothyroid [Ref Dhingra 5th/e p. 300]

Recurrent laryngeal nerve paralysis

Recurrent laryngeal nerve supplies : ?

- All intrinsic muscles of the larynx except cricothyroid.
- Sensory supply to larynx below vocal cords.

So, paralysis of recurrent laryngeal nerve causes : ?

- Paralysis of all intrinsic muscles including all adductors (except for cricothyroid) and all abductors.
- Anaesthesia below the level of vocal cord.
- Though, there is paralysis of both adductors (except cricothyroid) and abductors, the manifestations are mainly due to paralysis of abductors.

256.

Food particles mostly get obstructed in which part of esophagus -

a) Cricopharyngeal sphincter

b) Crossing of arch of aorta

c) Cardiac end

d) None of the above

Correct Answer - A

Ans. is 'a' i.e, Cricopharyngeal sphincter [Ref: Dhingra 6thie p. 349]

By far the commonest site is at or just below the cricopharyngeal sphincter. Flat objects like coins are held up at the sphincter while others are held in the upper oesophagus just below the sphincter due to poor peristalsis.

257. True regarding traction diverticuli of esophagus is all except

a) Does not empty completely

b) Triangular appearance

c) Contains all layers

d) Maintains elastic recoil

Correct Answer - A

Ans. is 'a' i.e., Does not empty completely ***[Ref The Esophagus by Richter p. 143]***

	Traction Diverticula	**Pulsion Diverticula**
Type	True diverticula	False diverticula
Layers	Lined by all layers	Ususally only mucosal outpouchings
Location	Mid esophagus	Distal esophagus
Associated	Scarring from TB or histoplasmosis involving perihilar or subcarinal lymph nodes	Associated with dysmotility
Shape	Triangular or tented	Rounded outpouchings
Emptying	Tends to empty contents	Do not empty completely
		Epiphrenic diverticula, Zenker's diverticula

258. Sluder's neuralgia is also called as

a) Anterior ethmoidal syndrome

b) Posterior ethmoidal syndrome

c) Trotter syndrome

d) Lermoyez syndrome

Correct Answer - A

Ans. is 'a' i.e., Anterior ethmoidal syndrome [Ref Dhingra 6th/e p. 450]

Sluder's neuralgia

- It is also called anterior ethmoidal syndrome.
- It is said to originate from the middle turbinate pressing on the nasal septum.
- It is characterized by pain around the bridge of the nose radiating into forehead.
- Treatment Anatomical correction relieves the pain.

259. Most common tumor of oropharynx is

a) Squamous cell carcinoma

b) Adenocarcinoma

c) Melanoma

d) Salivary gland tumors

Correct Answer - A

Ans. is 'a' i.e., Squamous cell carcinoma *[Ref Abeloff's Clinical Oncology 6" le p. 1059]*

90 – 95% of tumors in the oropharynx are squamous cell carcinomas, whereas others are minor salivary gland tumors, melanomas.

The most common manifesting symptoms are a nontender neck mass, dysphagia, otalgia, or a "hot potato" voice.

260. Investigation of choice for diagnosing submandibular gland duct stones is

a) Ultrasound

b) X-ray of floor of mouth

c) Sialography

d) Sialoendoscopy

Correct Answer - A

Ans. is 'a' i.e., Ultrasound *[Ref Churchill's pocket book of surgery p. 133]* Investigations for salivary gland stones

- Ultrasound is the investigation of choice – as it permits assessment of the gland, duct system and calculus which usually has an acoustic shadow.
- 'Floor of mouth' radiographic view for submandibular calculi in Wharton's duct where ultrasound findings are equivocal or unavailable.
- If no stone is seen, consider sialography.
- Sialoendoscopy is increasingly used in the diagnosis and treatment of salivary gland outflow obstructive conditions.

261. Deafness in a case of Paget's disease is due to

a) Retraction pockets

b) Otitis

c) Eight nerve involvement

d) Endolymphatic hydrops

Correct Answer - C

Ans. is 'c' i.e., Eight nerve involvement [Refer Neurology consult 5"/e p. 866]

Cranial nerve compression is the usual cause of deafness.

Complications of Paget's disease

Following complications can occur in Paget's disease : -

1. Fracture : Are common in weight bearing bones
2. Cranial nerve compression :- May cause impaired vision, facial palsy, trigeminal neuralgia or deafness.
3. Otosclerosis : - Another cause of deafness in Paget's disease.
4. Spinal canal stenosis and nerve root compression
5. High output cardiac failure
6. Osteoarthritis : of Hip and knee
7. Rarely osteosarcoma

262. Membrane incised during hemilaryngectomy is

a) Thyrohyoid

b) Cricothyroid

c) Aryepiglottic

d) Infralaryngeal

Correct Answer - B

Ans. is 'b' i.e., Cricothyroid *[Ref Dhingra ele* p. *310]*

- Indications and containdications
- Ideal for bulky lesions of the membranous true vocal cord
- Normal or slightly impaired vocal cord mobility
- No involvement of the supraglottis

263. Callaural fistula is an abnormality of ?

a) 1" branchial arch

b) P^t branchial cleft

c) 2nd branchial arch

d) 2nd branchial cleft

Correct Answer - B

Ans. is 'b' i.e., P^t branchial cleft

- **Collaural fistula** is a **1" branchial cleft** anomaly which arises from failure of fusion of the ventral part of the P^t cleft.
- Its **upper part** opens into *floor of external auditary canal.*
- Its *lower part* opens in the neck between angle of mandible and sternocleidomastoid muscle.

264. Acute suppurative otits media in children is most commonly caused by ?

a) St. pneumoniae

b) S. epidermidis

c) S. aureus

d) Pseudomonas

Correct Answer - A

Ans. is 'a' i.e., St. pneumonia [Ref Dhingra 5thIe p. 54]

- ASOM is especially common in infants and children. Most of the time ASOM usually follows respiratory tract infections (i.e., acute tonsillitis, common cold or influenza) and the infection travel up by the eustachian tube to the middle ear.
- The most common causative organism is streptococcus pneumoniae

265. Young's operation is done for

a) Allergic rhinitis

b) Atropic rhinitis

c) Vasomotor rhinitis

d) Idiopathic rhinitis

Correct Answer - B

Ans. is 'b' i.e., Atrophic rhinitis ***[Ref Dhingra 5th/e p. 171; Essential otolaryngology 2"d/e p. 523]***

Surgical treatment of Atrophic rhinitis

1. Young's operation
2. Modified Young's operation
3. Narrowing of the nasal cavity by (Lautenslagers operation)
4. Lautenslagers operation

266.

All of the following are are a part of medial wall of the middle ear except?

a) Promontory

b) Fenestra vestibule

c) Pyramid

d) Subiculum

Correct Answer - C

Ans. is 'c' i.e.,Pyramid [Ref Dhingra Save **p. 6]**

Medial or inner or labyrinthic wall (paries labyrinthica) of middle ear

- It is formed by labyrinth and separates the middle ear cavity from internal ear. It has following features :- **A bulge called as promontory formed by basal turn of cochlea.**
- **Fenestra vestibuli (oval window)** lies posterosuperior (behind and above) to the promontory and opens into scala vestibuli.
- **It is occupied by foot plate of stapes** fixed by annular ligament. Its, **size on average is 3.25 mm long & 1.75 mm wide.**
- **Fenestra cochleae (round window)** lies posteroinferior to the promontory and opens into scala tympani of cochlea. **It is closed by secondary tympanic membrane.** The round window is closest to ampulla of posterior semicircular canal. Round window is a triangular opening. **Its diameter is between 1.8 to 2.3 mm.**

267. What is the intensity in decibel of normal conversation in humans?

a) 30dB

b) 60dB

c) 90dB

d) 150dB

Correct Answer - B

Ans. is 'b' i.e., 60dB [Ref Dhingra 5thIe p. 23]

- Intensity is the strength of sound which determines its loudness. It is usually measured in decibels (dB).
- Following are intensities when a person is at a distance of one meter from sound source.

Whisper	30 dB
Normal conversation	60 dB
Shout	90 dB
Discomfort of ear	120 dB
Pain in ear	130 dB

268. What is the role of Sodium Fluoride in otosclerosis?

a) It restores the electrolyte equilibrium

b) It hastens recovery of the Overstimulated Cochlea

c) It quickens the maturity of the active focus and reduces osteoclastic resorption

d) It repolarizes the cochlear cells

Correct Answer - C

Ans. is 'c' i.e., It quickens the maturity of the active focus and reduces osteoclastic resorption

[Ref Current Diagnosis and treatment in Otolaryngology 2nd/e p. 678; Otosclerosis and Stapedectomy: Diagnosis, Management, and Complication by Glasscock (7hieme) 1st (2004) p. 61, 62]

Mechanism of action of Sodium fluoride in otosclerosis

1. Reduces osteoclastic bone resorption and increases osteoblastic bone formation : These actions reduce bone remodelling in actively expanding osteolytic lesions and promote recalcification.
2. Inhibits proteolytic enzymes that are cytotoxic to the cochlea : Inhibition of proteolyic enzymes that are cytotoxic to the cochlea is believed to prevent sensorineural deafness.

269. Chemical labyrinthectomy by transtympanic route is done in Meniere's disease using which drug?

a) Amikacin

b) Gentamicin

c) Amoxycillin

d) Cyclosporine

Correct Answer - B
Ans. is 'b' i.e., Gentamicin [Ref Levine SC, Haberkamp TJ. Labyrinthectomy to correct vertigo
Operative techniques in otolaryngology - Head & neck surgery. 2001. 12:141-143.]
Chemical labyrinthectomy in meneires disease is done using Gentamicin loca**lly.**

270. Which of the following tests is not used to differentiate between cochlear and retrocochlear hearing loss?

a) SISI TEST

b) Evoked response audiometry

c) Threshold tone decay test

d) Recruitment

Correct Answer - C

Ans. is 'c' i.e., Threshold tone decay test [Ref Dhingra 5th/e p. 31; Zr/e p. 28]

271. Where is the auditory cortex located inside the brain?

a) Superior temporal gyrus

b) Inferior temporal gyrus

c) Area 3,1,2

d) Cingulate gyrus

Correct Answer - A
Ans. is 'a' i.e., Superior temporal gyrus *[Ref Pickles, James* 0. *(2012). An Introduction to the Physiology of Hearing (4th ed.). Bingley, UK: Emerald Group Publishing Limited, pp. 215-217.]* Primary Auditory Cortex is located bilaterally, roughly at the upper sides of the temporal lobes - in humans on the superior temporal plane, within the lateral fissure and comprising parts of Heschl's gyrus and the superior temporal gyrus, including planum polare and planum temporale (roughly Brodmann areas 41, 42, and partially 22).

272. When does the rudimentary cochlea develop in the fetus?

a) First week

b) 4th to 8th week

c) 8th to 12th week

d) 16 to 20th week

Correct Answer - B

Ans. is 'b' i.e., 4th to 8th week [Ref Chap 172-Teview of medical embryology-Ben Pasky]

Development of Inner ear

- After implantation, around the second to third week the developing embryo consists of three layers: endoderm, mesoderm andectoderm.
- The first part of the ear to develop is the inner ear,which begins to form from the ectoderm around the 22nd day of the embryo's development. Specifically, the inner ear derives from two thickenings called otic placodes on either side of the head. Each otic placode recedes below the ectoderm, forms an otic pit and then an otic vesicle. This entire mass will eventually become surrounded by mesenchyme to form the bony labyrinth.
- Around the 33'd day of development, the vesicles begin to differentiate. Closer to the back of the embryo, they form what will become the utricle and semicircular canals. Closer to the front of the embryo, the vesicles differentiate into a rudimentary saccule, which will eventually become the saccule and cochlea.
- Part of the saccule will eventually give rise and connect to the cochlear duct. This duct appears approximately during the sixth

week and connects to the saccule through the ductus reuniens.

273. The main muscle affected in congenital muscular torticollis is?

a) Sternocleidomastoid

b) Trapezius

c) Scalenus Anticus

d) Omohyoid

Correct Answer - A

Ans. is 'a' i.e., Sternocleidomastoid

[Ref: Cooperman, Daniel R. (1997). Karmel-Ross, Karen, ed. "The Differential Diagnosis of Torticollis in Children". Physical & Occupational Therapy in Pediatrics. 17 (2): 1-11]

- The cause of congenital muscular torticollis is unclear. Birth trauma or intrauterine malposition is considered to be the cause of damage to the sternocleidomastoid muscle in the neck. Other alterations to the muscle tissue arise from repetitive microtrauma within the womb or a sudden change in the calcium concentration in the body which causes a prolonged period of muscle contraction.

274. Miracle fruit is used to change the taste from?

a) Sour to Bitter

b) Sour to Sweet

c) Bitter to sweet

d) Salty to sweet

Correct Answer - B
Ans. is 'b' i.e., Sour to Sweet *[Ref Peter Hanelt, ed. (2001).Mansfeld's encyclopedia of agricultural and horticultural crops 2. Springer. p. 1660. ISBN 3-540-41017-1.]*
Miracle Fruit contains a glycoprotein called miraculin, which binds to the tongue's taste buds when the fruit is consumed.
Miraculin acts as a sweetness inducer when it comes in contact with acids, causing sour foods to taste sweet, temporarily.

275. All of the following are complications of maxillary sinus lavage and insufflation except?

a) Air embolism

b) Orbital injury

c) Epistaxis

d) Facial nerve injury

Correct Answer - D

Ans. is 'd' i.e., Facial nerve injury ***[Ref Schlemmer KD, Naidoo SK. Complicated sinusitis in a developing country, a retrospective review. Int J Pediatr Otorhinolaryngol. 2013 May 17]***

Complication of Maxillary sinus lavage and insufflation

- Complications of nonendoscopic drainage procedures can be minor or severe.
- The most common complication is failure to enter the sinus because of improper positioning of the trocar, incomplete penetration of the sinus mucosa, or the presence of a hypoplastic antrum.
- Epistaxis may occur because of laceration of the nasal mucosa or preexisting coagulopathies necessitating packing.
- Severe complications include orbital injury, air embolism, and death secondary to injection of air into the sinus.

276. All of the following are removed in vertical hemilaryngectomy except?

a) Half Glottis

b) Half Supraglottis

c) Half tongue

d) Half Subglottis

Correct Answer - C

Ans. is 'c' i.e., Half tongue ***[Ref Dhingra 4th/e p. 284; http://128.255.52.245/oto/Beta/database/contents]***

Vertical hemilaryngectomy means excision of one half of the larynx on one side, i.e., vertical half is removed which include vertical half of supraglottis, glottis and subglottis.

Horizontal hemilaryngectomy is the excision of supraglottis only, also known as supraglottic laryngectomy.

277.

Submucosal resection is the treatment of choice of?

a) DNS in adults

b) DNS in children

c) Sluder's Neuralgia

d) Nasal polyp

Correct Answer - A

Ans. is 'a' i.e., DNS in adults *[Ref Dhingra 5th /e p. 423]*

Submucous resection (SMR) is a surgical procedure to correct the deformity of nasal septum.

The principle of this procedure is to remove deviated cartilage and bone from beneath the mucosal lining of nasal septum, leaving a corrected septum largely composed of scar tissue.

Submucous resection is not advocated in children upto 17 years of age as it may interfere with development of the facial bones.

278. Which perforation of the tympanic membrane is most commonly seen with tubotympanic CSOM?

a) Central

b) Anterosuperior

c) Posterosuperior

d) Posteroinferior

Correct Answer - A

Ans. is 'a' i.e., Central [Ref Dhingra 5th le p. 77; Pediatric otolaryngology 2"/e p. 478] Tubotympanic CSOM

- It is also known as safe ear as it does not cause any serious complications
- Infection is is limited to antero-inferior part of middle ear cleft (eustachain tube & mesotympanum) and is associated with central perforation in pars tensa of tympanic membrane.

279. Caldwell Luc Surgery has its approach to the maxillary antrum through ?

a) Gingivolabial sulcus

b) Inferior orbital rim

c) Nasal septum

d) Cribriform plate

Correct Answer - A

Ans. is 'a' i.e.,Gingivolabial sulcus *[Ref Dhingra 5thIe p. 422]*

280. In Caldwell Luc operation, the approach is through the?

a) Sublabial Approach leading to opening of mandibular antrum

b) Through the sphenopalatine recess

c) Opening of maxillary antrum through gingivolabial approach

d) Superior meatus

Correct Answer - C

Ans. is 'c' i.e., Opening of maxillary antrum through gingivolabial approach ***[Ref Dhingra Stile p. 422]***

Caldwell-Luc operation is a process of opening the maxillary antrum through canine fossa by sublabial approach and dealing with the pathology inside the antrum.In this surgery, antrum is reached through a incision in gingivolabial sulcus (from lateral incisor to 2"d molar) and then opening of antrum in this area.

281. All of the following are indications for tracheostomy except ?

a) Coma after head injury

b) Maxillofacial injury

c) Bilateral abductor palsy

d) Superior laryngeal nerve palsy

Correct Answer - D

Ans. is 'd' i.e., Superior laryngeal nerve palsy ***[Ref Ajay Yadav zi^{th}ie p. 215; Dhingra 5thie p. 337]***

<u>Tracheostomy</u>

- A tracheostomy is a surgical procedure to create an opening through the neck into the anterior wall of trachea.
- A tube is usually placed through this opening to provide an airway and to remove secretions from the lungs. The tube is called *tracheostomy tube.*

282. Most common cause of otitis externa is?

a) Fungal infection

b) Bacterial infection

c) Seborrheic disease

d) Herpes Zoster

Correct Answer - B

Ans. is 'b' i.e., Bacterial infection [Ref Clinical ENT 5th/e p. 223]

- Most common cause of otitis externa is bacterial infection.
- Two most common causative bacteria are staphylococcus aureus and pseudomonas

283. Which is the narrowest portion of the esophagus?

a) At the cricopharyngeal sphincter

b) At the crossing of the left main bronchus

c) At the level of the aortic arch

d) At the diagphragmatic aperture

Correct Answer - A
Ans. is 'a' i.e., At the cricopharyngeal sphincter
[Gray H. Chapter 35: Mediastinum. Standring S, ed. Gray's Anatomy: The Anatomical Basis of Clinical Practice. 40`Ve New York, NY: Churchill Livingstone Elsevier; 2008. 939-57.]
Cricopharyngeal sphincter is the narrowest portion of esophagus

284. Which of the following is not a premalignant condition oral cancer?

a) Leukoplakia

b) Erythroplakia

c) Oral submucous fibrosis

d) Systemic Sclerosis

Correct Answer - D

Ans. is 'd' i.e., Systemic Sclerosis [*Ref Devita 7"Ve p. 982; Bailey & love 25`Ve p. 735]*

<u>Lesions with increased risk of malignancy in oral cancer</u>

- Premalignant condition :- Leukoplakia, Erythroplakia, Speckled erythroplakia, chronic hyperplastic candidiasis.
- Conditions increasing risk :- Oral submucous fibrosis, syphilitic glossitis, sideropenic dysphagia (Peterson Kelly syndrome).
- Risk is doubtful : - Oral lichen planus, DLE, Dyskeratosis congenita.

285. Which of the following is a cause of objective tinnitus?

a) Impacted Wax

b) Carotid artery aneurysm

c) Meniere's disease

d) Ototoxic drugs

Correct Answer - B

Ans. is 'b' i.e., Carotid artery aneurysm [Refi Dhingra Sth/e p. 145; Scott Brown's 7th/e Vol-3 p. 4029-4030;Tuli p. 125-126]

286. Which of the following cancers do not present with cervical lymphnode involvement?

a) Glottic Cancer

b) Subglottic Cancer

c) Papillary thyroid cancer

d) Oral cancer

Correct Answer - A

Ans. is 'a' i.e., Glottic Cancer *[Ref Dhingra 5th Ie p. 327; 4th' p. 283]*

True vocal cords are devoid of lymphatic, hence less chance of cervical nodal metastasis

287. Pulsatile tinnitus is a feature of ?

a) Glomus tumour

b) acoustic neuroma

c) malignant otits externa

d) meneire's disease

Correct Answer - A

Ans. is 'a' i.e., Glomus tumour [Ref Logan Turner 10th/e p. 214]

- The earliest symptoms of glomus tumour is pulsatile tinnitus (earliest) and hearing loss. Hearing loss is conductive and slowly progressive. These are followed by blood stained otorrhoea and earache.

288. Histelberger's sign is seen in?

a) Acoustic neurom

b) Glomus Tumour

c) Nasal angiofibroma

d) Acute suppurative otitis media

Correct Answer - A

Ans. is 'a' i.e., Acoustic neurom [Ref Acta Otorhinolaryngol Belg. 1987;41(1):40-8.The Hitselberger sign as a perception phenomenon. Benz B, Baumgarten D.]

Hitselberger's sign

- In Acoustic neuroma - loss of sensation in the postero-superior part of external auditory meatus supplied by Arnold's nerve (branch of Vagus nerve to ear).

289. All of the following are true about Spasmoidic Dysphonia except ?

a) It may be of adductor or abductor type

b) Abductor type is characterized by Whispering quality of voice

c) Adductor type is characterized by Breathlessness

d) It is focal Laryngeal dystonia

Correct Answer - C

Ans. is 'c' i.e., Adductor type is characterized by Breathlessness

[RefiSulica L (December 2004). "Contemporary management of spasmodic dysphonia". Current Opinion in Otolaryngology & Head and Neck Surgery. 12 (6)]

290. Ethmoidal infundibulum lies between ?

a) Bulla ethmoidalis and uncinate process of ethmoid

b) Middle and inferior turbinate

c) Hiatus semilunaris and Inferior meatus

d) Wing of sphenoid and maxillary antrum

Correct Answer - A

Ans. is 'a' i.e., Bulla ethmoidalis and uncinate process of ethmoid

- The hiatus semilunaris is bounded inferiorly by the sharp concave margin of the uncinate process of the ethmoid bone, and leads into a curved channel, the infundibulum, bounded above by the bulla ethmoidalis and below by the lateral surface of the uncinate process of the ethmoid.

291. What lies between the middle and inferior turbinate?

a) Middle meatus

b) Superior meatus

c) Hiatus semmilunaris

d) Inferior meatus

Correct Answer - A

Ans. is 'a' i.e., Middle meatus [Ref Scott Brown 7'Ve vol 2 p. 1329]

- Superior meatus → * Below superior turbinate (between superior and middle turbinates)
- Middle meatus → Below middle turbinate (between middle and inferior turbinates)
- Inferior meatus → Below inferior turbinate.

292. All of the following are extrinsic laryngeal membranes except?

a) Quadrangular membrane

b) Hyoepiglottic ligament

c) Cricotracheal membrane

d) Thyrohyoid membrane

Correct Answer - A

Ans. is 'a' i.e., Quadrangular membrane

[Ref Merati AL, Bielamowicz SA. Textbook of Laryngology. San Diego: Plural Publishing Inc 2006.]

Quadrangular membrane

1. Aryepiglottic ligament (superior border of membrane)
2. Vestibular ligament (Inferior border of membrane

293.

The narrowest part of the nasal cavity is ?

a) Internal nasal valve

b) Antrochoanal region

c) 1st nasal turbinate

d) Region of inferior concha

Correct Answer - A

Ans. is 'a' i.e., Internal nasal valve [Ref Jafek BW. Anatomy and physiology of the nose. Jafek BW, Stark AK, eds. ENT Secrets. Philadelphia, Pa: Hanley & Belfus; 1996. 77-83.]

- The internal nasal valve involves the area bounded by upper lateral cartilage, septum, nasal floor, and anterior head of the inferior turbinate. This makes up the narrowest portion of the nasal airway

294. Anterior tonsillar pillar is formed by?

a) Palatopharyngeal fold

b) Palatoglossal fold

c) Pterygopalatine arch

d) Valleculae

Correct Answer - B
Ans. is 'b' i.e., Palatoglossal fold
Anterior tonsillar pillar- Palatoglossal fold
Posterior tonsillar pillar- Palatopharyngeal fold

295. One of the following is true regarding Zenker diverticulum ?

a) It is a pulsion diverticulum

b) It projects anteriorly

c) Commonly seen in young males

d) It is between superior and middle constrictor

Correct Answer - A

Ans. is 'A' i.e., It is a pulsion diverticulum

Hypopharyngeal diverticulum or Zenker's diverticulum or pharyngeal pouch

It is a pulsion diverticulum where pharyngeal mucosa herniates through the Killian's dehiscence, a weak area between two parts of the inferior constrictor.

It is the most common esophageal diverticulum.

The diverticula arise posteriorly in the midline of neck. The mouth of the diverticula is in the midline but projects laterally (usually left laterally)

Zenker's diverticula are rarely seen below 30 yrs of age, most patients are over 50.

296.

Narrowest part of the nasal cavity is ?

a) Vestibule

b) Choanae

c) Inferior turbinate

d) Middle turbinate

Correct Answer - C

Ans. is 'c' i.e., Inferior turbinate [Ref Heidari Z, Mahmoudzadeh-Sagheb H, Khammar T, Khammar M (May 2009). "Anthropometric measurements of the external nose in 18-25-year-old Sistani and Baluch aborigine women in the southeast of Iran". Folia Morphol. (Warsz) 68 (2): 88-92]

- The internal nasal valve comprises the area bounded by the upper lateral-cartilage, the septum, the nasal floor, and the anterior head of the inferior turbinate. In the narrow (leptorrhine) nose, this is the narrowest portion of the nasal airway.

297. Saddle nose deformity is seen in?

a) Primary Syphilis

b) Secondary syphilis

c) Tertiary syphilis

d) Lupus Vulgaris

Correct Answer - C

Ans. is 'c' i.e., Tertiary syphilis [Ref Dhingra 5th/e p. 184]

Syphilis of nose occurs as :-

1. Primary :- Rare and manifests as primary chancre of the vestibule.
2. Secondary :- Rarely recognized and manifests as simple rhinitis, crusting and fissuring.
3. Tertiary :- This is the stage in which nose is involved most commonly. There is formation of gumma followed by bony perforation of nasal septum. Bridge of the nose collapses causing a saddle deformity. Atrophic rhinitis may occur as a complication.

298. All of the following are true about vasomotor rhinitis except ?

a) It is allergic

b) It is due to parasympathetic overactivity

c) Resistant cases may need cryotherapy

d) It may lead to hypertrophic rhinitis

Correct Answer - A

Ans. is 'a' It is allergic [Ref Scott's Brown 7thie p. 2122]

Vasomotor rhinitis

- Vasomotor rhinitis is a nonallergic condition that involves a constant runny nose, sneezing and nasal congestion, i.e., the nose is stuffy or runny for reasons other than allergies and infections. The exact etiology is unknown, but triggers include emotions, odors, poor air quality, spicy foods, and medication side effects.

299. All of the following are true about vasomotor rhinitis except?

a) It is a nonallergic condition

b) it is due to parasympathetic overactivity

c) It may cause paroxysmal episodes of sneezing

d) It is an infective condition

Correct Answer - D

Ans. is 'd' i.e., It is an infective condition [Ref Dhingra 5th/e p. 170]

300. In evaluation of a case of immotile nasal cilia, which of the following investigations should prove useful?

a) Rhinogram

b) Xray nasal and paranasal sinuses

c) Sweat sodium levels

d) Nitric oxide test

Correct Answer - D

Ans. is 'd' i.e., Nitric oxide test [Ref Leigh MW, Pittman JE, Carson JL, Ferkol TW, Dell SD, Davis SD. Clinical and genetic aspects of primary ciliary dyskinesia/Kartagener syndrome. Genet Med. 2009 Jul. 11(7):473-87]

Screening tests for immotile cilia syndrome

- Nitric oxide : Measuring exhaled nasal nitric oxide, which is mostly reduced in primary ciliary dyskinesia, is a good screening test for immotile-cilia syndrome with a good negative predictive value. Studies have demonstrated a relationship between nasal nitric oxide levels, nasal oxide synthase mRNA expression, and ciliary beat frequency. There is also a significant inverse correlation between the degree of aplasia and/or hypoplasia of the paranasal sinus and nasal nitric oxide values in primary ciliary dyskinesia patients.

301. All of the following are features of ethmoidal polyp except ?

a) Common in adults

b) Commonly Singular

c) Commonly bilateral

d) Is usually allergic

Correct Answer - B

Ans. is `b' i.e., Commonly Singular [Ref Dhingra 5thIe p. 187; Tuli 1"/e p. 173]

- Antrochoanal polyp grows backward (posteriorly), therefore, it may not be visible on anterior rhinoscopy, while posterior rhinoscopy shows smooth, greyish white, spherical mass in choana.
- On the other hand, ethmoidal polyps grow anteriorly. Therefore, they are best seen on anterior rhinoscopy and may not be seen on posterior rhinoscopy.

302. All of the following are features of enlarged adenoids except?

a) Otitis media

b) Nasal obstruction

c) Failure to thrive of child

d) Esophagitis

Correct Answer - D

Ans. is 'd' i.e., Esophagitis *[Ref Dhingra Vie p. 254]*

Clinical features of enlarged adenoids

Enlarged and infected adenoids may cause nasal, aural (ear), and general symptoms.

1) Nasal symptoms

- Nasal obstruction is the commonest symptom. This result in mouth breathing. As the respiration and feeding cannot take place simultaneously, child fails to thrive.
- Other symptoms are nasal discharge (wet bubbly nose), sinusitis, epistaxis and toneless voice with loss of nasal quality (Rhinololia clausa).

2) Aural symptoms

- Tubal obstruction
- Otitis media :- Recurrent acute otitis media, CSOM, serous otitis media

3) General symptoms

- Adenoidfacies: Elong at edface with dullex pression,open mouth,prominent & crow dedup per teeth, hit chedup perlip, pinched in appearance of nose and high arched palate. Pulmonary hypertension, aprosexia (lack of concentration).

303. All of the following are treatments of multiple bilateral ethmoidal polyps except?

a) Functional endoscopic sinus surgery

b) Intranasal ethmoidectomy

c) Extranasal ethmoidectomy

d) Caldwll Luc Surgery

Correct Answer - D

Ans. is 'd' i.e., Caldwil Luc Surgery [Ref Scott Brown, Vol-IL p.1701; Dhingra 5`"/e p. 188, 430]

Surgical treatment of ethmoidal polyps :

1. Functional endoscopic sinus surgery (FESS) : Surgery of choice when available.
2. Polypectomy : When there are one or two pedunculated polyps.
3. Intranasal ethmoidectomy : Indicated when polyps are multiple and sessile.
4. Extranasal ethmoidectomy : This is indicated when polyps recur after intranasal procedures.
5. Transantral ethmoidectomy : Indicated when infection and polypoidal changes are also seen in the maxillary antrum. In this case antrum is opened by caldwell-Luc approach and the ethmoidal air cells approached through the medial wall of the antrum.

304. What is the treatment of choice for ethmoidal polyps?

a) Functional Endoscopic sinus surgery with polypectomy

b) Intranasal ethmoidectomy

c) Extranasl ethmoidectomy

d) Transantral ethmoidectomy

Correct Answer - A

Ans. is 'a' i.e.,Functional Endoscopic sinus surgery with polypectomy [Ref See above explanation]

305. What is the type of epithelium of the adenoid?

a) Pseudostratified ciliated columnar epithelium

b) Non keratinized squamous epithelium

c) Cuboidal epithelium

d) Columnar epithelium with goblet cells

Correct Answer - A

Ans. is 'a' i.e., Pseudostratified ciliated columnar epithelium

[Ref Wiatrak BJ, Woolley AL. Pharyngitis and adenotonsillar disease. Cummings CW, Fredrickson JM , Harker LA, Crause CJ, Schuller DE, Richardson MA. Otolaryngology Head and Neck Surgery. ..V/e. London: Mosby; 1998. 188-215.]

The adenoid is covered by a pseudostratified ciliated columnar epithelium that is plicated to form numerous surface folds The nasopharyngeal epithelium lines a series of mucosal folds, around which the lymphoid parenchyma is organized into follicles and is subdivided into 4 lobes by connective tissue septa Seromucous glands lie within the connective tissue, and their ducts extend through the parenchyma and reach the nasopharyngeal surface.

306. The artery which leads to bleeding in Woodruff's area is?

a) Anterior ethmoidal artery

b) Sphenopalatine artery

c) Greater palatine artery

d) Superior labial artery

Correct Answer - B

Ans. is 'b' i.e., Sphenopalatine artery [Ref Scott Brown 7^{h}/e Vol-2p. 1597; Dhingra 5th/e p. 190]

Woodruff's area : ?

- It is situated under the posterior end of inferior turbinate. Sphenopalatine artery anastomoses with posterior pharyngeal artery here. Posterior epistaxis occurs in this area.

307. Intrathecal fluorescein with endoscopic visualization is useful in diagnosis of?

a) Deviated nasal septum

b) Multiple ethmoidal polyps

c) Rhinitis Medicamentosa

d) CSF Rhinorrhoea

Correct Answer - D

Ans. is 'd' i.e., CSF Rhinorrhoea [Ref: Logan Turner 10(h/e p. 28, Dhingra 5th/e p. 179]

Detection of site of CSF leak in CSF Rhinorrhoea

1. HRCT : - HRCT with or without godolinium is the most helpful study for identifying the site of leak, i.e., investigation of choice.
2. MRI : - MRI with heavy T2 weighted image may highlight CSF sufficiently to show the leak.
3. CT cisternography : - CT scan after injection of contrast dye is effective in patients with an active leak.
4. Radioisotope cisternography : - Radioisotope injected intrathecally and measured.
5. Fluorescin dye : - Intrathecal fluorescin with endoscopic visualization.

308. All of the following are features of a nasal foreign body except?

a) Foul smelling discharge

b) Epistaxis

c) Nasal obstruction

d) Septal perforation

Correct Answer - D

Ans. is 'd' i.e., Septal perforation [Ref Dhingra S^a^Ve p. 176; Logan Turner 10'^h^/e p. 63]

Foreign body in nose

- A nasal foreign body is anything that gets stuck inside the nose. Inanimate foreign body (object) is more common than animate foreign body. Common objects found in noses include food material (peas, beans, nuts), tissue paper, beads, toys and rocks. Animate foreign bodies are worms, larvae or maggots. Most cases of foreign bodies in the nose and nasal cavity are not serious and occur in toddlers and children from 1-8 years. Because children develop the ability to pick up objects at about the age of 9 months, this problem is much less common before 9 months of age.

309. ETHMOIDAL BULLAE are seen in?

a) Posterior ethmoidal air cells

b) Middle ethmoid air cells

c) Superior ethmoidal air cells

d) Inferior ethmoidal air cells

Correct Answer - B

Ans. is 'b' i.e., Middle ethmoid air cells ***[Ref: Logan Turner 10th le p. 379; Dhingra 5th/e p. 153, 154]***

310. All of the following are features of a nasal foreign body except?

a) Vestibulitis

b) Epistaxis

c) Nasal obstruction

d) Deviated septum

Correct Answer - D

Ans. is 'd' i.e., Deviated septum [Ref Dhingra 5thie p. 176; Logan Turner 10`"/e p. 63]

311.

All of the following are causes of perforation of cartilaginous part of nasal septum except?

a) Tuberculosis

b) Leprosy

c) Lupus

d) Syphilis

Correct Answer - D

Ans. is 'd' i.e., Syphilis [Ref Dhingra 5th/e p. 166; Scott-Brown's Otolaryngology 7th/e Vol-2 chapter-124 p. 1583]

- A nasal septal perforation is a through-and-through defect in any portion of the cartilaginous or bony septum with no overlying mucoperichondrium or mucoperiosteum on either side.
- Perforation of bony part :- Syphilis
- Perforation of cartilaginous part :- TB, leprosy, lupus.

312. All of the following are true about nasal myiasis except?

a) Common in vasomotor rhinitis

b) Intense nasal irritation present

c) Meningitis may occur in severe disease

d) Chloroform water is one of the modes of treatment

Correct Answer - A

Ans. is 'a' i.e., Common in vasomotor rhinitis ***[Ref Dhingra 5th/e p. 178]***

313. Water's view is used to obtain diagnostic information of:

a) Maxillary sinus

b) Ethmoidal sinuses

c) Frontal sinus

d) Sphenoid sinus

Correct Answer - A

ANSWER: A. Maxillary sinus

Waters' view (also known as the **Occipitomental view**) is a radiographic view, where an X-ray beam is angled at 45° to the orbitomeatal line.

The rays pass from behind the head and are perpendicular to the radiographic plate.

It is commonly used to get a better view of the **maxillary sinuses**.

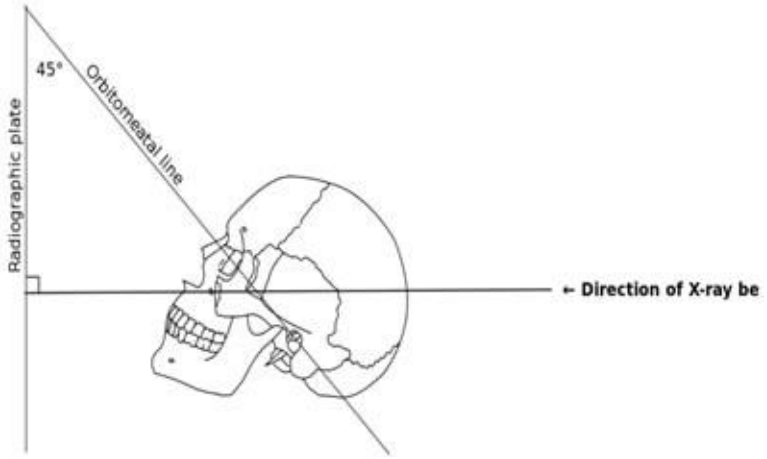

Water's radiographic view of skull

314. Tracheostomy indication is:

a) Vocal cord replacement

b) Pharynx replacement

c) Tracheomalacia

d) Foreign body obstructing airway

Correct Answer - D
Answer- D. Foreign body obstructing airway
Indications of tracheostomy:

- Upper respiratory tract obstruction; Laryngeal, supralaryngeal ,and tracheal causes.(Causes of stridor)
- Lower respiratory tract obstruction: (Secretory obstruction, Wet lung syndrome).

315. Caldwell's view is used for:

a) Maxillary sinus

b) Frontal sinus

c) Ethmoidal sinus

d) All of the above

Correct Answer - B
Answer- B. **Frontal sinus**
Caldwell's view (or **Occipitofrontal view**) is a radiographic view of skull, where X-ray plate is angled at 20° to orbitomeatal line.
The rays pass from behind the head and are perpendicular to radiographic plate.
It is commonly used to get better view of frontal sinuses.

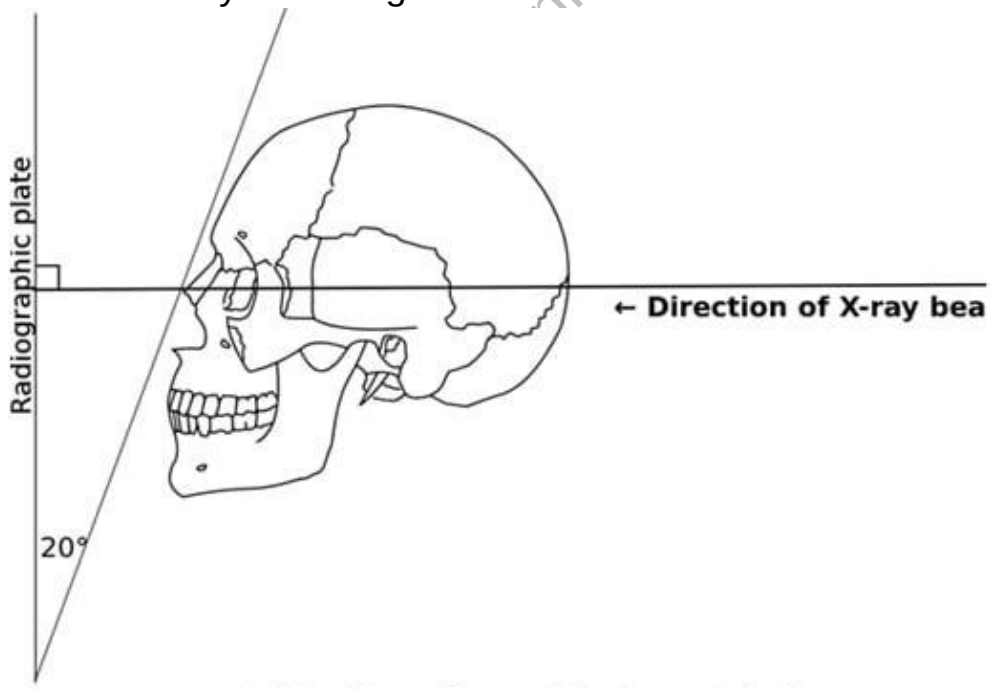

Caldwell's radiographic view of skull

316. Where will be the placement location for Auditory Brainstem Implant?

a) Scala tympani

b) Recess of 4th ventricle

c) IAC

d) back of ear

Correct Answer - B

Answer: B - Recess of 4th ventricle.

The implant is usually placed in the lateral recess of the fourth ventricle at the time of tumor resection to stimulate the cochlear nucleus

Auditory Brainstem Implant (ABI):

- Tumor resection surgery in NF patients result in cochlear nerve damage or loss of function of nerve resulting in deafness.
- ABI are useful in restoring auditory perception to deaf patients with neurofibromatosis type 2 (NF2)
- Also used in treatment of congenitally deaf children with cochlear malformations or cochlear nerve deficiencies.
- Placement location: **Lateral recess of 4th ventricle**

317. All of the following are features of Tubotympanic CSOM except ?

a) Profuse discharge

b) Hearing loss

c) Extreme pain

d) Sometimes paradoxical improvement in hearing is seen

Correct Answer - C

Ans. is 'c' i.e., Extreme pain [Ref Dhingra 5th/e p. 77; Pediatric otolaryngology 2"/e p. 478]

Clinical features of tubotympanic CSOM

- Profuse mucopurulent discharge which is not foul smelling, i.e., non-foul smelling discharge
- Hearing loss (conductive type). If sensorineural component also occurs (i.e., mixed type), it arouses the suspicion of toxic deafness.
- Sometimes, patient reports a paradoxical effect, i.e., hears better in the presence of discharge than when the ear isdry. This is due to round window shielding effect produced by discharge which helps to maintain phase differential.
- There is no pain, if it occurs it is due to associated otitis externa not due to otitis media.
- Since the infected area is open at both ends, discharge does not accumulate in the middle ear cavity
- Ossicular chain is mostly uninvolved, if involved only long process of incus is involved.

318. Features of Usher's Syndrome include all except ?

a) Night Blindness

b) Visual Impairment

c) Multiple Neurofibromas

d) Hearing deficit

Correct Answer - C

Ans. is 'c' i.e., Multiple Neurofibromas [Ref Mets MB, Young NM, Pass A, Lasky JB (2000). "Early diagnosis of Usher syndrome in children". Transactions of the American Ophthalmological Society. 98: 237-45.]

Usher syndrome

- Usher syndrome is a relatively rare genetic disorder caused by a mutation in any one of at least 11 genes resulting in a combination of hearing loss and visual impairment, and is a leading cause of deafblindness. Usher syndrome is incurable at present.
- Other names for Usher syndrome include Hallgren syndrome, Usher-Hallgren syndrome, retinitis pigmentosa dysacusis syndrome, and dystrophia retinae dysacusis syndrome.
- This syndrome is characterized by hearing loss and a gradual visual impairment. The hearing loss is caused by a defective inner ear, whereas the vision loss results from retinitis pigmentosa (RP), a degeneration of the retinal cells.Usually, the rod cells of the retina are affected first, leading to early night blindness and the gradual loss of peripheral vision. In other cases, early degeneration of the cone cells in the macula occurs, leading to a loss of central acuity. In some cases, the foveal vision is spared, leading to "doughnut vision"; central and peripheral vision are intact, but an annulus exists

around the central region in which vision is impaired.

319. 65 year old person with hearing loss with normal speech discrimination is suffering from?

a) Noise induced hearing loss

b) Presbycusis

c) Ototoxic drug

d) NOHL

Correct Answer - B

Ans. is 'B' i.e., Presbycusis

Information in this question are :- (i) Old age (65 years), (ii) Hearing loss, and (iii) Preserved speech discrimnation.

Diagnosis is Presbycusis.

Presbycusis

- Presbycusis refers to sensorineural hearing loss in elderly individuals
- Characteristically, presbycusis involves bilateral high frequency hearing loss associated with difficulty in speech discrimination and central auditory processing information.

Four pathological types of presbycusis have been identified :-

- Sensory presbycusis There is epithelial atrophy with loss of sensory hair cells and supporting cells in the organ of corti. This process starts in the basal turn of cochlea and slowly progress towards the apex. Higher frequencies are affected but speech discrimination is preserved.
- Neural presbycusis :- There is atrophy of nerve cells in the cochlea and central neural pathways. Atrophy occurs throughout the cochlea, with the basilar region only slightly more predisposed than

the remainder of the cochlea. Therefore, no precipitous drop in threshold on audiometry is observed. Speech discrimination is poor.

- Metabolic (strial) presbycusis ;;- There is atrophy of stria vascularis. Atrophy results in hearing loss represented by flat audiogram, but speech discrimination is preserved.
- Mechanical (cochlear conductive) presbycusis :- There is thickening and secondary stiffening of the basilar membrane of the cochlea. The thickening is more severe in the basal turn of cochlea where the basilar membrane is narrow. This correlates with a gradually sloping high frequency sensorineural hearing loss. Speech discrimination is average.

320. Stimulation of the external auditory canal leads to cough due to which nerve

a) Auricular branch Vagus

b) Greater auricular nerve

c) Auriculotemporal nerve

d) Facial Nerve

Correct Answer - A
Ans: A. Auricular branch Vagus nerve.
>Auricular branch of Vagus (Arnold's nerve) and Facial nerve continues inwards to supply the posterior wall and floor of the EAC.
> The cough response caused while stimulating the ear canal is mediated by the vagus which also supplies the larynx.
(Re/. Shambaugh, 6th ed., page 45)

321.

widening of the cartilaginous part of the extra auditory canal called.

a) Otoplasty

b) Myringoplasty

c) Tympanoplasty

d) Meatoplasty

Correct Answer - D
Ans. (d) Meatoplasty.
Meatoplasty is an operative technique to widen the lateral cartilaginous part of the external auditory canal.
Otoplasty- is a procedure to change the shape, position or size of the ears.
Myringoplasty-closure of the perforation of pars tensa of the tympanic membrane
Tympanoplasty- surgical technique to repair a defect in the tympanic membrane with the placement of a graft, either medial or lateral to the tympanic membrane annulus
ref:**https://vula.uct.ac.za/access/content/group/ba5fb1bd-be95-48e5-81be-586fbaeba29d/Meatoplasty.pdf**

322. Tubercular Otitis media is characterized by all except

a) Painful otorrhea

b) Multiple perforations

c) Pale granulations

d) Foul-smelling ear discharge

Correct Answer - A
Ans. A. Painful otorrhea.
>Tuberculosis of middle ear is a comparatively rare entity usually seen in association with or secondary to pulmonary tuberculosis, the infection reaches the middle ear through the eustachian tube
>It is characterized by painless otorrhoea which fails to respond to the usual antimicrobial treatment
>patient with evidence of tubercle infection elsewhere followed by multiple tympanic membrane perforations, abundant granulation tissue, and bone necrosis, preauricular lymph node enlargement
https://www.ncbi.nlm.nih.gov/pubmed/21522113

323. Partial and full closure done in

a) Atrophic rhinitis

b) Allergic rhinitis

c) Vasomotor rhinitis

d) Occupational rhinitis

Correct Answer - A
Ans. A. Atrophic rhinitis
ATROPHIC RHINITIS
>It is a form of chronic rhinitis associated with atrophy of nasal mucosa, mucous glands, nerves, and vessels.
>It can be primary or secondary.
>The surgical options aim to reduce the size of the roomy cavities to prevent the exposure to drying effects of air and crusts formation and thus help regeneration of nasal mucosa.
Full closure - Young's operation
Partial closure - Modified young's operation.
(Ref. Cummings,6th ed., 695)

324. Occipitomental view of PNS X-ray called as

a) Caldwell view

b) Water view

c) Town view

d) Pine view

Correct Answer - B
Answer:b. Water view
Occipitomental view of PNS X-ray called as Water view