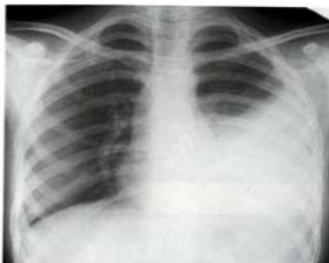



**MBBS FINAL PROFESSIONAL  
MODEL QUESTIONS FOR ANNUAL 2009  
Medicine  
(Multiple Choice Questions)**

- Q.1** 22 year old patient with 6 months history of fever, joint pain, photosensitivity skin rash and shortness of breath. Complete urine examination shows; proteins ++, blood ++.

Chest X-Ray is shown below:

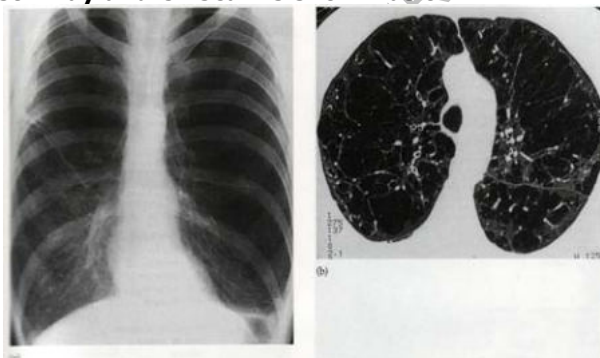


**What is the most likely diagnosis?**

- a) Tuberculosis
- b) SLE
- c) Rheumatoid arthritis
- d) Parapneumonic effusion
- e) CCF

- Q.2** 65 years old chronic smoker presents with acute shortness of breath in medical emergency.

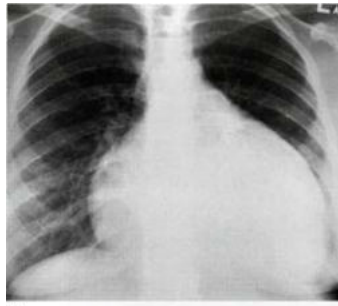
His chest x-ray and CT scan is shown below:



**What is the most likely diagnosis?**

- a) Pneumothorax
- b) Emphysema
- c) Bronchial asthma
- d) Pulmonary embolism
- e) Pulmonary edema

- Q.3** 45 year old gentleman presents in emergency department with fever, pleuritic chest pain shortness of breath on exertion. He has history of acute myocardial infarction 4 weeks back. Chest X-ray reveals cardiac shadow enlargement:

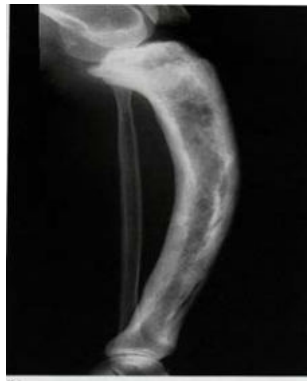

**What is the most likely diagnosis?**

- a) Valvular heart disease
- b) Dilated cardiomyopathy
- c) Dressler's syndrome
- d) Pulmonary edema
- e) Pulmonary embolism

- Q.4** 70 years old lady presents with pain in the leg with shortness of breath and deafness. On examination her leg is warm and bowed.

Chest X-ray – mild cardiomegaly,  
CBC – normal, LFT's – shows increased alkaline phosphatase with normal transaminases X-ray of leg is shown below:



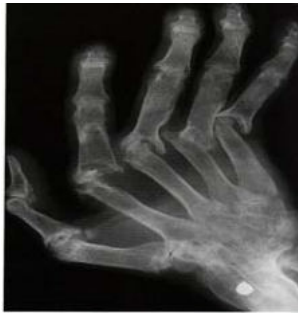**What is the most likely diagnosis?**

- a) Rickets
- b) Paget's disease of the bone
- c) Syphilitic bone disease
- d) Primary bone tumor
- e) Osteoporosis

Q.5

27 year old lady long standing history of fever, anorexia and shortness of breath for 6 months. Spirometry shows restrictive defect on pulmonary function testing.

Hand X-ray is shown below:



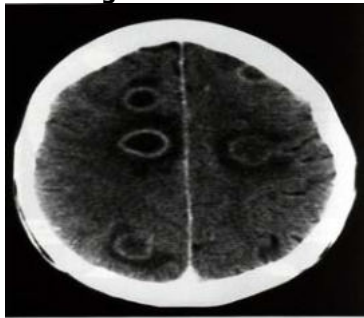
**What is the most likely diagnosis?**

- a) Gouty arthritis
- b) Psoriatic arthritis
- c) SLE
- d) Rheumatoid arthritis
- e) Reactive arthritis

Q.6

25 year old homosexual male known HIV patient presents with fever, headache, vomiting. On examination signs of meningeal irritation positive. Fundoscopy shows papilledema.

CSF examination reported – protein 2.5g/dl (20 – 45mg/dl), glucose 42mg/dl (serum glucose 200mg/dl), WBC 1200mm<sup>3</sup> with predominant lymphocytosis. CT Brain with contrast shows – multiple ring enhancing lesions.



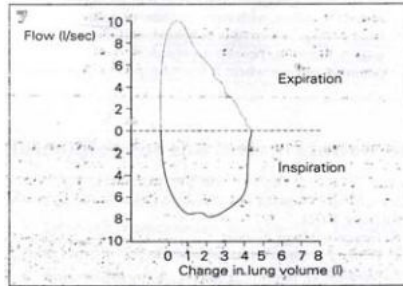
**What is the most likely diagnosis?**

- a) Cerebral toxoplasmosis
- b) Tuberculoma
- c) Metastatic brain disease
- d) Cerebral abscess
- e) Progressive multi focal leukoencephalopathy

Q.7

22 year old girl seen in emergency department with history of intermittent shortness of breath and palpitation. During episodes she feels numbness and paraesthesia in her limbs.

Respiratory Flow Loop Curve is shown below:



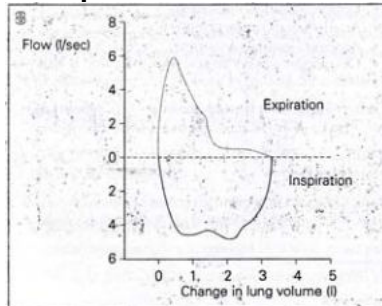
The above loop curve is consistent with which one the following illness?

- a) Bronchial asthma
- b) Pulmonary fibrosis
- c) Pulmonary edema
- d) Hyperventilation syndrome
- e) Pulmonary embolism

Q.8

18 year old boy with history of allergic rhinitis and episodic shortness of breath with wheeze.

Respiratory Flow Loop Curve is shown below:

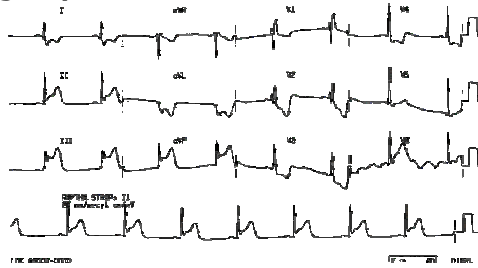


What is the interpretation of the curve?

- a) Obstructive pattern
- b) Restrictive pattern
- c) Normal pattern
- d) Extra thoracic obstructive pattern
- e) Intra thoracic obstructive pattern

**Q.9** 45 year old male smoker seen in emergency with 1 hour history of central chest pain with profuse sweating.

The ECG done in emergency is shown below:

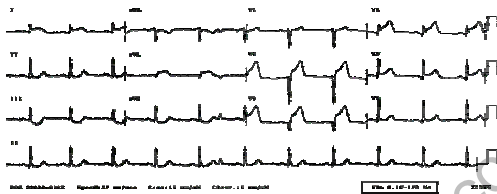


**What immediate step you will take in emergency?**

- a) I/V Heparin
- b) I/V Morphine
- c) Oxygen
- d) I/V Nitrates
- e) I/V Beta Blockers

**Q.10** 47 year old male smoker, diabetic presented in emergency department with shortness of breath and retrosternal chest pain.

The ECG is shown below:

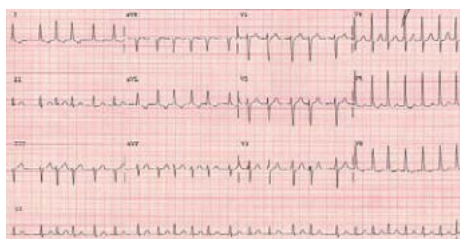


**What is the ECG diagnosis?**

- a) Acute posterior wall MI
- b) Acute anterior wall MI
- c) Acute inferior wall MI
- d) Acute lateral wall MI
- e) Acute sub-endocardial MI

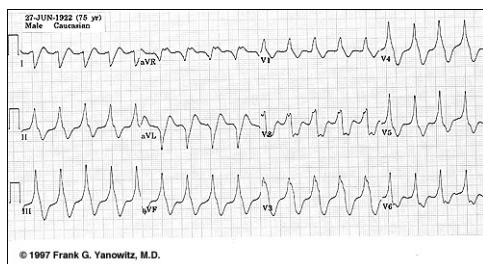Q.11 30 year old female seen in outpatient department with 6 months history of palpitation, weight loss and heat intolerance.

The ECG is shown below:



**What is the ECG diagnosis?**

- a) Atrial fibrillation
- b) Sinus arrhythmia
- c) Atrial flutter
- d) Multiple atrial ectopics
- e) Ventricular tachycardia



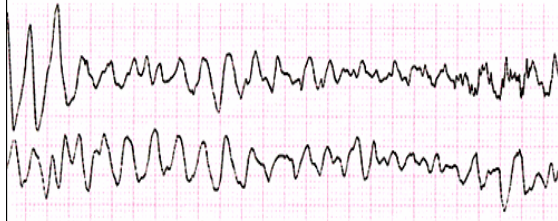
Q.12 The above ECG is of 20 year old girl who gives intermittent history of palpitation. The ECG reported to be Broad complex Tachycardia, either SVT with aberrant conduction or VT.

**Which one of the following drugs response will decide between the two arrhythmias?**

- a) I/V lignocain
- b) I/V Verapamil
- c) I/V Amiodarone
- d) I/V Adenosin
- e) I/V Beta Blocker

Q.13 60 year old male brought in emergency in a state of shock. He is haemodynamically unstable. According to his wife he has two episodes of myocardial infarction in the past 2 years.

ECG has taken immediately in emergency is shown below:



**What immediate step you will take?**

- a) I/V adrenalin
- b) I/V atropine
- c) DC cardio version
- d) I/V amiodarone
- e) I/V lignocain

- Q.14** 10 year old child seen in medical OPD with history of shortness of breath on exertion and palpitation. cardiac auscultation reveals wide fixed splitting of second heart sound:

The following is the cardiac catheterization of the patient:

Chamber	Pressure (mmHg)	Oxygen Saturation (%)
Superior vena cava	—	69
Inferior vena cava	—	65
Right atrium	10	81
Right ventricle	35/0	80
Pulmonary artery	35/12	80
Left atrium	12	96
Left ventricle	105/0	95
Femoral artery	105/55	95

**What is the diagnosis?**

- a) ASD
- b) VSD
- c) PDA
- d) Mitral stenosis
- e) Aortic regurgitation

- Q.15** 07 year old child seen in medical OPD with incidental finding of pansystolic murmur heard at left lower sternal edge. Cardiac catheterization data is shown:

Chamber	Pressure (mmHg)	Oxygen Saturation (%)
Superior vena cava	—	67
Inferior vena cava	—	69
Right atrium	3.5	68
Right ventricle	35/0	79
Pulmonary artery	35/10	80
Left ventricle	100/0	96

**What was the diagnosis?**

- a) ASD
- b) VSD
- c) Tricuspid regurgitation
- d) Mitral regurgitation
- e) PDA

**Q.16** 65 year old lady presents with syncope and angina. On clinical examination her pulse was low volume with BP of 120/100.

The following figures were obtained at cardiac catheterization:

Chamber	Pressure (mmHg)
Right atrium	3.5
Right ventricle	35/9
Pulmonary artery	35/20
Pulmonary artery wedge	18
Left ventricle	210/9
Left ventricular end diastolic	22
Ascending aorta	142/70

**What was the diagnosis?**

- a) Pulmonary stenosis
- b) Aortic stenosis
- c) Coarctation of aorta
- d) Tricuspid stenosis
- e) Mitral regurgitation

[www.FirstRanker.com](http://www.FirstRanker.com)



[www.FirstRanker.com](http://www.FirstRanker.com)