

[MBBS 0224]

FEBRUARY 2024

Sub. Code :6072

M.B.B.S. DEGREE EXAMINATION

(For the candidates admitted from the Academic Year 2019-2020)

THIRD PROFESSIONAL PART – I (CBME)

PAPER I – OTO-RHINO-LARYNGOLOGY

Q.P. Code: 526072

Time: 30 Minutes

Maximum : 20 Marks

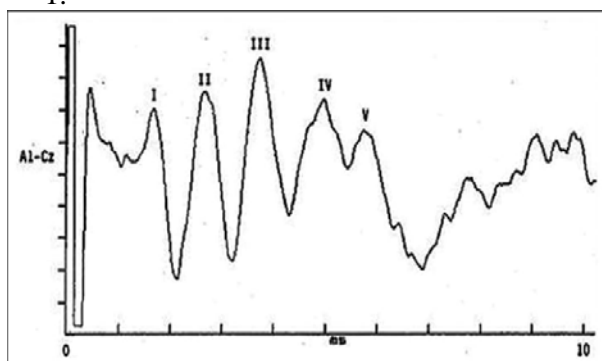
Answer All Questions

Choose one correct answer in the box provided in the Answer Script.
No overwriting should be done. Choice should be given in Capital Letters.

III. Multiple Choice Questions:

(20 x 1 = 20)

1.



In the above graph, which is the Prominent and Consistent waveform?

- A) Wave I B) Wave II C) Wave V D) Wave III
2. The following are parts of Temporal Bone except,
A) Tympanomastoid B) Temporal C) Squamosal D) Zygomatic
3. New Born Screening protocol as per NPPCD is
A) 0, 1, 2 month B) 0, 3, 6 month C) 1, 2, 3 month D) 3, 6, 9 month
4. When there is an Unilateral Sensorineural hearing loss in an elderly adult with negative Recruitment we have to rule out which of the following condition
A) Meniere's disease B) Cochlear Otosclerosis
C) Vestibular Schwannoma D) Malignancy of EAC
5. The Common organism in Otomycosis are
A) Mucor B) Aspergillus C) Candida D) Actinomyces
6. The artery of Epistaxis is
A) Anterior Ethmoidal artery B) Sphenopalatine artery
C) Posterior Ethmoidal artery D) Ophthalmic artery
7. Blue Mantle is a sign of
A) Meniere's disease B) Otosclerosis C) Secretory Otitis Media D) Barotrauma
8. Epistaxis in child is usually due to
A) Vestibulitis B) Hypertension C) Tumours D) Road Traffic Accident

... 2 ...

9. Autonomy in medical Ethics means
A) The doctor has the right to decide which is best for his patient
B) The attender have the right to decide which is best for the patient
C) The patient has the right to decide which is right for the patient
D) The Institute's Medical Board decides what is right for the patient
10. Tapir Nose is a result of
A) Hansen's disease B) Syphilis C) Lupus Vulgaris D) Wegener's granulomatosis
11. For a dorsal hump, which type of Rhinoplasty is performed
A) Augmentation B) Tip-plasty C) Reduction D) External
12. A New Born infant has inspiratory stridor, difficulty in feeding and relieved on prone position, the probable diagnosis is
A) Croup B) Epiglottitis C) Laryngomalacia D) Airway Foreign body
13. Nodes of Rouviere
A) Retropharyngeal node B) Parapharyngeal node C) Adenoids D) Prelaryngeal node
14. Passavant's ridge is formed by
A) Cricopharyngeus and superior constrictor B) Palatopharyngeus and superior constrictor
C) Palatoglossus and superior constrictor D) Thyropharyngeus and superior constrictor
15. Gerlach Tonsil
A) Tubal tonsil B) Palatine tonsil C) Pharyngeal tonsil D) Lingual tonsil
16. A 5-year old child after adenoidectomy developed hypernasality and nasal regurgitation of food. What could be the cause?
A) Velopharyngeal insufficiency B) Glossopharyngeal nerve injury
C) Reactionary hemorrhage D) Trauma to soft palate
17. A 49-year old diabetic patient presents with black necrotic mass filling the nasal cavity and diplopia of the affected side, Management should be
A) Endoscopic Dacryo cysto rhinostomy B) Parenteral Steroids
C) IV. Amphotericin B with endoscopic debridement D) Parenteral Antibiotics
18. Tripod Fracture is seen in
A) Mandible B) Maxilla C) Nasal Bone D) Zygoma
19. Frey's syndrome includes
A) Crocodile tears B) Anosmia C) Gustatory sweating D) None of the above
20. Hearing loss is not caused by
A) Kanamycin B) Vancomycin C) Metronidazole D) Quinine

[MBBS 0224]